

Can Helical Tomotherapy be used as a Safe Treatment Alternative for Breast Cancer Patients?

Julian Jacob, Francois Campana, Ciprian Chira, Dominique Peurien, Caroline Daveau, Nathalie Fournier-Bidoz, Alain Fourquet and Youlia M Kirova*

Department of Radiation Oncology, Institut Curie, Paris, France

Abstract

Radiation therapy (RT) has demonstrated strong clinical benefits for patients who present a high relapse risk after breast conserving surgery or radical mastectomy. Unfortunately, the benefits of RT can be offset by its possible impacts on cardiac toxicity and increased risk of death from cardiac events.

Additionally, recent radiological and radiotherapy techniques have allowed clinicians to better define target volumes and customize irradiation so that doses to the heart and left coronary artery can be accurately quantified. Alternative treatment positions, such as the lateral and prone positions are also being used. These positions can adapt to the patient's anatomy and thus better protect the heart and lungs.

This paper will report the outcomes for a patient who received breast cancer treatment after her treatment position and technique were optimized for ideal target volume coverage and minimum irradiation to organs at risk (OAR), particularly to the heart and lungs.

Keywords: Breast cancer; Radiotherapy; Helical tomotherapy; Organs at risk

Introduction

Radiation therapy (RT) has demonstrated strong clinical benefits for patients who present a high relapse risk after breast-conserving surgery or radical mastectomy [1]. Unfortunately, the benefits of RT can be offset by its possible impacts on cardiac toxicity and increased risk of death from cardiac events [2-4]. However, most trials have split their patients into groups that received either systemic therapy or RT but did not describe the clinical context of these events [3]. Additionally, recent radiological and radiotherapy techniques have allowed clinicians to better define target volumes and customize irradiation so that doses to the heart and left coronary artery [2,5,6] can be accurately quantified. Alternative treatment positions, such as the lateral and prone positions [7,8] are also being used. These positions can adapt to the patient's anatomy and thus better protect the heart and lungs.

The Intensity-Modulated Radiotherapy, delivered using several techniques, has been assessed in breast cancer and presents dosimetric advantages compared to the Three-Dimensional Conformal Radiotherapy, in terms of coverage of the target volumes [9] and of sparing of the organs at risk (OAR) [10]. By patients presenting difficult target volumes due to their anatomy or bilateral breast treatment, the Helical Tomotherapy (HT) seems to provide promising dosimetric results with an acceptable clinical tolerance [11].

This paper will report the outcomes for a patient who received breast cancer treatment using HT for a tumor localized at the inner edge. Her treatment position and technique were optimized for ideal target volume coverage and minimum irradiation to the OAR, particularly to the heart and lungs.

Patient's Presentation

A 59-year-old female patient underwent breast-conserving surgery and axillary lymph node dissection for infiltrating ductal carcinoma (IDC) of the lower inner quadrant of the left breast (pT2pN0M0). The 28-mm lesion was grade II, estrogen-receptor positive, progesterone-

receptor negative, and HER2-negative. There was no lympho-vascular involvement (LVI) and the surgical margins and the nine resected axillary lymph nodes were free of disease. However, the patient refused chemotherapy and was thus referred to the Department of Radiation Oncology at Institut Curie. The multidisciplinary clinics decided to deliver chemotherapy followed by radiotherapy to the whole breast with a boost to the tumor bed, followed by an hormonotherapy using aromatase inhibitors. Also, due to the internal position and the size of the treated lesion [12,13], the internal mammary (IMN) and supra-clavicular nodes (SCN) required irradiation. The target volumes and OAR were then delineated on the planning CT scan in a treatment position as previously reported [14,15]. The patient refused the chemotherapy and has been treated by radiotherapy followed by letrosolo.

Dosimetry was first assessed using Institut Curie's field-in-field technique [16] with the patient in the supine position. However, because the tangential fields included a maximal heart distance (MHD) of 2.6 cm and a central lung distance (CLD) of 3.1 cm, the patient's radiation oncologist did not approve the plan (Figure 1). A new CT scan in the lateral isocentric position was thus taken and a new dosimetric plan was completed (Figure 2). Although this plan resulted in low doses to the heart and lungs, the radiation oncologist again refused it due to suboptimal coverage of the tumor bed volume and surgical clips area.

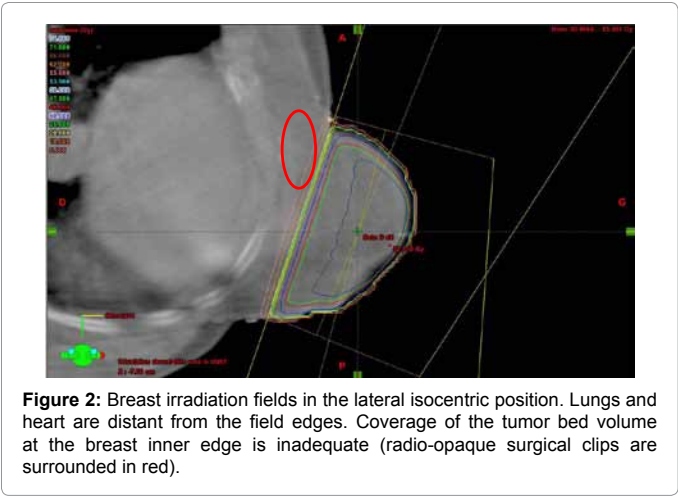
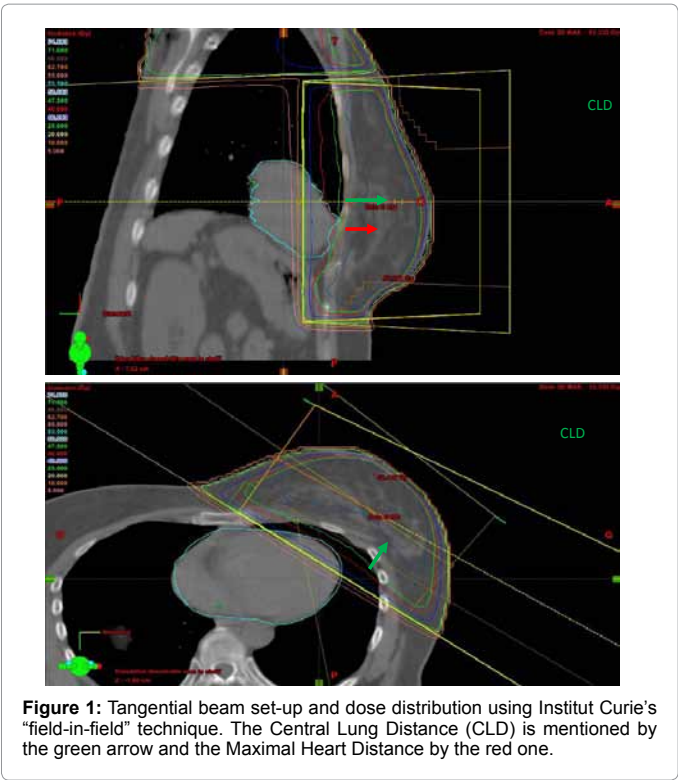
The patient's case was thus discussed at Institut Curie's weekly radiotherapy meeting, and Helical Tomotherapy® (HT) (Accuray

***Corresponding author:** Dr. Youlia M. Kirova, Department of Radiation Oncology, Institut Curie, 26, Rue d'Ulm, 75005 Paris, France, Tel: 331 44 32 41 93; Fax: 331 44 32 46 16; E-mail: youlia.kirova@curie.net

Received April 24, 2012; Accepted May 22, 2012; Published May 25, 2012

Citation: Jacob J, Campana F, Chira C, Peurien D, Daveau C, et al. (2012) Can Helical Tomotherapy be used as a Safe Treatment Alternative for Breast Cancer Patients? J Nucl Med Radiat Ther S6:002. doi:10.4172/2155-9619.S6-002

Copyright: © 2012 Jacob J, et al. This is an open-access article distributed under the terms of the Creative Commons Attribution License, which permits unrestricted use, distribution, and reproduction in any medium, provided the original author and source are credited.



Target volumes	3D-CRT (dorsal decubitus)	3D-CRT (lateral isocentric decubitus)	HT
Left breast	95.7%	78.0%	102.6%
Tumor bed	95.0%	91.7%	96.2%

3D-CRT: three-dimensional conformal radiotherapy; HT: Helical tomotherapy

Table 1: Delivered relative doses to 95% of the planning target volume.

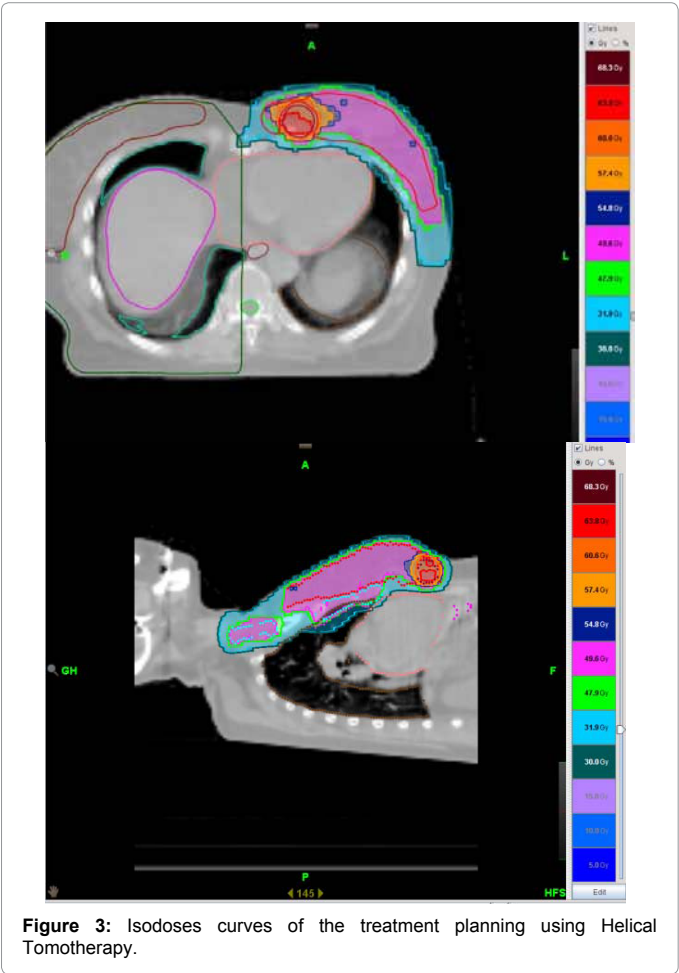
Incorporated, Sunnyvale, CA, USA) was suggested and the dosimetry was realized using Tomotherapy Planning System. When the dosimetric study for HT was analyzed (Figure 3), it became clear that HT could deliver optimal coverage to the planning target volumes (Table 1 and 2) while also providing acceptable doses to the patient's heart and lungs (Table 3). Using a previously reported fractionation scheme [17], the integrated boost was then delivered to the tumor bed. Treatment-

related toxicity was scored using the Common Terminology Criteria for Adverse Events (v3. 2006). The patient experienced acute grade 1 skin toxicity.

Currently, one year after the Tomotherapy treatment, there is no late toxicity, the patient is still under letrozole and she is regularly followed up.

Discussion and Conclusions

This case illustrates how to customize radiation treatment and decrease the probability of long-term adverse effects through correct patient position, treatment planning, and delivery. Additionally, newly available treatment techniques and modalities allow breast cancer radiotherapy to adapt to a patient's anatomy, deliver optimal coverage to treatment volumes, and minimize dosage to OAR. HT also proved to be a better option for this patient than 3D conformal radiotherapy with the field-in-field technique or the lateral decubitus position. Finally, this



Planning target volumes	Minimum dose (Gy)	Maximum dose (Gy)	Median dose (Gy)	Mean dose (Gy)
Left breast	34.1	64.2	52.5	52.6
Tumoral bed	60.4	66.4	64.1	64.0
Internal mammary nodes	43.3	54.5	50.9	50.9
Supra-clavicular nodes	44.9	58.8	50.9	51.0

Table 2: Delivered doses to the planning target volumes.

Organs	3D-CRT (dorsal decubitus)	3D-CRT (lateral isocentric decubitus)	HT
Heart	8.1	4.5	9.0
Ipsilateral lung	19.6	8.6	12.7
Controlateral lung	0.8	0.2	5.9

3D-CRT: Three-dimensional conformal radiotherapy, HT: Helical tomotherapy

Table 3: Mean doses (Gy) delivered to organs at risk.

case study supports other published experiences with dosimetry [17-19]. To confirm these dosimetric results, however, prospective studies with a thorough clinical description of patient status, especially cardiac disease risks, are needed [20]. This clinical observation is an example that the early breast cancer treatment becomes highly performant and the radiotherapy tailoring is currently a part of the everyday routine practice.

References

- Early Breast Cancer Trialists' Collaborative Group (2000) Favourable and unfavourable effects on long-term survival of radiotherapy for early breast cancer: an overview of the randomised trials. *Lancet* 355: 1757-1570.
- Giordano SH, Kuo YF, Freeman JL, Buchholz TA, Hortobagyi GN, et al. (2005) Risk of Cardiac Death After Adjuvant Radiotherapy for Breast Cancer. *J Natl Cancer Inst* 97: 419-424.
- Chargari C, Kirov KM, Bollet MA, Magné N, Védrine L, et al. (2011) Cardiac toxicity in breast cancer patients: From a fractional point of view to a global assessment. *Cancer Treat Rev* 37: 321-330.
- Taylor CW, McGale P, Povall JM, Thomas E, Kumar S, et al. (2009) Estimating cardiac exposure from breast cancer radiotherapy in clinical practice. *Int J Radiat Oncol Biol Phys* 73: 1061-1068.
- Feng M, Moran JM, Koelling T, Chughtai A, Chan JL, et al. (2011) Development and Validation of a Heart Atlas To Study Cardiac Exposure to Radiation Following Treatment for Breast Cancer. *Int J Radiat Oncol Biol Phys* 79: 10-18.
- Kirova YM, de Almeida CE, Canary PC, Kuroki Y, Massabeau C, et al. (2011) Heart, coronaries and breast cancer radiotherapy. *Breast* 20: 196-197.
- Campana F, Kirova YM, Rosenwald JC, Dendale R, Vilcoq JR, et al. (2005) Breast radiotherapy in the lateral decubitus position: A technique to prevent lung and heart irradiation. *Int J Radiat Oncol Biol Phys* 61: 1348-1354.
- Goodman KA, Hong L, Wagman R, Hunt MA, McCormick B. (2004) Dosimetric analysis of a simplified intensity modulation technique for prone breast radiotherapy. *Int J Radiat Oncol Biol Phys* 60: 95-102.
- Kestin LL, Sharpe MB, Frazier RC, Vicini FA, Yan D, et al. (2000) Intensity modulation to improve dose uniformity with tangential breast radiotherapy: initial clinical experience. *Int J Radiat Oncol Biol Phys* 48: 1559-1568.
- Popescu CC, Olivetto I, Patenaude V, Wai E, Beckham WA (2006) Inverse-planned, dynamic, multi-beam, intensity-modulated radiotherapy (IMRT): a promising technique when target volume is the left breast and internal mammary nodes. *Med Dosim* 31: 283-291.
- Cendales R, Schiappacasse L, Schnitman F, Garcia G, Marsiglia H (2011) Helical tomotherapy in patients with breast cancer and complex treatment volumes. *Clin Transl Oncol* 13: 268-274.
- Freedman GM, Fowble BL, Nicolaou N, Sigurdson ER, Torosian MH, et al. (2000) Should internal mammary lymph nodes in breast cancer be a target for the radiation oncologist? *Int J Radiat Oncol Biol Phys* 46: 805-814.
- Veronesi U, Cascinelli N, Bufalino R, Morabito A, Greco M, et al. (1983) Risk of internal mammary lymph node metastases and its relevance on prognosis of breast cancer patients. *Ann Surg* 198: 681-684.
- Kirova YM, Castro Pena P, Dendale R, Servois V, Bollet MA, et al. (2010) Simplified rules for everyday delineation of lymph node areas for breast cancer radiotherapy. *Br J Radiol* 83: 683-686.
- Kirova YM, Castro Pena P, Hijal T, Fournier-Bidoz N, Laki F, et al. (2010) Improving the definition of tumor bed boost with the use of surgical clips and image registration in breast cancer patients. *Int J Radiat Oncol Biol Phys* 78: 1352-1355.
- Fournier-Bidoz N, Kirova Y, Campana F, El Barouky J, Zefkili S, et al. (2009) Technique alternatives for breast radiation oncology: Conventional radiation therapy to tomotherapy. *J Med Phys* 34: 149-152.
- Hijal T, Fournier-Bidoz N, Castro-Pena P, Kirova YM, Zefkili S, et al. (2010) Simultaneous integrated boost in breast conserving treatment of breast cancer: a dosimetric comparison of helical tomotherapy and three-dimensional conformal radiotherapy. *Radiother Oncol* 94: 300-306.
- Goddu SM, Chaudhari S, Mamlui-Hunter M, Pechenaya OL, Pratt D, et al. (2009) Helical tomotherapy planning for left-sided breast cancer patients with positive lymph nodes: comparison to conventional multiport breast technique. *Int J Radiat Oncol Biol Phys* 73: 1243-1251.
- Zhong GX, Xu SP, Dai XK, Ju ZJ, Gong HS et al. (2011) Clinical Dosimetric Study of Three Radiotherapy Techniques for Postoperative Breast Cancer: Helical Tomotherapy, IMRT, and 3D-CRT. *Technol Cancer Res Treat* 10:15-23.
- Askoxylakis V, Jensen AD, Häfner MF, Fetzner L, Sterzing F, et al. (2011) Simultaneous integrated boost for adjuvant treatment of breast cancer—intensity modulated vs. conventional radiotherapy: the IMRT-MC2 trial. *BMC Cancer* 11: 249.

This article was originally published in a special issue, [Cancer Radiation Therapy](#) handled by Editor(s). Dr. XinChen, University of Arkansas for Medical Sciences, USA