

FDG-PET, a Complementary Modality to Computed-Tomography in Radiotherapy Target Volume Delineation for Head and Neck Cancer

Voichita Bar-Ad^{1*}, Wenyin Shi¹, Madalina Tuluc², Nitin Ohri¹, David Cagnetti³, Joseph Curry³ and Charles Intenso⁴

¹Department of Radiation Oncology, Thomas Jefferson University, Philadelphia, USA

²Department of Pathology, Thomas Jefferson University, Philadelphia, USA

³Department of Otorhinolaryngology, Thomas Jefferson University, Philadelphia, USA

⁴Department of Nuclear Medicine, Thomas Jefferson University, Philadelphia, USA

Abstract

Objectives: The objective of the current review was to use published data to assess the role of [¹⁸F] fluorodeoxyglucose-positron emission tomography (FDG-PET) as a complementary modality to computed-tomography (CT) in radiotherapy target volume delineation for head and neck cancer (HNC).

Methods: Studies were identified by searching PubMed electronic databases. Both prospective and retrospective studies were included. Information regarding the role of FDG-PET for radiotherapy target volume delineation for HNC was analyzed.

Results: FDG-PET is a promising tool for improving radiotherapy target volume delineation by defining a metabolically active biological target volume (BTv). The use of novel PET tracers representing properties such as hypoxia, protein synthesis and proliferation remain to be better characterized.

Conclusions: The role of FDG-PET for radiotherapy target volume delineation for patients with HNC is expanding and should be further evaluated in clinical trials.

Keywords: FDG-PET; Radiotherapy target volumes; Head and neck cancer

Introduction

Positron emission tomography (PET) is a functional imaging study that is now frequently used for staging, treatment planning and post-treatment surveillance of malignant tumors including HNC due to the additional valuable biological information it provides over structural imaging [1,2]. It is a non-invasive technique that provides biological characteristics of the tumor “*In-vivo*”, which may be monitored and quantified before, during and following the treatment of head and neck (HNC). The most commonly used positron-emitting tracer in oncology is the glucose analog [¹⁸F]fluorodeoxyglucose (FDG), which accumulates in a wide variety of tumors due to the increased cellular metabolic demand and glucose avidity of cancer cells compared to most normal human tissues [2-4]. Malignant cells take up and entrap the radiolabelled glucose, which is not metabolized further and acts as a positron-emitting tracer. Although the use of FDG-PET in the evaluation of head and neck cancer is promising, its role in the treatment planning for HNC has not been completely elucidated. The purpose of the present review is to describe the current clinical evidence for the application of FDG-PET in radiotherapy planning for patients with HNC.

The impact of FDG-PET on the initial staging of head and neck cancer

The majority of patients with HNC present with locoregionally advanced disease, involving the cervical lymph node. Correct staging of the cervical lymph nodes is vital to determine the necessary extent of neck dissection and for precise delineation of radiotherapy target volumes and fields.

Standard staging techniques used for HNC include clinical examination, computed tomography (CT) and magnetic resonance imaging (MRI). Characteristics used in the interpretation of CT and MRI in staging cervical lymph nodes include lymph node size, the

presence of central necrosis, enhancement patterns, imprecise nodal margins and obliteration of fat or tissue planes [5-8]. FDG-PET appears to be at least as sensitive as or slightly more sensitive than conventional imaging for the initial staging of nodal metastases in patients with HNC [5]. Recent studies reported an average sensitivity of 87% to 90% and an average specificity of 80% to 93% for FDG-PET in the detection of nodal metastases, which compares favorably with the sensitivity (61% to 97%) and specificity (21% to 100%) of CT and MRI [5]. However, the impact of PET staging of cervical nodes on eventual clinical outcome is not well established.

As MRI technology advances, MRI may equal or potentially surpass the accuracy of PET in the initial locoregional staging of HNC. Dammann et al. prospectively compared FDG-PET, CT and MRI for initial staging of HNC patients and reported that the sensitivity and specificity of MRI in detecting nodal metastases were 93% and 95%, respectively, compared to 85% and 98% for FDG-PET. In view of its higher sensitivity and superior anatomic detail, the authors of that report recommended MRI as the optimal initial imaging modality for HNC [6].

FDG-PET imaging techniques have evolved as well. In particular, the anatomic localization of hypermetabolic activity has been improved

***Corresponding author:** Voichita Bar-Ad, MD, Department of Radiation Oncology, Thomas Jefferson University 111 S. 11th Street, Philadelphia, PA 19107, USA, Tel: 215-955-8194; E-mail: Voichita.BarAd@Jeffersonhospital.org

Received January 09, 2012; **Accepted** February 21, 2012; **Published** February 24, 2012

Citation: Bar-Ad V, Shi W, Tuluc M, Ohri N, Cagnetti D, et al. (2012) FDG-PET, a Complementary Modality to Computed-Tomography in Radiotherapy Target Volume Delineation for Head and Neck Cancer. J Nucl Med Radiat Ther 3:124. doi:10.4172/2155-9619.1000124

Copyright: © 2012 Bar-Ad V, et al. This is an open-access article distributed under the terms of the Creative Commons Attribution License, which permits unrestricted use, distribution, and reproduction in any medium, provided the original author and source are credited.

with the introduction of FDG-PET/CT, which was shown to be more accurate than FDG-PET alone. Syed et al. reported that compared with FDG-PET alone, FDG-PET/CT downstaged disease and changed the recommended management in 17% of patients by correctly assigning areas of increased uptake to fat and muscle tissue. Furthermore, FDG-PET/CT notably improved the confidence in anatomic localization and increased interobserver agreement in assigning lesions to specific anatomical regions [7].

As FDG-PET/CT, MRI and high-resolution CT continue to evolve, it is unclear which modality is currently the most accurate for the initial staging of locoregional disease in HNC. An advantage of FDG-PET/CT is undoubtedly its ability to detect contralateral nodal disease, distant metastatic disease and synchronous primary tumors [8-10]. Numerous studies have demonstrated that FDG-PET may detect occult distant metastases in as many as 10% of patients with locoregionally advanced HNC [5,9,11,13]. Furthermore, HNC patients have a high risk of synchronous malignancies, particularly in the upper aerodigestive tract. FDG-PET might be valuable in detecting such tumors, though its sensitivity in this situation is not clear as relatively few studies address this subject [13-15]. FDG uptake in tumors may also represent a prognostic marker; FDG uptake has been correlated with recurrence risk following surgery and/or radiotherapy [16]. FDG uptake may signify a need for intensification of therapy, but this requires further study.

Radiotherapy target volume delineation

Radiotherapy is an integral part of treatment for many HNC patients. Treatment machines have evolved from orthovoltage X-ray devices to the state-of-the-art linear accelerators that deliver megavoltage radiation. Within the realm of megavoltage radiotherapy, treatment delivery techniques have progressed from two-dimensional open field techniques to three-dimensional conformal radiotherapy to intensity-modulated radiation therapy (IMRT). Each advance has allowed for more conformal radiotherapy dose delivery and increased the ability to spare normal tissues from high-dose irradiation. At the same time, the ability of the radiation oncologist to generate precise target volumes becomes increasingly critical [17].

The first step in radiotherapy planning is to define the target volumes and the organs at risk. Anatomical imaging modalities, such as CT and MRI, remain the most commonly used tools for target delineation in radiotherapy. Traditionally, CT has been used to delineate radiotherapy target volumes. Certain MRI sequences, especially T1-weighted and T2-weighted imaging, are more accurate than CT for determining the extent of soft tissue involvement, especially for tumors of the tongue and nasopharynx [18,19]. However, commercial radiotherapy planning platforms use CT data to create an electron density map for dose calculation [17]. Therefore, MRI or functional imaging studies like PET cannot be used independently for radiotherapy planning and must be fused with CT. CT, unfortunately, may be affected by artifacts from dense materials, such as dental fillings or prosthetic joints. This can make CT imaging inaccurate for the aforementioned dose calculations, unless appropriate corrections are made [17].

The role of FDG-PET in radiotherapy target delineation for head and neck tumors

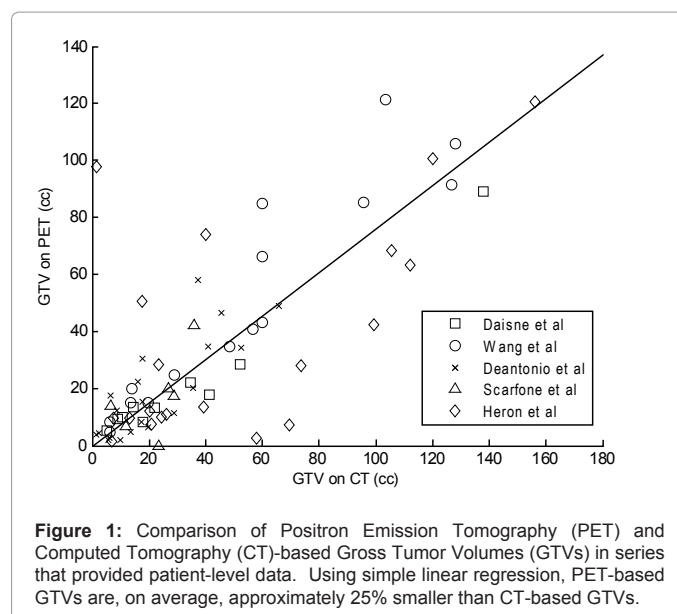
Despite technological advances in radiation oncology, the locoregional recurrence rate for HNC patients is still significant [20]. As techniques for more accurate radiotherapy delivery to head and neck tumors such as IMRT have developed rapidly, improvements

in localizing disease have been harder to achieve. Functional imaging studies, such as FDG-PET, promise to improve target volume delineation by allowing clinicians to define a metabolically active biological target volume (BTv) [17].

Gross tumor volume (GTV), is classically defined as the grossly visible tumor and metastatic lymphadenopathy based on physical examination and anatomic imaging studies. Radiotherapy target volumes, however, may be significantly modified when FDG-PET data are incorporated in the treatment planning process. FDG-PET may be utilized in radiation therapy planning by importing an FDG-PET study set into the treatment planning software and co-registering it with the treatment planning CT scan. Use of the same immobilization head mask for both planning CT and FDG-PET allow for precise co-registration. Modern studies have demonstrated the feasibility of successful co-registration between PET-CT and the CT planning imaging [21].

Radiotherapy target volumes defined on FDG-PET may be larger or smaller than volumes outlined using CT information alone [21-39] (Table 1 and Figure 1). The total target volume may increase when metabolically active tumor is detected in cervical lymph nodes that are not enlarged. On the other hand, an FDG-PET-based GTV may be smaller than a CT-based GTV in the case of a partially necrotic tumor. Studies have also demonstrated that FDG-PET/CT guided IMRT planning may selectively target and intensify the treatment of head and neck cancer while reducing the dose to critical normal structures. Moreover, FDG-PET can identify areas within the conventional target volume that are particularly hypermetabolic that may be possible biological target volumes for dose escalation studies in the future.

Daisne et al. compared the GTVs of primary laryngeal tumors generated using CT, MRI, FDG-PET and surgical pathology in 9 HNC patients who underwent total laryngectomy. Nodal volumes were not delineated. Surgical specimens were significantly smaller (average: 12.6 cm³), than they appeared on each imaging modality (average volume of 20.8 cm³ with CT, 23.8 cm³ with MRI and 16.3 cm³ with FDG-PET). Interestingly, each imaging modality failed to detect the superficial extent of the laryngeal tumors, underestimating the superficial tumor extension into the mucosa of the contralateral larynx and extralaryngeal



Study	Number of patients	CT/MRI/PET/PET-CT radiotherapy target volumes
Ciernik et al. [21]	39 (12 patients with head and neck cancer)	≥ 25% GTV increase with PET-CT vs CT ≥ 25% GTV decrease with PET-CT vs CT
Heron et al. [23]	21	Mean GTV 42.7 cm ³ with PET vs 65 cm ³ with CT
Scarfone et al. [24]	6	Mean GTV primary tumor 22.2 cm ³ with CT vs 19.9 cm ³ with PET
Paulino et al. [27]	40	Median GTV 20.3 cm ³ with PET vs 37.2 cm ³ with CT
Newbold et al. [32]	18 (9 unknown primary tumors)	Median 6.1 cm ³ increase in GTV (combined primary and nodal) with PET-CT vs CT for known primary tumors Median 10.1 cm ³ increase in CTV with PET-CT for known primary site Median 6.3 cm ³ increase in GTV with PET-CT vs CT for unknown primary tumors Median 155.4 cm ³ increase in CTV with PET-CT vs CT for unknown primary tumors
Guido et al. [33]	38	Mean GTV for CT 34.54 cm ³ vs 29.38 cm ³ for PET-CT
Breen et al. [36]	10	Mean GTV primary tumor 26.9 cm ³ with CT vs 27.7 cm ³ with CE-CT vs 26.5 cm ³ with PET/CT
Wang et al. [35]	28	Mean GTV 68.8 cm ³ with CT vs 61.8 cm ³ with PET-CT
Deantonio et al. [34]	22	Mean GTV with PET/CT 26.0 cm ³ (composite volume between PET and CT) Mean GTV 5.5 cm ³ with PET Mean GTV 8.1 cm ³ with CT Mean GTV 11.2 cm ³ with CT&PET (the common volume of the two imaging modalities)
El-Bassiouni et al. [38]	25	Median GTV for CT 29.6 cm ³ , mean GTV for CT 41.6 cm ³ Median GTV for PET 23.0 cm ³ , mean GTV for PET 34.2 cm ³ Median PTV for CT 171.5 cm ³ , mean PTV for CT 204.1 cm ³ Median PTV for PET 127.7 cm ³ , mean PTV for PET 165.9 cm ³
Daisne et al. [39]	29 (9 with total laryngectomy)	Oropharyngeal tumors: Mean GTV 32.0 cm ³ with CT Mean GTV 27.9 cm ³ with MRI Mean GTV 20.3 cm ³ with PET Laryngeal and hypopharyngeal tumors: Mean GTV 21.4 cm ³ with CT Mean GTV 21.4 cm ³ with MRI Mean GTV 16.4 cm ³ with PET Mean surgical GTV 12.6 cm ³

FDG-PET, [¹⁸F]Fluoro-Deoxy-Glucose-Positron Emission Tomography, CT, Computed Tomography, MRI, Magnetic Resonance Imaging, PET-CT, Positron Emission Tomography-Computed Tomography, CE-CT, Contrast Enhanced Computed Tomography, GTV, gross tumor volume, CTV, Clinical Target Volume, PTV, Planning Target Volume

Table 1: FDG-PET for radiotherapy target volumes delineation for head and neck cancer.

extension. Furthermore, there was a high tendency for geographic mismatch both between the imaging modalities and with the surgical specimen. Since eight of nine patients in that series were diagnosed with T4 laryngeal tumors, its results may not apply to earlier stages of laryngeal cancer or other HNC sites [39].

One major source of difference in GTV delineation is the interobserver variability. Breen et al. studied 10 patients with HNC. For each patient, the GTV of the primary tumor was delineated by a total of 8 specialists (6 head and neck radiation oncologists and 2 head and neck neuroradiologists) on CT, PET-CT and contrast-enhanced CT imaging. Metastatic lymph nodes were excluded from these volumes. The analysis demonstrated a high concordance between volumes delineated by experienced radiation oncologists. Furthermore, the addition of PET-CT for HNC primary tumor delineation did not change the GTV [36]. In contrast, Riegel et al. evaluated GTV delineation variability among multiple physicians on CT and PET-CT fusion for 16 HNC patients. A significant interobserver variability was reported not only between all the physicians, but also between the radiation oncologists [37].

Although the use of FDG-PET is gaining acceptance for target volume delineation for HNC in the radiation oncology community, techniques for contouring GTV using FDG-PET have not been standardized. Target volumes may be significantly overestimated or underestimated, depending on the windowing level, when contours

are generated manually [24,25]. The lack of widely validated protocols, which introduces a significant source of heterogeneity across studies, may explain the inconsistencies in published reports. Differences in imaging acquisition techniques may introduce additional elements of heterogeneity. Studies have not yet demonstrated the impact of using FDG-PET for radiotherapy target volume delineation on clinical outcomes for HNC patients.

The role of novel PET tracers for HNC

Despite significant research efforts and widespread clinical use of FDG-PET, the optimal manner in which FDG-PET should be implemented in the management of HNC patients remains undefined. Less clear still is the role of novel PET tracers, designed to depict biological characteristics such as hypoxia, protein synthesis, cell proliferation and apoptosis, in HNC patient care. One or more of these tracers may one day facilitate functional imaging-based individualization of treatment strategies [40-55].

Hypoxia has been recognized as an adverse prognostic factor for HNC patients treated with definitive radiotherapy [44-46]. 18-F-fluoromisonidazole (FMISO) has been the most studied hypoxic PET tracer and FMISO uptake in imaging studies has been correlated with treatment outcome in HNC [40,41,47]. A newer agent, fluorine-18 fluorozomycin arabinoside (18FAZA), has the advantage of a faster blood clearance than FMISO, resulting in improved target-to-background contrast and should be further studied in clinical trials

[43,44]. Furthermore, recent results have suggested a potential benefit of the hypoxic radiosensitizer tirapazamine for selected HNC patients who were at high risk for locoregional failure (smokers and patients with HPV negative tumors), had evidence of hypoxia on functional imaging and received high-quality radiotherapy [47-49].

Accelerated repopulation is a well-known mechanism of HNC radioresistance [50]. “*In-vivo*” measurement of cellular proliferation by functional imaging using tracers such as 32-deoxy-32-(18)F fluorothymidine (FLT) may provide valuable information in the setting of early tumor response assessment [51,52] and possibly guide focal intensification of therapy to tumor regions that demonstrate accelerated repopulation.

Besides high glucose metabolism, most epithelial tumors also exhibit high levels of protein synthesis. Based on this principle, tracers such as 11C-methionine (MET), which are markers of high protein metabolism, may provide clinical utility. The role of MET-PET in evaluation of early tumor response to radiotherapy for HNC and delineation of radiotherapy target volumes remains to be determined [53-55].

Conclusions

The use of PET is gaining acceptance for radiotherapy target volume delineation in HNC. Addition study is required to demonstrate the impact of PET in this role on the clinical outcome of HNC patients. Recent data suggest that novel hypoxia and cell proliferation tracers, such as FMISO and FLT, could allow early response evaluation and potentially identify subvolumes for targeted radiotherapy dose escalation.

References

1. Strauss LG, Conti PS (1991) The applications of PET in clinical oncology. J Nucl Med 32: 623-648.
2. Price P, Jones T (1995) Can positron emission tomography (PET) be used to detect subclinical response to cancer therapy? The EC PET Oncology Concerted Action and the EORTC PET Study Group. Eur J Cancer 31: 1924-1927.
3. Wahl RL, Hutchins GD, Buchsbaum DJ, Liebert M, Grossman HB, et al. (1991) 18F-2-deoxy-2-fluoro-D-glucose uptake into human tumor xenografts. Feasibility studies for cancer imaging with positron-emission tomography. Cancer 67: 1544-1550.
4. Gallagher BM, Fowler JS, Gutterson NF, MacGregor RR, Wan CN, et al. (1978) Metabolic trapping as a principle of radiopharmaceutical design: some factors responsible for the biodistribution of [¹⁸F]-2-deoxy-2-fluoro-D-glucose. J Nucl Med 19: 1154-1161.
5. Schoder H, Yeung HW (2004) Positron emission imaging of head and neck cancer, including thyroid carcinoma. Semin Nucl Med 34: 180-197.
6. Dammann F, Horger M, Mueller-Berg M, Schlemmer H, Claussen CD, et al. (2005) Rational diagnosis of squamous cell carcinoma of the head and neck region: Comparative evaluation of CT, MRI, and 18FDG PET. AJR Am J Roentgenol 184: 1326-1331.
7. Syed R, Bomanji JB, Nagabhushan N, Hughes S, Kayani I, et al. (2005) Impact of combined (18)FDG PET/CT in head and neck tumors. Br J Cancer 92: 1046-1050.
8. Sigg MB, Steinert H, Gratz K, Hugenin P, Stoeckli S, et al. (2003) Staging of head and neck tumors: [18F]fluorodeoxyglucose positron emission tomography compared with physical examination and conventional imaging modalities. J Oral Maxillofac Surg 61: 1022-1029.
9. Teknos TN, Rosenthal EL, Lee D, Taylor R, Marn CS (2001) Positron emission tomography in the evaluation of stage III and IV head and neck cancer. Head Neck 23: 1056-1060.
10. Goerres GW, Schmid DT, Gratz KW, von Schulthess GK, Eyrich GK (2003) Impact of whole body positron emission tomography on initial staging and therapy in patients with squamous cell carcinoma of the oral cavity. Oral Oncol 39: 547-551.
11. Schmid DT, Stoeckli SJ, Bandhauer F, Huguenin P, Schmid S, et al. (2003) Impact of positron emission tomography on the initial staging and therapy in locoregional advanced squamous cell carcinoma of the head and neck. Laryngoscope 113: 888-891.
12. Schwartz DL, Rajendran J, Yueh B, Coltrera M, Anzai Y, et al. (2003) Staging head and neck squamous cell cancer with extended-field FDG-PET. Arch Otolaryngol Head Neck Surg 129: 1173-1178.
13. Keyes JW Jr, Chen MY, Watson NE Jr, Greven KM, McGuirt WF, et al. (2000). FDG PET evaluation of head and neck cancer: value of imaging the thorax. Head Neck 22: 105-110.
14. Wax MK, Myers LL, Gabalski EC, Husain S, Gona JM, et al. (2002) Positron emission tomography in the evaluation of synchronous lung lesions in patients with untreated head and neck cancer. Arch Otolaryngol Head neck Surg 128: 703-707.
15. Perlow A, Bui C, Shreve P, Sundgren PC, Teknos TN, et al. (2004) High incidence of chest malignancy detected by FDG PET in patients suspected of recurrent squamous cell carcinoma of the upper aerodigestive tract. J Comput Assist Tomogr 28: 704-709.
16. Allal AS, Slosman DO, Kebdani T, Allaoua M, Lehmann W, et al. (2004) Prediction of outcome in head-and-neck cancer patients using the standardized uptake value of 2-[18F]fluoro-2-deoxy-D-glucose. Int J Radiat Oncol Biol Phys 59: 1295-1300.
17. Dandekar P, Partridge M, Kazi R, Nutting C, Harrington K, et al. (2010) Challenges in integrating 18FDG PET-CT into radiotherapy planning of head and neck cancer. Indian J Cancer 47: 260-263.
18. Park JO, Jung SL, Joo YH, Jung CK, Vho KJ, et al. (2011) Diagnostic accuracy of magnetic resonance imaging (MRI) in the assessment of tumor invasion depth in oral/oropharyngeal cancer. Oral Oncol 47: 381-386.
19. King AD, Bhatia KS (2010) Magnetic resonance imaging staging of nasopharyngeal carcinoma in the head and neck. World J Radiol 2: 159-165.
20. Bernier J. (2008) A multidisciplinary approach to squamous cell carcinomas of the head and neck: an update. Cur Opin Oncol 20: 249-255.
21. Ciernik IF, Dizendorf E, Baumert BG, Reiner B, Burger C, et al. (2003) Radiation treatment planning with an integrated positron emission and computer tomography (PET/CT): a feasibility study. Int J Radiat Oncol Biol Phys 57: 853-863.
22. Nishioka T, Shiga T, Shirato H, Tsukamoto E, Tsuchiya K, et al. (2002) Image fusion between 18FDG-PET and MRI/CT for radiotherapy planning of oropharyngeal and nasopharyngeal carcinomas. Int J Radiat Oncol Biol Phys 53: 1051-1057.
23. Heron DE, Andrade RS, Flickinger J, Johnson J, Agarwala SS, et al. (2004) Hybrid PET-CT simulation for radiation treatment planning in head-and-neck cancers: a brief technical report. Int J Radiat Oncol Biol Phys 60: 1419-1424.
24. Scarfone C, Lavelly WC, Cmelak AJ, Delbeke D, Martin WH, et al. (2004) Prospective feasibility trial of radiotherapy target definition for head and neck cancer using 3-dimensional PET and CT imaging. J Nucl Med 45: 543-552.
25. Paulino AC, Johnstone PA (2004) FDG-PET in radiotherapy treatment planning: Pandora's box? Int J Radiat Oncol Biol Phys 59: 4-5.
26. Schwartz DL, Ford EC, Rajendran J, Yueh B, Coltrera MD, et al. (2005) FDG-PET/CT-guided intensity modulated head and neck radiotherapy: A pilot investigation. Head Neck 27: 478-487.
27. Paulino AC, Koshy M, Howell R, Schuster D, Davis LW, et al. (2005) Comparison of CT- and FDG-PET-defined gross tumor volume in intensity-modulated radiotherapy for head- and-neck cancer. Int J Radiat Oncol Biol Phys 61: 1385-1392.
28. Geets X, Daisne JF, Tomsej M, Duprez T, Lonnew M, et al. (2006) Impact of the type of imaging modality on target volumes delineation and dose distribution in pharyngo-laryngeal squamous cell carcinoma: comparison between pre- and post-treatment studies. Radiother Oncol 78: 291-297.
29. Geets X, Tomsej M, Lee JA, Duprez T, Coche E, et al. (2007) Adaptive biological image-guided IMRT with anatomic and functional imaging in pharyngo-laryngeal tumors: impact on target volume delineation and dose distribution using helical tomography. Radiother Oncol 85: 105-115.

30. Castadot P, Geets X, Lee JA, Gregoire V (2011) Adaptive functional image-guided IMRT in pharyngo-laryngeal squamous cell carcinoma: Is the gain in dose distribution worth the effort? *Radiother Oncol* 101: 343-350.
31. Soto DE, Kessler ML, Piert M, Eisbruch A (2008) Correlation between pretreatment FDG-PET biological target volume and anatomical location of failure after radiation therapy for head and neck cancers. *Radiother Oncol* 89: 13-18.
32. Newbold KL, Partridge M, Cook G, Sharma B, Rhys-Evans P, et al. (2008) Evaluation of the role of 18FDG-PET/CT in radiotherapy target definition in patients with head and neck cancer. *Acta Oncol* 47: 1229-1236.
33. Guido A, Fuccio L, Rombi B, Castellucci P, Cecconi A, et al. (2009) Combined 18-F-FDG-PET/CT imaging in radiotherapy target delineation for head-and-neck cancer. *Int J Radiat Oncol Biol Phys* 73: 759-763.
34. Deantonio L, Beldi D, Gambaro G, Loi G, Brambilla M, et al. (2008) FDG-PET/CT imaging for staging and radiotherapy treatment planning of head and neck carcinoma. *Radiother Oncol* 3: 29.
35. Wang D, Schultz CJ, Jursinic PA, Bialkowski M, Zhu XR, et al. (2006) Initial experience of FDG-PET/CT guided IMRT of head-and-neck carcinoma. *Int J Radiat Oncol Biol Phys* 65:143-151.
36. Breen SL, Publicover J, De Silva S, Pond G, Brock K, et al. (2007) Intraobserver and interobserver variability in GTV delineation on FDG-PET-CT images of head and neck cancers. *Int J Radiat Oncol Biol Phys* 68:763-770.
37. Riegel AC, Berson AM, Destian S, Ng T, Tena LB, et al. (2006) Variability of gross tumor volume delineation in head-and-neck cancer using CT and PET/CT fusion. *Int J Radiat Oncol Biol Phys* 65: 726-732.
38. El-Bassiouni M, Ciernik IF, Davis JB, El-Attar I, Reiner B, et al. (2007) [18FDG] PET-CT-based intensity-modulated radiotherapy treatment planning of head and neck cancer. *Int J Radiat Oncol Biol Phys* 69: 286-293.
39. Daisne JF, Duprez T, Weynand B, Lonnew M, Hamoir M, et al. (2004) Tumor volume in pharyngolaryngeal squamous cell carcinoma: comparison at CT, MR imaging, and FDG PET and validation with surgical specimen. *Oncology* 233: 93-100.
40. Thorwarth D, Eschmann SM, Scheiderbauer J, Paulsen F, Alber M. (2005) Kinetic analysis of dynamic 18Ffluoromisonidazole PET correlates with radiation treatment outcome in head-and-neck cancer. *BMC Cancer* 5:152.
41. Hicks RJ, Rischin D, Fisher R, Binns D, Scott AM, et al. (2005) Utility of FMISO PET in advanced head and neck cancer treated with chemoradiation incorporating a hypoxia-targeting chemotherapy agent. *Eur J Nucl Med Mol Imaging* 32: 1384-1391.
42. Sorger D, Patt M, Kumar P, Wiebe LI, Barthel H, et al. (2003) [18F] Fluoroazomycinaraboside (18FAZA) and [18F]Fluoromisonisazole (18FMISO): a comparative study of their selective uptake in hypoxic cells and PET imaging in experimental rat tumors. *Nucl Med Biol* 30: 317-326.
43. Piert M, Machulla HJ, Picchio M, Reischl G, Ziegler S, et al. (2005) Hypoxia-specific tumor imaging with 18F-fluoroazamycin arabinoside. *J Nucl Med* 46:106-113.
44. Brizel DM, Sibley GS, Prosnitz LR, Scher RL, Dewhirst MW (1997) Tumor hypoxia adversely affects the prognosis of carcinoma of the head and neck. *Int J Radiat Oncol Biol Phys* 38: 285-289.
45. Nordsmark M, Overgaard J (2004) Tumor hypoxia is independent of hemoglobin and prognostic for loco-regional tumor control after primary radiotherapy in advanced head and neck cancer. *Acta Oncol* 43:396-403.
46. Overgaard J, Eriksen JG, Nordsmark M, Alsner J, Horsman MR (2005) Plasma osteopoetin, hypoxia, and cancer response to the hypoxia sensitizer nimorazole in radiotherapy of head and neck cancer: results from the DAHANCA 5 randomized double-blind placebo controlled trial. *Lancet Oncol* 6: 757-764.
47. Rischin D, Hicks RJ, Fisher R, Binns D, Corry J, et al. (2006) Prognostic significance of [18F]-misonidazole positron emission tomography-detected tumor hypoxia in patients with advanced head and neck cancer randomly assigned to chemoradiation with or without tirazapamine: a substudy of Trans-Tasman Radiation Oncology Group Study 98.02. *J Clin Oncol* 24: 2098-2104.
48. Rischin D, Peters LJ, O'Sullivan B, Giralt J, Fisher R, et al. (2010) Tirapazamine, cisplatin, and radiation versus cisplatin and radiation for advanced squamous cell carcinoma of the head and neck (TROG 02.02.HeadSTART): a phase III trial of the Trans-Tasman Radiation Oncology Group. *J Clin Oncol* 28: 2989-2995.
49. Pryor DI, Solomon B, Porceddu SV (2011) The emerging era of personalized therapy in squamous cell carcinoma of the head and neck. *Asia-Pacific J Clin Oncol* 7: 236-251.
50. Fenwick JD, Pardo-Montero J, Nahum AE, Malik ZI (2011) Impact of schedule duration on head and neck radiotherapy: Accelerated tumor repopulation versus compensatory mucosal proliferation. *Int J Radiat Oncol Biol Phys*.
51. Menda Y, Boles Ponto LL, Dornfeld KJ, Tewson TJ, Watkins GL, et al. (2009) Kinetic analysis of 32-deoxy-32-(18F)-fluorothymidine ([18F]f-FLT) in head and neck cancer patients before and early after initiation of chemoradiation therapy. *J Nucl Med* 50: 1028-1035.
52. Troost EG, Bussink J, Hoffmann AL, Boerman OC, Oyen WJ, et al. (2010) 18F-FLT PET/CT for early response monitoring and dose escalation in oropharyngeal tumors. *J Nucl Med* 51: 866-874.
53. Nuutinen J, Jyrkkio S, Lehtikainen P, Lindholm P, Minn H (1999) Evaluation of early response to radiotherapy in head and neck cancer measured with [11C] methionine-positron emission tomography. *Radiother Oncol* 52: 225-232.
54. Geets X, Daisne JF, Gregoire V, Hamoir M, Lonnew M (2004) Role of 11-C-methionine positron emission tomography for the delineation of tumor volume in pharyngo-laryngeal squamous cell carcinoma: comparison with FDG-PET and CT. *Radiother Oncol* 71: 267-273.
55. Hasebe M, Yoshikawa K, Ohashi S, Toubaru S, Kawaguchi K, et al. (2010) A study on the prognostic evaluation of carbon ion radiotherapy for head and neck adenocarcinoma with C-11 methionine PET. *Mol Imaging Biol* 12: 554-562.