

Acute Respiratory Distress Syndrome in a 46-Year-Old Man with NSCLC after Airway Stenting and Chemo-Radiotherapy

Pia C Kraemer* and Azza A Khalil

Department of Oncology, Aarhus University Hospital, Aarhus, Denmark

*Corresponding author: Pia C Kraemer, Aarhus University Hospital Oncology, Norrebrogade 44 Aarhus 8000, Denmark, Tel: +45-20-99-69-66; E-mail: pck@rm.dk

Received date: Jul 01, 2014, Accepted date: Oct 23, 2014, Published date: Oct 27, 2014

Copyright: © 2014 Kraemer PC, et al. This is an open-access article distributed under the terms of the Creative Commons Attribution License, which permits unrestricted use, distribution, and reproduction in any medium, provided the original author and source are credited.

Abstract

Background: Airway stenting is a minimal invasive treatment providing a quick relief of symptoms for patients having airway obstruction. While the use of stenting is well documented in the palliative setting, its role in curative setting is unclear. This case report describes a clinical course that relates to this question that affect the daily clinical practice of oncologists.

Patient: A 46 year old man with a history of heavy smoking; 80 pack year, was diagnosed with bilateral NSCLC and received both chemotherapy and radiotherapy. During radiotherapy the patient developed dyspnoea and a stent was placed in the right main bronchus providing immediate relief. Radiotherapy was continued afterwards.

Case Report

Airway stenting is a minimally invasive treatment that provides quick relief of symptoms for patients suffering from airway obstruction. While the use of stenting is well documented in the palliative setting, its role in the curative setting remains unclear. For example, we do not know whether incomplete stenting enhances abscess formation or if radiotherapy should continue on cavitated lung infection in the presence of the stent.

The present case report addresses these two questions in context of the daily clinical practice of oncologists.

A 46-year-old man was diagnosed with bilateral non-small-cell lung cancer (NSCLC), squamous cell carcinoma, near both the right and the left main bronchi. Computed tomography (CT) showed that the lesions involved the entire lumen of the right and the left upper lobes.

The patient had a long history of heavy smoking; 80 pack years; yet, was in a very good condition (performance status (PS)=0), had no co-morbidity and received no medication.

The patient received chemotherapy with three cycles of Carboplatin (area under the curve (AUC) x 5 given as intravenous perfusion on day one) combined with Vinorelbine (60 mg/m² on day one and eight as tablets) given as 21-day cycles. The patient proceeded to daily radiotherapy after having received induction therapy. The irradiation target included both lung tumours and pathologically enlarged mediastinal lymph nodes. The planning target volume (PTV) was covered with a total dose of 60 Gy in 30 fractions. The plan respected the local guidelines for normal tissue constraints with 38% of the lung volume receiving 20 Gy or more. The mean lung dose (MLD) was 21 Gy.

After three fractions of radiotherapy the patient developed dyspnoea and started high-dose prednisolone 50 mg daily and achieved clinical improvement for a few days. The situation later deteriorated and a chest CT was performed which showed right-sided progression of the tumour, which was compressing the right main bronchus leaving only 2 mm worth of passage for airflow. Cavitated

infiltrates were seen in the right upper lobe (Figure 1), which could indicate either metastasis or abscesses/infection. Regression of the tumour on the left side raised the possibility that the patient had two different primary tumours.

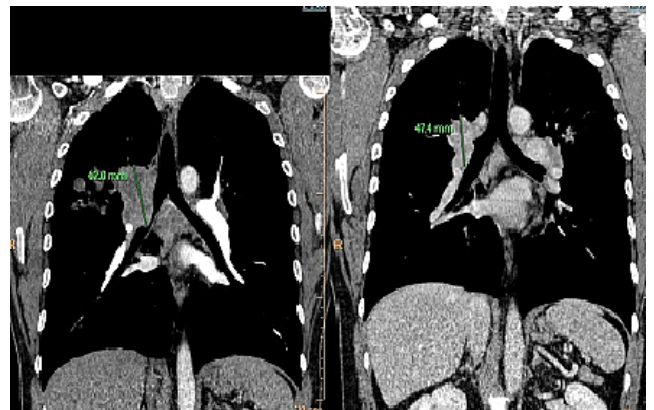

Figure 1: CT of the chest showing the tumour in the right upper lobe intruding the main bronchus. The CT scan was performed on the day of stenting

To release the patients symptoms a tracheobronchial uncovered stent (Ultraflex; Boston Scientific, Natick, MA) was placed in the right main bronchus, maintaining open airway passage; this procedure provided immediate relief for the patient. The stent had a length of 6 cm and a diameter of 1.4 cm. The right upper lobe bronchus was completely obstructed by the tumour and could not be stented, so passage of air was possible only via the airways to the right middle and lower lobes. The procedure was performed at the Department of Heart- and Lung Surgery at Aalborg University Hospital.

Running a fever and being in a poor general condition the patient was admitted to our department approximately two weeks later. An

abscess involving almost the entire right upper lobe was seen on CT images (Figure 2). Microbiology revealed *Staphylococcus aureus* and the patient was treated with antibiotics including tazobactam in combination with piperacillin 4 g x 3 I.V., metronidazole 500 mg x 3 P.O., and dicloxacillin 1 g x 4 I.V.

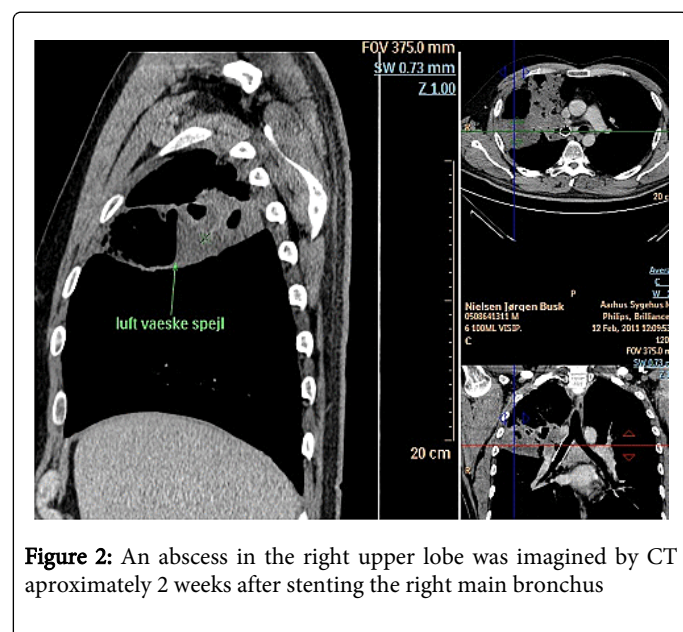


Figure 2: An abscess in the right upper lobe was imaged by CT approximately 2 weeks after stenting the right main bronchus

At this point, the patient had received 21 of 30 planned radiotherapy fractions and was given the remaining 9 fractions even though he had been diagnosed with a lung abscess. The condition worsened during and after radiotherapy, and the patient started lose weight and developed overwhelming fatigue.

After three weeks the stent was removed in an attempt to create drainage from the abscess. Spillage of pus was observed after the removal and unfortunately the condition of the patient changed dramatically just a few hours after removal. Acute respiratory distress syndrome (ARDS) was diagnosed in the patient and intensive care became necessary and the patient was placed on mechanical ventilation. Both lungs were infected and the abscess remained unchanged (Figure 3).

Despite two weeks of intensive antibiotic treatment the patient died from respiratory failure. The bronchoscopic airways manipulation which was necessary in order to remove the stent resulted in aspiration of purulent contents. This may have contributed to the outcome of the story of this patient. The fatal aspiration of purulent contents is a known complication of bronchoscopic manipulation of lung abscess [1].

ARDS is a life-threatening acute clinical syndrome with high mortality. Many different causes including cancer can be predisposing for developing ARDS. The diagnosis of ARDS depends on chest x-ray showing “white lungs” defining infection all over the lungs. Development of hypoxia and initially hypocapnia leads to ventilation and perfusion disturbances. Finally the pressure in a. pulmonalis is high and the vascular resistance in the lungs is increased dramatically [2].

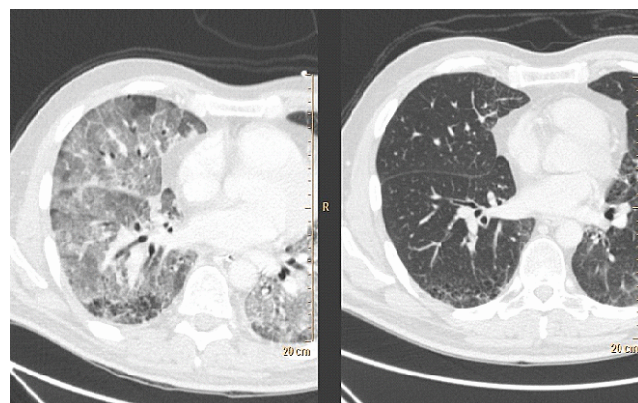


Figure 3: Both lungs were now infected and the patient dies from respiratory failure

Eighty per cent of patients with lung cancer are not suitable for curative surgical treatment [3] and central airway obstruction is found in 40-50% of patients diagnosed with advanced-stage lung cancer [4,5]. Endobronchial stents provide effective symptoms of obstruction relief. Stents can be safely placed with either flexible or rigid bronchoscopy; the latter at general anaesthetic [6]. The complication rate is very small [4] and was observed to be 0.06 complications per patient month in one large review of long-term complications of metallic stents in patients with either benign or malignant caused airway obstruction [7].

The overall incidence of infections in patients with malignant disease and stent is 16% and approximated mortality 76%. Cavitory pneumonia/lung abscess is only seen in 2% of patients [8].

Airway stent placement provides initial palliation to improve PS. Subsequently, this can allow adjuvant therapy such as chemotherapy and radiotherapy in selected patients [9].

The patient in this case report was probably already infected by the time of stent placement according to the findings on CT images (Figure 1). Whether the presence of an infection by the time of stenting has worsened the prognosis for the patient or the infection could have been maintained in a better way without airway stenting, is not possible to verify. The continuing radiotherapy to an infected field may also have provided complications which could have been avoided, even though Furukawa et al recommends that the attending physician should consider stent placement during the treatment period in order to alleviate the symptoms of the patient or improve quality of life [9].

References

1. Hammer DL, Aranda CP, Galati V, Adams FV (1978) Massive intrabronchial aspiration of contents of pulmonary abscess after fiberoptic bronchoscopy. *Chest* 74: 306-307.
2. Andrejaitiene J (2003) [Acute respiratory distress syndrome]. *Medicina (Kaunas)* 39: 1044-1056.
3. Asimakopoulos G, Beeson J, Evans J, Maiwand MO (2005) Cryosurgery for malignant endobronchial tumors: analysis of outcome. *Chest* 127: 2007-2014.
4. Luomanen RKJ, Watson WL (1968) Autopsy findings. In: Watson WL, ed. *Lung cancer: a study of five thousand Memorial Hospital cases*. St Louis, MO: CV Mosby Co.

-
5. Noppen M, Meysman M, D'Haese J, Schlessers M, Vincken W (1997) Interventional bronchoscopy: 5-year experience at the Academic Hospital of the Vrije Universiteit Brussel (AZ-VUB). *Acta Clin Belg* 52: 371-380.
 6. Ranu H, Madden BP (2009) Endobronchial stenting in the management of large airway pathology. *Postgrad Med J* 85: 682-687.
 7. Madden BP, Loke TK, Sheth AC (2006) Do expandable metallic airway stents have a role in the management of patients with benign tracheobronchial disease? *Ann Thorac Surg* 82: 274-278.
 8. Agrafiotis M, Siempos II, Falagas ME (2009) Infections related to airway stenting: a systematic review. *Respiration* 78: 69-74.
 9. Furukawa K, Ishida J, Yamaguchi G, Usuda J, Tsutsui H, et al. (2010) The role of airway stent placement in the management of tracheobronchial stenosis caused by inoperable advanced lung cancer. *Surg Today* 40: 315-320.