

Comparison between Corticosteroid, Platelet Rich Plasma (PRP) and Xylocaine Infiltration for Lateral Epicondylitis (Tennis Elbow): A Prospective Randomized Study

Vishnu Vardhan Reddy*, Vijay Chandru, Ishani Patel and Gopalakrishna SV

Department of Orthopaedics, JSS Hospital, Mysore, Karnataka, India

Abstract

Background: Platelet rich plasma and corticosteroid injection have both been suggested to treat chronic lateral epicondylitis. The aim of this study was to compare the safety and effectiveness of corticosteroid, PRP and xylocaine infiltration for lateral epicondylitis.

Materials and Methods: 150 patients with chronic lateral epicondylitis were randomly divided into three groups. Group A was treated with a single injection of 2 ml of corticosteroid mixed with 1 ml of xylocaine, Group B with 2 ml of PRP mixed with 1 ml of xylocaine and Group C with 3 ml of 2% xylocaine through peppering needle technique. Pain and functional improvements were assessed using visual analogue scale (VAS) and Nirschl's staging at 0,2,6,12,26 and 52 weeks.

Results: Baseline evaluation showed no difference between the three groups ($p>0.05$). Analysis at 2 weeks showed no difference in Nirschl staging but showed significant decrease in VAS score in favour of corticosteroid group. No statistically significant difference was noted between groups at 6 weeks ($p>0.05$). At 12 weeks VAS score was comparable but Nirschl stage was significantly low in corticosteroid group. Evaluation at 26 and 52 weeks demonstrated a statistically significant difference between groups favouring PRP group ($p<0.05$).

Conclusion: PRP, Corticosteroid and Xylocaine are safe and effective in treatment of lateral epicondylitis. Both steroid and xylocaine are effective on a short term period. However, on long term follow-up, PRP seems to be the more effective treatment with more persistent efficacy than corticosteroid and xylocaine in relieving pain.

Keywords: Lateral epicondylitis; Platelet rich plasma injection; Corticosteroid injection; Nirschl pain score; Xylocaine injection

Introduction

Lateral epicondylitis (tennis elbow) is one of the most frequently diagnosed musculoskeletal disorders in the upper extremity in a primary care setting. It has an incidence of 4-7 per 1000 per year in general practice, with a peak between the age groups of 35-54 years, with a mean age of approximately 42 years [1-3]. Over-use from many activities has been reported to be the cause of lateral epicondylitis. The patient usually presents with pain over the elbow region and on examination, tenderness over the lateral epicondyle is present. Histopathological reports have shown that lateral epicondylitis is not an inflammatory process but a degenerative condition termed 'tendinosis' [4-6]. There are various treatment methods for lateral epicondylitis both conservative as well as operative. Conservative management which includes activity modification, RICE (rest, ice, compression, elevation) and Non-steroidal anti-inflammatory drugs is usually the first line of treatment. Traditionally xylocaine has been used alone or in combination with corticosteroids to treat lateral epicondylitis. Most conservative methods such as local corticosteroid injection have focused on suppressing inflammatory process that does not actually exist. Relapse and recurrence is high after treatment with corticosteroids, probably due to permanent adverse changes within the tendon and due to overuse of the arm after injection, as a result of direct pain relief.

Recently, platelet rich plasma (PRP) has been promoted as an ideal biologic autologous blood derived product. PRP is defined as volume of the plasma fraction of autologous blood having a platelet concentration above baseline [6-8]. It can be exogenously applied to various tissues where, upon platelet activation, a release of high concentrations of platelet derived growth factors occurs [9,10]. These growth factors

trigger stem cell recruitment, increase local vascularity and directly stimulate the production of collagen by tendon sheath fibroblasts. Platelet rich plasma applications enhance wound healing, bone healing and also tendon healing.

This study was thus undertaken to compare the safety and effectiveness of corticosteroid, PRP and xylocaine infiltration for lateral epicondylitis.

Materials and Methods

All patients with clinical signs and symptoms of chronic lateral epicondylitis willing for the treatment and attending JSS Hospital, Mysore during July 2013-October 2015 were evaluated to enter this prospective randomized control study.

Inclusion criteria

Inclusion criteria for this study was: patients aged 18 years or greater of either sex with clinical diagnosis of lateral epicondylitis based on site of pain and pain elicited with active extension of wrist in pronation and elbow in extension.

***Corresponding author:** Vishnu Vardhan Reddy, Department of Orthopaedics, JSS Hospital, Mysore, Karnataka, India, Tel: 08212335555; E-mail: chinna9chintu@gmail.com

Received March 18, 2016; **Accepted** May 05, 2016; **Published** May 08, 2016

Citation: Reddy VV, Chandru V, Patel I, Gopalakrishna SV (2016) Comparison between Corticosteroid, Platelet Rich Plasma (PRP) and Xylocaine Infiltration for Lateral Epicondylitis (Tennis Elbow): A Prospective Randomized Study. J Trauma Treat 5: 304. doi:[10.4172/2167-1222.1000304](https://doi.org/10.4172/2167-1222.1000304)

Copyright: © 2016 Reddy VV, et al. This is an open-access article distributed under the terms of the Creative Commons Attribution License, which permits unrestricted use, distribution, and reproduction in any medium, provided the original author and source are credited.

Exclusion criteria

Patients excluded from this study were those with history of acute elbow trauma, elbow arthritis, patients requiring antiplatelet medication for the treatment of ischaemic heart disease, cerebrovascular accidents or other medical conditions, any previous elbow surgeries, other causes of elbow pain such as osteochondritis dissecans of capitellum, posterior interosseous nerve syndrome, cervical disc syndrome, synovitis of radiohumeral joint, cervical radiculopathy, fibromyalgia.

Ethical considerations

All patients gave written consent for inclusion in the study. The treatment process was explained to the patients and they were aware of his/her rights during the study. The written consent form was signed or fingerprinted by the patient. The institutional review board of JSS University approved the protocol of this study. The process of treatment did no harm to their health.

Randomization

A sealed envelope technique containing randomization coding system generated by the computer was used for randomization of patients.

Procedure

Group A-Corticosteroid group: Patients were infiltrated with 2 milliliters of local corticosteroid (Methyl prednisoloneacetate 80 mg) mixed with 1 milliliters of 2% xylocaine, at the lateral epicondyle by the technique mentioned below.

Group B-Platelet rich plasma group: Patients were infiltrated with 2 milliliters of freshly prepared PRP mixed with 1 milliliter of 2% xylocaine by the same technique.

Group C-Xylocaine group: Patients were infiltrated with 3 milliliters of 2% xylocaine at the lateral epicondyle by the same technique.

PRP preparation: The patient was placed in a comfortable and appropriate position that allows for sterile access to the site of injection. At first, 20 ml of blood was collected from the patient's contralateral upper extremity cubital vein under aseptic conditions into four vacutainers containing anticoagulant. These four vacutainers were subjected to a first spin in a centrifuge at a speed of 2500 RPM for 10 minutes. After the first spin 3 layers appeared. The deep layer consists of red blood cells, the middle layer contains platelets and leukocytes, and the top layer is made up of platelet-poor plasma. The top and middle layers were transferred to a fresh vacutainer. The plasma was then

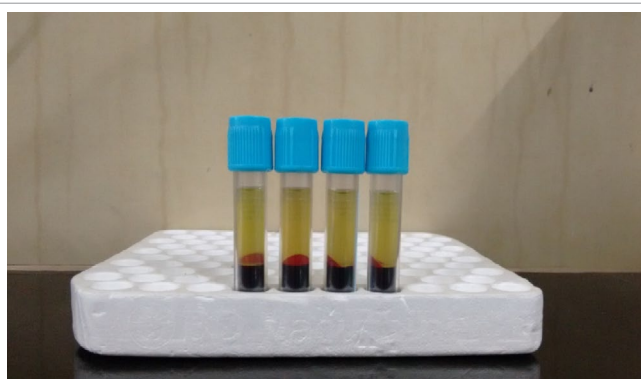


Figure 1: Plasma on the top after 1st spin.




Figure 2: Plasma at the bottom after 2nd spin.

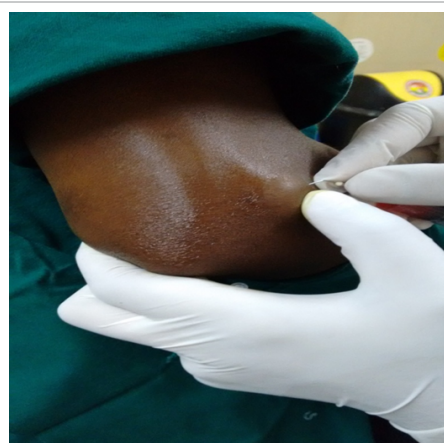


Figure 3: Injection technique.

subjected to a second spin at a speed of 3500 RPM for 15 minutes. The plasma at the bottom, which is rich in platelets was separated and used for infiltration (Figures 1 and 2).

Injection technique

The elbow is flexed to 90° with forearm in pronation. The injection site is painted and draped. Radial head is palpated while pronating and supinating the forearm. The needle (22 G) is introduced proximal to the radial head on lateral epicondyle at the point of maximum tenderness and in the vicinity (around the tendon of ECRB). Multiple pricks were made in the tendon (peppering technique) and contents of syringe were injected slowly. Patients were advised to give rest to the upper limb, avoid heavy activities for three days, after which no restriction on activity was advised (Figure 3).

Outcome evaluation

Outcome was measured using visual analogue scale (VAS) and 'Nirschl staging of lateral epicondylitis'.

Nirschl staging

Phase 1: Mild pain with exercise; resolves within 24 hours.

Phase 2: Pain after exercise; exceeds 48 hours.

Phase 3: Pain with exercise; does not alter activity.

Phase 4: Pain with exercise; alters activity.

Phase 5: Pain with heavy activities of daily living.

Phase 6: Pain with light activities of daily living; intermittent pain at rest.

Phase 7: Constant pain at rest; disrupts sleeps.

Statistical analysis

Inferential statistics was done by using chi-square test, ANOVA (Analysis of Variance) one way, ANOVA repeated measure, two ways ANOVA and paired t test. All analysis was done using SPSS software version 21.0. P<0.05 was considered as statistically significant.

Results

The study comprised of a total number of 157 patients. Clinical evaluation was done for all patients. Baseline VAS scores and Nirschl staging were recorded. In PRP group two patients were lost to follow up, one after 6 weeks and one after 12 weeks. One patient had persisting pain after 6 weeks; he opted for corticosteroid injection at 6th week follow up. In corticosteroid injection group, two patients lost to follow up after the 6th week. In xylocaine group, two patients were lost to follow up, one after 6 weeks and one after 26 weeks.

Out of the 150 participants, 82 were males and 68 were females. In PRP group, 28 were males and 22 were females. In steroid group, 24 were males and 26 were females. In xylocaine group 30 were males and 20 were females (p value=0.47). Thus, three of the groups were comparable in terms of number of males and females in each group.

Age group encountered in the study ranged from 27 years to 82 years, with a mean age of 44.39. Peak incidence at fourth decade of life was seen. The mean age of patients in PRP group was 42.6, steroid group was 44.18 and in xylocaine group was 46.4, (p value=0.1). Thus age of patients in three groups was comparable.

Baseline characteristics: A Comparison of baseline demographic and clinical data in three groups was done. Statistical analysis showed that the difference between three groups was not significant (Tables 1 and 2).

	Steroid	PRP	Xylocaine	P value
AGE (In Years)	44.18(8.63)	42.60 (11.18)	46.40 (7.32)	0.1(NS)
Sex (Male:Female)	24:26	28:22	30:20	0.47(NS)
Laterality (Right:Left)	37:13	41:9	39:11	0.7(NS)
Mean duration of symptoms (in weeks)	9.74 (21.50)	11.16 (15.99)	9.38 (10.13)	0.8(NS)
Mean VAS Score	5.4 (1.8)	5.88 (1.6)	5.28 (1.8)	0.2(NS)
Mean Nirschl Stage	4.9 (1.8)	5.28 (1.6)	4.86 (1.7)	0.4(NS)

(SD-standard deviation); NS-not significant

Table 1: Baseline clinical and demographic characteristics of each group.

Steroid Group (50 patients)								
Time	VAS				Nirschl Staging			
	Mean	SD	Median	p value	Mean	SD	Median	p value
0	5.44	1.8	6	<0.0001	4.92	1.81	5	<0.0001
2 weeks	4.42	1.4	5		3.96	1.4	4	
6 weeks	4.1	1.49	4		3.36	1.4	3.5	
12 weeks	4.16	1.17	4		3.22	1.43	3	
26 weeks	4.98	1.38	5		4.22	1.58	4	
52 weeks	4.32	1.15	4		3.66	1.26	3	

SD- Standard deviation; VAS- Visual Analog Scale

Table 2: Change of VAS and Nirschl score in the steroid group during follow up.

PRP (50 patients)								
Time	VAS				Nirschl Staging			
	Mean	SD	Median	p value	Mean	SD	Median	p value
0 weeks	5.88	1.64	6	<0.0001	5.28	1.6	6	<0.0001
2 weeks	5.6	1.5	5.5		4.46	1.28	4.5	
6 weeks	4.62	1.37	5		3.72	1.03	4	
12 weeks	4.1	1.25	4		3.24	1.06	3	
26 weeks	3.84	1.46	4.00		3.06	1.43	3.00	
52 weeks	3.46	0.97	3		2.7	1.27	2.5	

SD- Standard Deviation, VAS- Visual Analog Scale, PRP- Platelet Rich Plasma <0.0001, Significant, repeated measure ANOVA (Analysis of variance)

Table 3: Change of VAS and Nirschl Score in PRP group during follow up

Xylocaine (50 patients)								
Time	VAS				Nirschl Staging			
	Mean	SD	Median	p value	Mean	SD	Median	p value
0	5.28	1.81	5	<0.0001	4.86	1.75	5	<0.0001
2 weeks	4.5	1.61	4		4.08	1.44	4	
6 weeks	4.12	1.49	4		3.66	1.08	4	
12 weeks	4.28	1.43	4		3.94	1.06	4	
26 weeks	4.44	1.72	4		4.28	1.13	4	
52 weeks	4.2	1.36	4		3.88	0.85	4	

SD- Standard Deviation, VAS- Visual Analog Scale <0.0001, Significant, repeated measure ANOVA (Analysis of variance)

Table 4: Change of VAS and Nirschl score in xylocaine group during follow up

Corticosteroid group: The mean VAS score before injection was 5.44. Similarly the mean value of Nirschl stage before administration of steroid was 4.92. The mean values of VAS scores and Nirschl stages at different follow up visits are given in Table 2 respectively. The mean decrease observed in the VAS scores and Nirschl stage at the end of 52 weeks came out to be statistically significant (Table 3).

PRP Group: The baseline VAS score was 5.88. Similarly the mean value of Nirschl stage before administration of PRP was 5.28. The change in VAS scores and Nirschl stages at different follow up visits are given in Table 3 respectively. The mean decrease observed in the VAS scores and Nirschl stage at the end of 52 weeks came out to be statistically significant (Table 4).

Xylocaine Group: The pre injection mean VAS score and Nirschl stage were 5.28 and 4.86 respectively. The change in VAS scores at different follow up visits are given in Table 4. The mean values of Nirschl stages at different follow up visits are given in the table. The mean decrease observed in the VAS scores and Nirschl stage at the end of 52 weeks came out to be statistically significant.

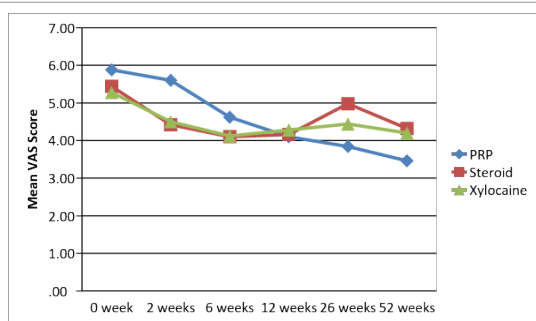
Analysis between three groups: After the initial analysis of three groups separately, comparisons were drawn. Pre injection mean VAS score and the mean value of Nirschl stage were comparable in the three groups.

The mean VAS scores in the three groups were plotted on a line diagram. Statistical comparison between the three groups (Table 5) revealed that at 2 weeks VAS score was significantly lower in steroid group. At 6 and 12 weeks there was no significant difference between groups. However at 26 and 52 weeks significant difference was noted between groups favouring PRP group over the others.

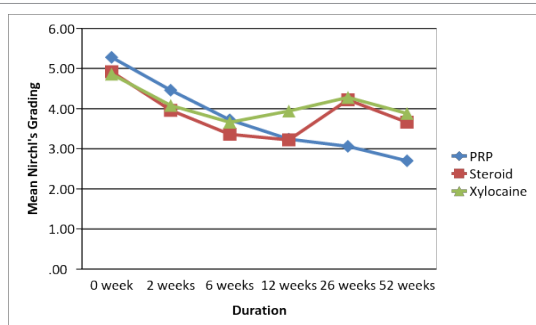
Similar to the above comparison, Nirschl staging was compared and plotted on a line diagram. At 2 and 6 weeks there was no significant difference noted between the groups. At 12 weeks the mean value of Nirschl staging was significantly lower in steroid group. However, similar to VAS scores, Nirschl staging was also significantly lower in PRP group at 26 and 52 weeks (Graphs 1 and 2) (Tables 5 and 6).

Discussion

Tennis elbow is a common problem encountered in orthopaedic practice. Majority of the treatment modalities used for its management lack scientific rationale [11]. A large percentage of cases (70-80%) report resolution of their symptoms within a year with or without treatment [12]. The most commonly recommended treatment is physiotherapy and bracing. Approximately 87% of the patients benefit from this combination of treatment methods [13]. The role of a local steroid is debatable because pathology is not inflammation at the lateral epicondyle. Treatment with corticosteroids has a high frequency of relapse and recurrence, probably because intratendinous injection may lead to permanent adverse changes within the structure of the tendon and because patients' tend to overuse the arm after injection as a result of direct pain relief [14].



Graph 1: Graph showing mean VAS score at different follow up visits in the three groups.



Graph 2: Graph showing mean Nirschl staging at different follow up visits in three groups.

	Groups									
	PRP			Steroid			Xylocaine			
	Mean	SD	Median	Mean	SD	Median	Mean	SD	Median	
0	5.88	1.64	6	5.44	1.8	6	5.28	1.81	5	0.2
2 weeks	5.6	1.5	5.5	4.42	1.4	5	4.5	1.61	4	<0.0001
6 weeks	4.62	1.37	5	4.1	1.49	4	4.12	1.49	4	0.1
12 weeks	4.1	1.25	4	4.16	1.17	4	4.28	1.43	4	0.7
26 weeks	3.84	1.46	4	4.98	1.38	5	4.44	1.72	4	0.001
52 weeks	3.46	0.97	3	4.32	1.15	4	4.2	1.36	4	0.001

SD- Standard Deviation, VAS- Visual Analog Scale One way ANOVA(Analysis of variance) Two way repeated measure ANOVA, p=0.9

Table 5: Difference in VAS score between the three groups during each visit

	Nirschl grading									
	PRP			Steroid			Xylocaine			
	Mean	SD	Median	Mean	SD	Median	Mean	SD	Median	
0	5.28	1.6	6	4.92	1.81	5	4.86	1.75	5	0.4
2 weeks	4.46	1.28	4.5	3.96	1.4	4	4.08	1.44	4	0.2
6 weeks	3.72	1.03	4	3.36	1.4	3.5	3.66	1.08	4	0.3
12 weeks	3.24	1.06	3	3.22	1.43	3	3.94	1.06	4	0.04
26 weeks	3.06	1.43	3	4.22	1.58	4	4.28	1.13	4	<0.0001
52 weeks	2.7	1.27	2.5	3.66	1.26	3	3.88	0.85	4	<0.0001
52 weeks	3.46	0.97	3	4.32	1.15	4	4.2	1.36	4	0.001
SD- Standard Deviation One way ANOVA (Analysis of variance) 0.3, not SIGNIFICANT two way repeated measure ANOVA										

SD- Standard Deviation One way ANOVA (Analysis of variance) 0.3, not SIGNIFICANT, two way repeated measure ANOVA

Table 6: Change in mean Nirschl staging between different groups at different follow up visits.

Recently, an injection of autologous platelet rich plasma has been reported to be effective for both intermediate and long term outcomes for the treatment of lateral epicondylitis. The exact mechanisms by which PRP initiates cellular and tissue changes are presently being investigated [15]. There is enough laboratory evidence of PRP effect on tendon healing. It has been considered in some studies that platelet growth factors could be effective in the cartilage healing process in knee osteoarthritis [16]. The proposed mechanism of action is the elicitation of a healing response in the damaged tendons by growth factors. These growth factors trigger stem cell recruitment, increase local vascularity, and directly stimulate the production of collagen by tendon sheath fibroblasts. Increased production of endogenous growth factors has been found in human tendons treated with PRP [17].

According to the results of our study, local injection of PRP, steroid and xylocaine into lateral epicondyle led to significant improvement in VAS and Nirschl staging at every follow up. There was no statistically significant difference between groups regarding VAS at 6 and 12 weeks. Significant difference of VAS score between groups was found at 2 weeks favouring steroid group and at 26, 52 weeks favouring PRP group.

In our study comparison between three groups, showed that Nirschl staging was similar at 2,6 weeks. At 12 weeks Nirschl staging in steroid group was significantly lower. Significant difference of Nirschl staging between groups was found at 26, 52 weeks favouring PRP group.

In a study the efficacy of PRP and corticosteroid for tennis elbow was evaluated in 100 patients [18]. Regarding VAS scores significant difference was noted at 4 weeks supporting steroid group and at 26 and 52 weeks supporting PRP group which is in agreement with the result of our study. Mishra and his colleagues evaluated treatment of chronic severe elbow tendinosis with PRP. Eight weeks after the treatment, patients who had received PRP, noted 60% improvement in their VAS scores versus 16% improvement in control patients [19].

In a study PRP was compared to steroid in 30 patients of tennis elbow. Both VAS and DASH scores improved significantly in both groups after six weeks of treatment. While no significant differences were observed between both groups at six weeks which is in accordance to our study [20].

In a study of autologous blood was compared to steroid in treating 50 tennis elbow patients. Evaluation at 6 weeks demonstrated a significant decrease in pain levels and Nirschl staging in blood group

[21]. The evaluated treatment of lateral epicondylitis patients with PRP and autologous whole blood. At 4 weeks no statistically significant difference was noted between groups regarding VAS and Mayo scores. While significant difference was noted at 8 weeks showing improvement in PRP group [22].

The 3 studies in which PRP was compared to some other modality of treatment for lateral epicondylitis. Based on the best evidence synthesis, they concluded that PRP is not efficacious in chronic lateral epicondylar tendinopathy. The method of PRP preparations could be the possible source of different results obtained by these studies. The differences in sample size and duration of illness also might have had an effect on the outcome. The mechanism of action of steroid and xylocaine remains obscure [23].

The beneficial effects of injection result from the bleeding caused by forcing fluid through tissue planes at high pressures [24].

In a study the steroid, autologous blood and saline injection all afforded the same benefit in cases of tennis elbow [21]. This indirectly points out that these reported outcomes may also be due to placebo effect of injection itself or a reflection of concurrent resolution of a self-limited disease.

Limitations

In our study we used only subjective modes for evaluation of pain in the form of VAS and Nirschl staging. The inclusion of an objective method of evaluation in the form of hand grip strength would have increased the strength of study. The concentration of platelets in PRP was not checked and standardized. We used free hand technique to give injection at lateral epicondyle. An ultrasound guided technique would have helped us in giving the injection precisely at the damaged tendon site. Since we enrolled only those patients who were previously untreated, further studies are needed to detect any difference in efficacy of PRP injection in cases of patients earlier treated with other modalities.

Conclusion

PRP, Corticosteroid and Xylocaine are safe and effective in the treatment of lateral epicondylitis. Both steroid and xylocaine are effective on a short term basis. However, at 26 and 52 weeks of follow up, PRP seems to be more effective treatment with more persistent efficacy than corticosteroid and xylocaine in relieving pain. We encourage more randomized clinical trials on this topic emphasizing on the best technique of injection using ultrasound, number and frequency of injections, and standardization of concentration of platelets in PRP. Additionally, including a control group who receive no therapy may allow the investigation of the real efficacy of PRP compared to no treatment.

References

- Hamilton PG (1986) The prevalence of humeral epicondylitis: a survey in general practice. *J R Coll Gen Pract* 36: 464-465.
- Verhaar JAN. Tennis elbow (Thesis). Maastricht: Maastricht University Press.
- Gruchow HW, Pelletier D (1979) An epidemiologic study of tennis elbow: Incidence, recurrence, and effectiveness of prevention strategies. *Am J Sports Med* 7: 234-238.
- Price R, Sinclair H, Heinrich I, Gibson T (1991) Local injection treatment of tennis elbow--hydrocortisone, triamcinolone and lignocaine compared. *Br J Rheumatol* 30: 39-44.
- Barry S. Kraushaar, Emerson, Robert P. Nirschl (1999) Current concepts review Tendinosis of elbow, clinical features and findings of histological, 63 immunohistochemical & electro microscopic studies. *J Bone Joint Surg*.
- Molloy T, Wang Y, Murrell G (2003) "The roles of growth factors in tendon and ligament healing," *Sports Med* 33: 381-394.
- Connell DA, Ali KE, Ahmad M, Lambert S, Corbett S, et al. (2006) Ultrasound guided autologous blood injection for tennis elbow. *Skeletal Radiol* 35: 371-377.
- Iwasaki M, Nakahara H, Nakata K, Nakase T, Kimura T, et al. (1995) Regulation of proliferation and osteochondrogenic differentiation of periosteum derived cells by transforming growth factor-B and basic fibroblast growth factor. *J Bone Joint Surg Am* 77: 543-554.
- Nirschl RF, Sobel J. Conservative treatment of tennis elbow. *Physician Sport Med* 64.
- Baily RA, Brock BH (1957) Hydrocortisone in tennis elbow. A controlled series. *Pro R Soc Med* 50: 389-390.
- Labelle H, Guibert R, Joncas J, Newman N, Fallaha M, et al. (1992) Lack of scientific evidence for the treatment of lateral epicondylitis of the elbow: An attempted meta-analysis. *J Bone Joint Surg Br* 74: 646-651.
- Tonks JH, Pai SK, Murali SR (2007) Steroid injection therapy is the best conservative treatment for lateral epicondylitis: a prospective randomised controlled trial. *Int J Clin Pract* 61: 240-246.
- Struijs PA, Kerkhoffs GM, Assendelft WJ, Van Dijk CN (2004) Conservative treatment of lateral epicondylitis: brace versus physical therapy or a 70 combination of both- a randomized clinical trial. *Am J Sports Med* 32: 462-469.
- Smidt N, Windt van der DAWM, Assendelft WJJ, Devillé W, Korthals-de Bos I, et al. (2002) Corticosteroid injections, physiotherapy or a wait-and-see policy for lateral epicondylitis: a randomised controlled trial. *Lancet* 359: 657-662.
- Kaux JF, Crielaard JM (2013) Platelet-rich plasma application in the management of chronic tendinopathies. *Acta Orthopaedica Belg* 79: 10-15.
- Raeissadat SA, Rayegani SM, Babaee M, Ghorbani E (2013) The effect of platelet-rich plasma on pain, function, and quality of life of patients with knee osteoarthritis. *Pain Research and Treatment* 7: 165967-165970.
- Dhillon RS, Schwarz EM, Maloney MD (2012) Platelet rich plasma therapy- future or trend? *Arthritis Res Ther* 14: 219.
- Gosens T, Peerbooms JC, van Laar W, den Ouden BL (2011) Ongoing positive effect of platelet-rich plasma versus corticosteroid injection in lateral epicondylitis: a double-blind randomized controlled trial with 2-year follow-up. *Am J Sports Med* 39: 1200-1208.
- Mishra A, Pavelko T (2006) Treatment of chronic elbow tendinosis with buffered platelet-rich plasma. *Am J Sports Med* 34: 1774-1778.
- Omar AS, Ibrahim ME, Ahmed AS, Said M (2012) Local injection of autologous platelet rich plasma and corticosteroid in treatment of lateral epicondylitis and plantar fasciitis : Randomized clinical trial. *The Egyptian Rheumatologist* 34: 43-49.
- Jindal N, Gaury Y, Banshiwal RC, Ravinder Lamoria, Vikas Bachhal (2013) Comparison of short term results of single injection of autologous blood and steroid injection in tennis elbow: a prospective study. *J Orthop Surg Res* 8: 10.
- Raeissadat SA, Sedighipour L, Rayegani SM, Bahrami MH, Bayat M (2014) Effect of Platelet-Rich Plasma (PRP) versus Autologous Whole Blood on Pain and Function Improvement in Tennis Elbow: A Randomized Clinical Trial. *Pain Research and Treatment* 8: 191525-191533.
- de Vos R-J, Windt J, Weir A (2014) Strong evidence against platelet-rich plasma injections for chronic lateral epicondylar tendinopathy: a systemic review. *Br. J Sports Med* 48: 952-956.
- Balasubramaniam P, Prathap K (1972) The effect of injection of hydrocortisone into rabbit calcaneal tendons. *JBJS* 54: 729-734.