

Gross Pathology, Biochemistry and Histopathology of Selected Organs of Camels Suffering from Suspected Monensin Toxicosis in Australia

Al Jassim RAM^{1*}, Shahsavari A¹, Owen H¹ and Khamas W²

¹The University of Queensland, Gatton, St Lucia QLD-4072, Queensland, Australia

²Western University of Health Sciences, 309 E 2nd, St. Pomona, CA 91766, United States of America

*Corresponding author: Al Jassim RAM, The University of Queensland, Gatton, St Lucia QLD-4072, Queensland, Australia, Tel: +61754601521; E-mail: r.aljassim@uq.edu.au

Rec date: Feb 12, 2016; Acc date: Apr 06, 2016; Pub date: Apr 08, 2016

Copyright: © 2016 Al Jassim RAM, et al. This is an open-access article distributed under the terms of the Creative Commons Attribution License, which permits unrestricted use, distribution, and reproduction in any medium, provided the original author and source are credited.

Abstract

The rumen modifier monensin is widely used in Australia cattle production systems. In addition to its anti-coccidial action monensin improves energy efficiency and nitrogen metabolism in rumen bacteria, and reduces the incidence of metabolic disorders such as acidosis and bloat. While monensin is considered safe for cattle, swine and poultry, it is extremely toxic to horses and incidents of toxicity have also been reported in camels.

In this study, we are reporting for the first time monensin toxicosis in a camel herd in South-West Queensland, Australia (~267 km west of Brisbane). The camels were fed a cattle breeder supplements containing 250 mg/kg monensin, formulated to ensure effective concentrations if the supplement is consumed by breeder cattle at levels of 200-500 g/head/d.

Blood samples were collected from 13 camels with clinical signs of monensin toxicosis and 12 healthy camels that had no exposure to monensin. Post-mortem examinations were carried out on two camels immediately after death, these animals had marked ascites. Monensin toxicoses resulted in marked decreases in albumin and increases in ALP, LDH and CPK when compared to physiologically normal healthy camels. Other parameters in the blood profile remain within normal limits.

Minor to no histopathological changes were observed in the two necropsied camels however death due to rapidly developing congestive heart failure is suspected. Skeletal muscle was not examined histologically. However, the biochemical changes could be consistent with muscle necrosis.

Keywords: Camels; Monensin toxicosis; Blood profile; Histopathology

Introduction

The rumen modifier monensin is a polyether ionophore antibiotic produced by the soil bacterium *Streptomyces cinnamonensis* [1]. It is widely used in Australian and US cattle production systems [2]. In addition to its anti-coccidial action, monensin improves energy efficiency and nitrogen metabolism in rumen bacteria, and reduces the incidence of metabolic disorders such as acidosis and bloat [3]. Monensin induces pH change within the cell, which can lead to a reduction in the secretion and/or transport of the chemicals important for the proper functioning of the cell. Monensin also affects the processes involved in formation of external structures on the cell surface and their growth by reducing the secretion of necessary substances [1]. It has been demonstrated that the cellular effects of monensin depend on the body size subjected to its action, the route of administration, and the dose of this antibiotic [1].

The mode of action of monensin is well established [4]. It forms a complex with extracellular Na⁺, dissolves into the bilayer membrane of bacteria and protozoa causing total intracellular Na⁺ to increase and total K⁺ to decrease. In doing so, it disrupts the Na⁺-K⁺ pumps and kills bacteria and protozoa. While monensin is considered safe for

cattle, swine and poultry, it is extremely toxic to horses [5] and incidents of toxicity have also been reported in several animal species in Egyptian camels [6]; in a group of bulls [7]; in two sheep flocks [8]; in a dairy herd [9] and an ostrich [10]. The blood profiles and histopathology in a camel herd, following suspected monensin toxicosis will be presented in this study.

In conclusion, the camel appears not to be in the same category of intermediate sensitivity like the cattle and therefore feeding them cattle ration supplemented with monensin is likely to result in morbidity or mortality.

Materials and Methods

A group of Arabian camels (*Camelus dromedarius*) ranging in age from one to eight years were co-grazed with cattle in a paddock with native grass and different types of pine and eucalyptus trees and shrubs. They had access to varying levels of monensin for a period of approximately 4 weeks due to receiving a cattle breeder supplement containing the ionophore antibiotic feed additive monensin (250 mg/kg). Thirteen camels out of a small herd of 40 camels showed clinical signs of monensin toxicity of variable severity. Blood samples were collected from these camels for blood profiling. Deaths of four camels were reported and two of these camels were necropsied on site immediately after their sudden death. Blood samples were also

collected from twelve healthy camels that had no exposure to monensin and used as controls. Sera were separated by centrifugation and biochemical analysis was performed using an Olympus blood analyzer (Olympus Life and Material Science Europa GmbH, Hamburg, Germany). Tissues were collected during the post mortem for histological examination. Specimens (forestomach, colon, liver, heart and spleen) were preserved in 10% neutral buffered formalin solution, embedded in paraffin, sectioned at 5 μ m and routinely stained with haematoxylin and eosin (H&E). Finally, the stained sections were examined under a light microscope for further evaluation and histological studies.

Results

Clinical observation

Toxicity signs demonstrated by several camels ranged from depression and muscular weakness to inability to stand. Among the four dead, a 13 month old camel was presented with a history of “not doing well”, being recumbent and not able to get up and having cyanotic mucus membrane. This animal died with torticollis (Figure 1). Post mortem and histological observations from the two dead camels are as follows: several litres of clear peritoneal fluid were present in the abdominal cavity (Figure 2). Furthermore, fluid was found to be in large quantity within the omentum/mesentery and inside the pericardial sac while the heart was found to be within normal shape (Figures 3 and 4).




Figure 1: Torticollis, irreversible position of the neck before death of 13 month old camel.

Histopathology findings

Myocardial necrosis, a feature of ionophore toxicity in other species was not noted in the sections examined. Microscopically, the only change observed was occasional nuclear rowing in the cardiomyocytes. No oedema or alveolar macrophages containing hemosiderin that might suggest congestive heart failure were noted in the sections of the lung examined. Moderate to severe oedema was detected in the submucosa of the forestomaches. Oedema in the colon was transmural. Within the colonic lamina propria, there was an equivocal increase in lymphocytes and plasma cells and multifocal, small, dense aggregates

of eosinophils. No changes of significance were noted in other tissues. Skeletal muscle was not collected.



Figure 2: Severe oedema in a camel exposed to four-week monensin toxicity with large amount of clear peritoneal fluid inside the abdominal cavity.

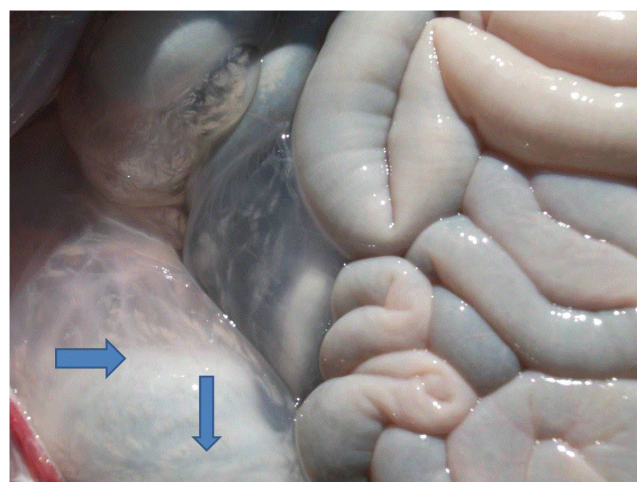


Figure 3: Peritoneal fluid below the omentum of 13 month camel (Arrows).

Blood chemistry profile

Blood profile showed an increase in alkaline phosphates (ALP), Lactate dehydrogenase (LDH) and creatine phosphokinase (CPK) when compared to physiologically normal healthy camels (Table 1) and reference ranges were reported in one study [11]. In comparison to the normal camels and published reference ranges, the average values from the exposed camels demonstrated marked hypoalbuminaemia ($P<0.0001$), associated hypocalcaemia ($P<0.001$) and hyperphosphataemia ($P<0.01$) were detected but other parameters (Na, Cl, Anion Gap, Cholesterol, Creatinine, gamma-glutamyl transferase (GGT), Globulin, HCO_3 and Urea) in the blood profile remained unchanged ($P>0.05$). Camels exposed to monensin had a tendency

toward higher levels of ALP (147.4 vs 93.8) but the statistical difference was not highly significant ($P>0.05$).

Test	Monensin Toxicity (n=13, exposed camels)		Normal Range (n=12, non-exposed domesticated camels)		SI Unit	P value
	(Mean \pm SE)	Range	(Mean \pm SE)	Range		
Sodium	146.3 ^a \pm 1.3	134-154	155.5 ^b \pm 0.38	154-158	mmol/L	0.000
Na/K ratio	25.4 ^a \pm 0.9	17.4-29.0	31.56 ^a \pm 0.36	26.3-30.4		
Potassium	5.9 ^a \pm 0.2	5.1-7.7	4.93 ^a \pm 0.05	4.7-5.2	mmol/L	0.001
Chloride	104.5 ^a \pm 7.4	17-119	119.5 ^a \pm 0.42	117-122	mmol/L	0.065
Bicarbonate	24.8 ^a \pm 1.0	18-33	22.17 ^a \pm 0.85	16-25	mmol/L	0.060
Ca/P ratio	0.74 ^a \pm 0.1	0.32-1.03	1.18 ^a \pm 0.03	1.25-1.15		
Calcium	1.81 ^a \pm 0.1	1.44 -2.59	2.17 ^b \pm 0.02	2.09-2.27	mmol/L	0.000
Anion Gap	22.85 ^a \pm 7.5	11-111.4	18.77 ^a \pm 1.12	25.7-16.2	mEq/L	0.608
Magnesium	1.0 ^a \pm 0.03	0.78-1.2	0.86 ^a \pm 0.01	0.79-0.91	mmol/L	0.008
Phosphorus	2.67 ^a \pm 0.2	1.75-4.54	1.85 ^b \pm 0.03	1.67-1.98	mmol/L	0.003
AST (Alanine transaminase)	202.5 ^a \pm 45.1	110-604	97.00 ^b \pm 3.37	82-112	U/l@37°C	0.035
ALP (Alkaline Phosphatase)	147.4 ^a \pm 41.7	54-605	93.83 ^b \pm 5.76	65-122	U/l@37°C	0.234
LDH (GLDH) (Glutamate dehydrogenase)	891.2 ^a \pm 120.1	496-1981	5.32 ^b \pm 0.40	3.2-7.2	U/l@37°C	0.000
CPK (Creatine phosphokinase)	293.0 ^a \pm 49.7	130-789	143.3 ^b \pm 17.02	83-268	U/l@37°C	0.010
GGT (Gama glutamyl transferase)	18.5 ^a \pm 6.0	8-90	12.43 ^a \pm 0.81	8 - 16	U/l@37°C	0.343
Protein	48.2 ^a \pm 2.5	25-61	59.0 ^a \pm 1.11	54-64	g/L	0.001
Albumin	17.3 ^a \pm 1.9	6-34	29.83 ^b \pm 0.76	26-34	g/L	0.000
Globulin	30.8 ^a \pm 1.5	19-40	29.26 ^a \pm 0.73	24.5-32.4	g/L	0.369
A/G Albumin/Globulin	0.58 ^a \pm 0.1	0.32-1.48	1.03 ^a \pm 0.04	1.06-1.05		0.000
Urea	4.18 ^a \pm 0.5	2.5-9.5	3.59 ^a \pm 0.19	2.5-4.3	mmol/L	0.286
Creatinine	102.8 ^a \pm 7.4	81-171	110.4 ^a \pm 5.51	88-135	μ mol/L	0.424
Cholesterol	0.88 ^a \pm 0.3	0.2-3.9	0.84 ^a \pm 0.07	0.5-1.2	mmol/L	0.902
Triglycerides	0.34 ^a \pm 0.05	0.05-0.6	0.5 ^a \pm 0.0	0.5-0.5	mmol/L	0.005
Total Bilirubin	2.17 ^a \pm 0.1	1.2-3.1	2.93 ^a \pm 0.07	2.5-3.3	μ mol/L	0.000
Glucose	5.49 ^a \pm 0.5	0.6-9.8	6.94 ^a \pm 0.29	5.8 -8.3	mmol/L	0.030

Table 1: Blood chemistry profile of camels suspected with monensin toxicity (n=13) compared to normal healthy camels (n=12). ^{a,b}Different superscripts denote significant statistical difference between groups while identical superscripts denote no statistical difference.

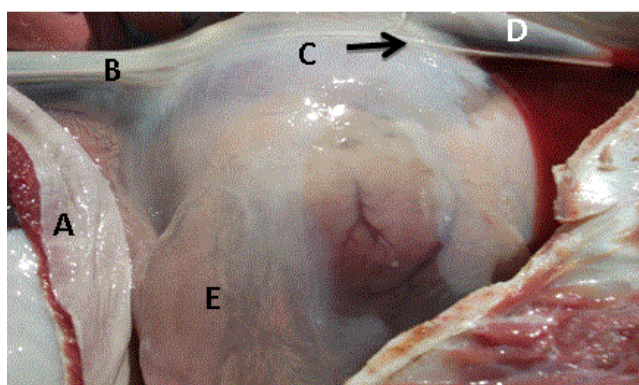


Figure 4: Increase pericardial fluid in 13 month old camel. Diaphragm (A); caudal vena cava (B); phrenic nerve (C); cranial vena cava (D); pericardial fluid (E).

Discussion

Food mixing errors have been documented in the literature in diverse animal species. The suspected camel herd monensin toxicity reported in this article was due to this kind of error where cattle feed with monensin additives were offered to the camels without taking into consideration the camel's unknown sensitivity to this ionophore compound. LD₅₀ of monensin was reported to be 1.4 mg/kg for horses [12] and 26.4 mg/kg in goats [13] while in broiler chickens; it was 214 mg/kg [14]. The most sensitive animal species was horses [1,12]. The toxicity of monensin for cattle and other species is well documented and is known to be dose dependent [15-18]. Unfortunately, no such data is available in the literature for camels.

No clear indication of extensive myocardial necrosis, a common feature of acute ionophore toxicity was observed or of myocardial fibre atrophy, indispersed with areas of myocardial hypertrophy and fibrosis which are features that have been described in cases of chronic ionophore toxicity in other species [17-18]. The only cardiac change observed was nuclear rowing which is an indication of early degeneration and regeneration initiation as reported by Mollenhauer et al. [19] in a Holstein heifer. The heart of this animal showed rare myocytes, characterized by rowing of nuclei and suggestive of attempted myofiber regeneration, with evidence of chronic yew toxicity in cattle. Some cases of chronic ionophore toxicity produce very localized or subtle cardiac lesions which may not be identified on limited sectioning of the heart. The severe ascites and visceral oedema could also be consistent with right sided congestive heart failure. Although the hypoalbuminaemia noted in the exposed animals may have been the cause of the ascites, it is possible that this hypoalbuminaemia was the result of rapidly developing congestive heart failure. This has been shown to occur in dogs and turkeys as a result of blood volume expansion, inanition and possibly loss of protein into the ascites fluid. An alternative explanation for the hypoalbuminaemia was not discovered, there was no histological or biochemical indication of extensive liver disease and protein-loss through the gut or kidney would be unlikely in multiple animals. A nutritional cause was also considered less likely as albumin concentrations in the control animals were substantially higher (29.83 vs 17.3, $P < 0.0001$).

It is also possible that monensin toxicity in camels results in skeletal muscle necrosis while cardiac muscle cells show no clear changes of necrosis due to selective effect [20]. Serum CK, GLDH and AST activities were increased ($P < 0.05$ and $P < 0.0001$), a finding that could be consistent with skeletal muscle necrosis. Serum potassium concentration was also higher (5.85 vs 4.93, $P < 0.001$) above normal. Myoglobinuria was not noted. Unfortunately skeletal muscle samples were not collected for histopathological examination.

Luckily, regardless of the exposure of meat animals to ionophores in feed, residues in the meat milk and its byproducts will have no potential effect on humans consuming these products [21].

In conclusion, the clinical signs associated with monensin toxicity in different animal species vary according to the dose and duration of exposure. In this case, no diarrhea was noted and histological evidence of extensive muscle damage was lacking. Although no histopathological changes were observed in the cardiac muscles, cardiac damage can sometimes be localized and subtle and the severe ascites could be consistent with congestive heart failure.

From our observation, the camel is not in the same category of intermediate sensitivity like the cattle and therefore feeding them cattle ration supplemented with monensin is likely to result in mortality. Further observations of other possible cases of monensin toxicity or intoxication to clarify the rest of the unexplained changes in one-humped camels are very much needed if other cases arise.

References

- Lowicki D, Huczynski A (2013) Structure and Antimicrobial Properties of Monensin A and Its Derivatives: Summary of the Achievements. *BioMed Research International*, pp: 1-14.
- Butaye P, Devriese LA, Haesebrouck F (2003) Antimicrobial growth promoters used in animal feed: effects of less well known antibiotics on gram-positive bacteria. *Clin Microbiol Rev* 16: 175-188.
- Lean IJ, Rabiee AR, Golder HM, Lloyd J (2011) Analysis of the potential to manipulate the rumen of northern beef cattle to improve performance. *Meat & Livestock Australia*.
- Schelling GT (1984) Monensin mode of action in the rumen. *J Anim Sci* 58: 1518-1527.
- Roder JD (2011) Ionophore toxicity and tolerance. *Vet Clin North Am Food Anim Pract* 27: 305-314.
- Mousa HM, Elsheikh HA (1992) Monensin poisoning in dromedary camels. *Dtsch Tierarztl Wochenschr* 99: 464.
- Janzen ED, Rodostits OM, Orr JP (1981) Possible monensin poisoning in a group of bulls. *Can Vet J* 22: 92-94.
- Jones A (2001) Monensin toxicosis in 2 sheep flocks. *Can Vet J* 42: 135-136.
- Gonzalez M, Barkema HW, Keefe GP (2005) Monensin toxicosis in a dairy herd. *Can Vet J* 46: 910-912.
- Dedoussi A, Roubies N, Tserveni-Goussi A (2007) Monensin toxicity in ostriches on a farm in northern Greece. *Vet Rec* 161: 628-629.
- Bogin E (2000) Clinical pathology of camelids: present and future. *Revue Méd Vét* 151: 563-568.
- Matsuoka T, Novilla MN, Thomson TD, Donoho AL (1996) Review of monensin toxicosis in horses. *JEVS* 16: 8-15.
- Deljou M, Aslani MR, Mohri M, Movassaghi AR, Heidarpour M (2014) Clinical, laboratory and pathological findings in sub-acute monensin intoxication in goats. *Vet Res Forum* 5: 161-167.
- Sandercok DA, Mitchell MA (2004) The role of sodium ions in the pathogenesis of skeletal muscle damage in broiler chickens. *Poult Sci* 83: 701-706.

-
15. Potter EL, VanDuyn RL, Cooley CO (1984) Monensin toxicity in cattle. J Anim Sci 58: 1499-1511.
 16. Van Vleet JF, Ferrans VJ (1983) Ultrastructural myocardial alterations in monensin toxicosis of cattle. Am J Vet Res 44: 1629-1636.
 17. Bastianello SS, McGregor HL, Penrith ML, Fourie N (1996) A chronic cardiomyopathy in feedlot cattle attributed to toxic levels of salinomycin in the feed. J S Afr Vet Assoc 67: 38-41.
 18. Peek SF, Marques FD, Morgan J, Steinberg H, Zoromski DW, et al. (2004) Atypical acute monensin toxicosis and delayed cardiomyopathy in belgian draft horses. J Vet Intern Med 18: 761-764.
 19. Mollenhauer HH, Morre DJ, Rowe LD (1990) Alteration of intracellular traffic by monensin; mechanism, specificity and relationship to toxicity. Biochimica et Biophysica Acta 1031: 225-246.
 20. Beasley V (1990) Organic compounds that affect the heart. In: Beasley V (Ed), Veterinary Toxicology, Ithaca, USA. Int Vet Information, pp: 618-620.
 21. Novallis MN (2004) Expert report on the safety file for monensin sodium. Submitted to the European Medicines Agency CVM by Elanco Animal Health Division of Eli Lilly and company Indianapolis, IN, USA.