

Mesonephric Carcinoma of the Ovary: A Report of Two Cases

Philippe Moerman*, Eveline Lurquin and Ignace Vergote

Department of Pathology and Gynecologic Oncology and Leuven Cancer Institute (I.V.), University Hospital Gasthuisberg, Catholic University of Leuven, Leuven, Belgium

*Corresponding author: Philippe Moerman, Department of Pathology, University Hospital Gasthuisberg, Herestraat 49, B-3000 Leuven, Belgium, Tel: +32 (0)16 336627; Fax: +32 (0)16 336640; E-mail: philippe.moerman@uzleuven.be

Rec date: Feb 09, 2015, Acc date: Mar 12, 2015, Pub date: Mar 14, 2015

Copyright: © 2015 Moerman P, et al. This is an open-access article distributed under the terms of the Creative Commons Attribution License, which permits unrestricted use, distribution, and reproduction in any medium, provided the original author and source are credited.

Abstract

Mesonephric carcinomas of the female genital tract are rare tumors, mainly occurring in the cervix and exceptionally in the uterine corpus. There seems to be a paradigm that the only mesonephric neoplasms arising from the upper zone of the Wolffian system are FATWOs. Indeed, no cases of mesonephric carcinoma of the ovary have been reported in the recent literature. Herein, we describe two cases of ovarian carcinoma with histologic features consistent with mesonephric adenocarcinoma. In both cases, the initial diagnosis of well-differentiated endometrioid adenocarcinoma was withdrawn because of other coexistent growth patterns, and the presence of admixed mesonephric-type structures. The mesonephric identity of the tumors was supported immunohistochemically, in particular by their uniform negativity for ER and PR, and strong reactivity for CD10.

Keywords: Ovary; Mesonephric carcinoma; Wolffian duct remnants; CD10

Introduction

Mesonephric tumors are rare neoplasms of the female genital tract, derived from embryonic remnants of the Wolffian system [1]. In the female, two distinct zones of the Wolffian system are recognized, an upper or proximal and a lower or distal zone. The proximal zone comprises the rete ovarii, epoöphoron and paroöphoron; these are remnants of mesonephric tubules in the ovarian hilus, mesovarium and broad ligament. The distal zone includes Gartner's ducts, represented by scattered remnants of the mesonephric ducts, located deeply in the lateral walls of the uterine corpus, cervix and upper vagina.

Several types of mesonephric tumors have been described in the female genital tract: adenomas and cystadenofibromas of the rete ovarii, female adnexal tumors of Wolffian origin (FATWOs), and mesonephric carcinomas [2-5]. FATWOs almost exclusively occur in the upper zone of the Wolffian system, predominantly the broad ligament [2,6]. Only two cases have been reported in the lower zone, in a paravaginal location [7,8]. A reversed pattern of incidence seems to be the case for mesonephric carcinomas. Approximately 50 cases have been described in the cervix or vagina [9-11] but only very few cases in the uterine corpus, including one by our group [12-14]. There are virtually no previous reports of mesonephric carcinoma of the ovary in the English literature. However, this "missing link" is not in keeping with the presence of mesonephric remnants in the ovarian hilus. Importantly, the issue should not be confused by reports of ovarian mesonephric carcinoma or "mesonephroid tumors" in the older literature. Whilst not disputing that most of these tumors are in fact clear cell carcinomas of Müllerian origin or yolk sac tumors of germ cell origin, it is conceivable that at least some of them are true mesonephric carcinomas.

Case Reports

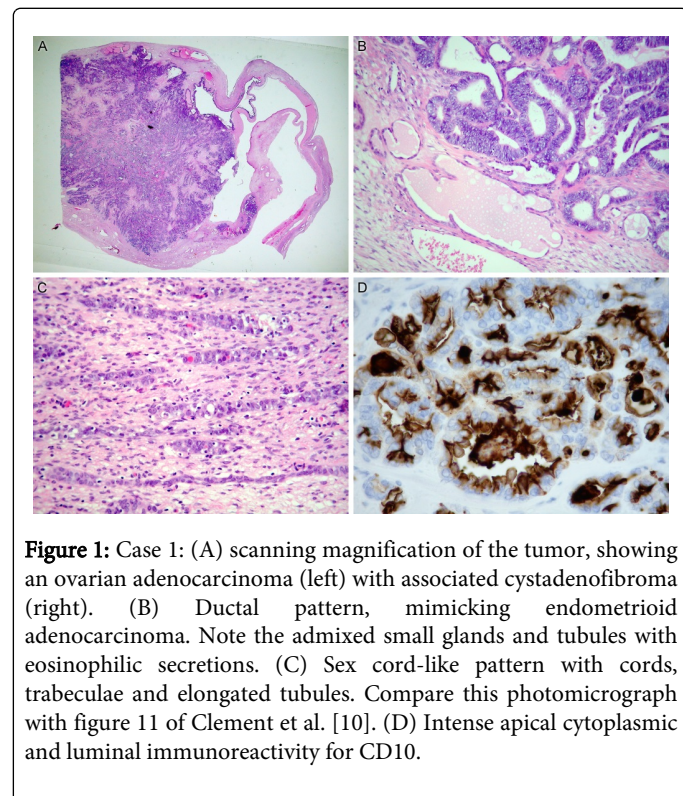
Case 1

An 80-year-old Caucasian woman presented to our hospital with a lower abdominal mass. Her previous medical history included fibrocystic breast disease, a colonic adenomatous polyp, nephrolithiasis, appendicitis and sick sinus syndrome. There was no family history of ovarian or breast cancer. Ultrasound showed a large anechogenic multilocular cyst in the left ovary, containing solid masses measuring up to several cm. MRI scan suggested a primary ovarian tumor of borderline malignancy, without evidence of peritoneal disease or distant metastases.

The patient underwent total abdominal hysterectomy with bilateral salpingo-oophorectomy, omentectomy and peritoneal biopsies. On gross pathological examination, the left ovary weighed 350 g and measured 10.2 cm in greatest dimension. Its outer surface was smooth and intact. The cut section showed a multilocular cyst, containing yellow gelatinous fluid and a solid white mural mass of 7.2 cm. A small nodule of 0.7 cm was present on the serosa of the left Fallopian tube. No significant abnormalities were seen in the other organs. On frozen section a diagnosis of well-differentiated endometrioid adenocarcinoma of the ovary was suggested. No adjuvant chemotherapy was given. The patient is relapse-free one year after surgery.

Microscopically, the mural mass was an invasive adenocarcinoma arising in a cystadenofibromatous tumor (Figure 1A). The invasive adenocarcinoma was predominantly composed of ductal and villoglandular structures, lined by a pseudostratified columnar endometrioid-like epithelium (Figure 1B). Mitotic figures were readily found, but there was no high grade nuclear atypia and cell polarity was maintained with basally located nuclei. Squamous metaplasia was completely absent and there was no associated endometriosis. Focally the tumor mimicked a papillary serous carcinoma. Part of the tumor consisted of closely packed small tubular structures lined by cuboidal to columnar cells, resembling mesonephric hyperplasia. A minor part

of the tumor exhibited a sex cord-like pattern being composed of cords, trabeculae and compressed elongated tubules (Figure 1C). The abutting cystadenofibroma was made up of fibroblastic stroma and variably sized cystic spaces, lined by a monolayered bland flat, to cuboidal, to columnar epithelium. Small benign-appearing tubules containing eosinophilic colloid-like secretions were present in the interface between the cystadenofibroma and the adenocarcinoma. The omentum, uterus and peritoneal biopsies were free of tumor. The small nodule on the left Fallopian tube was a benign adenomatoid tumor.



Immunohistochemically, the adenocarcinoma was completely negative for ER and PR. Cytokeratin AE1/AE3, epithelial membrane antigen (EMA), and cytokeratin 7 (CK7) were strongly positive. CD10 showed strong luminal and apical cytoplasmic expression (Figure 1D). Calretinin showed only focal nuclear and cytoplasmic reactivity. Staining for WT1 was negative. There was strong multifocal expression of alpha-inhibin.

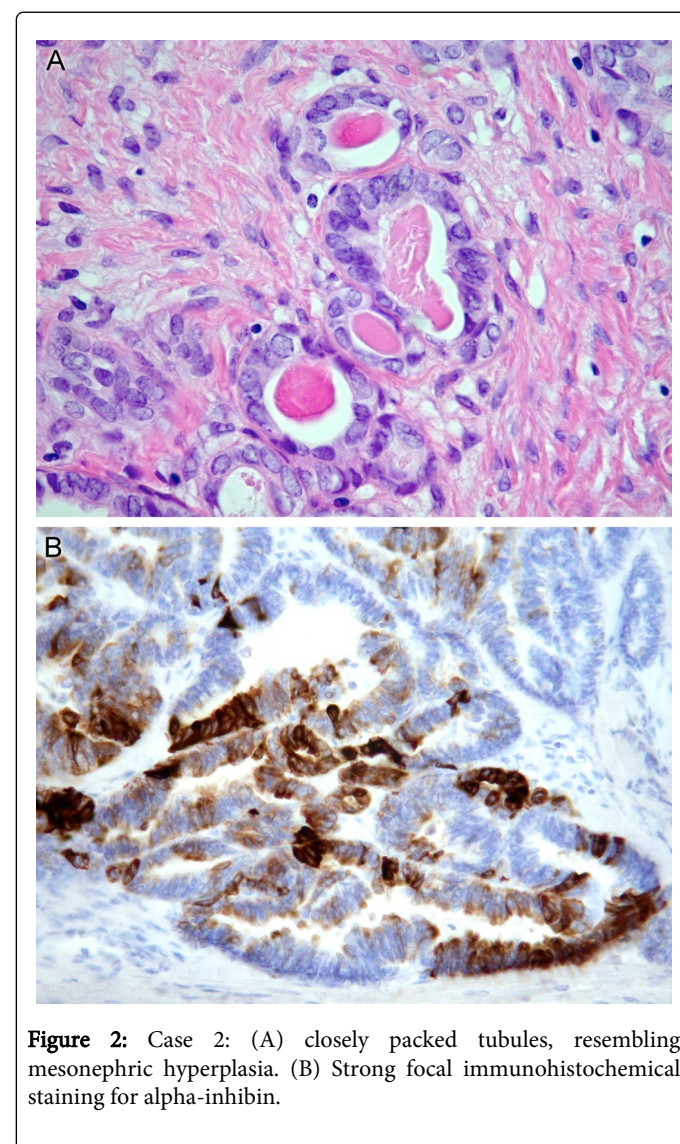
Case 2

This 79-year-old Caucasian female patient was admitted to another hospital because of abdominal distention and pain. She had a past medical history of cholecystectomy, hypertension and a mild brainstem stroke. CT scan showed a huge cystic tumor of the right ovary. A hysterectomy with bilateral salpingo-oophorectomy was performed. There was no ascites and no evidence of metastatic disease.

Gross pathological examination showed a multicystic ovarian tumor, with a weight of several kg and measuring 25 cm in diameter. Its outer surface was smooth. The inner surface of the cysts was largely covered by papillary vegetations. No tumor was present in the other genital organs. No adjuvant chemotherapy was administered. The patient is free of disease, two years after surgery.

Paraffin blocks were sent to us in consultation. Histologically, the tumor was initially considered a well-differentiated endometrioid adenocarcinoma. However, this diagnosis had to be abandoned because the tumor was completely negative for estrogen and progesterone receptors, and completely devoid of squamous differentiation. A more detailed examination of the slides revealed coexistent small tubular and slightly retiform growth patterns. Immediately adjacent to the adenocarcinoma there was an adenofibromatous component, composed of small cysts and tubules separated by a distinct fibromatous stroma. These cysts and tubules were lined by a bland cuboidal to flattened epithelium and often contained eosinophilic secretions (Figure 2A).

The tumor showed strong and diffuse cytoplasmic immunoreactivity for EMA and CK7. Luminal secretions and apical cytoplasm of the tumor cells stained intensely positive for CD10. There was strong focal nuclear and cytoplasmic positivity for calretinin, and strong focal positivity for alpha-inhibin (Figure 2B). WT1 was negative.



Discussion

In the present report, we describe two cases of mesonephric adenocarcinoma of the ovary. These cases are exceptional because of their location. The mesonephric nature of the tumors is strongly supported by the combination of ductal, tubular and sex cord-like growth patterns [10]. The ductal pattern bears a striking resemblance to endometrioid carcinoma. The tubular pattern mimics mesonephric hyperplasia, which is further enhanced by the presence of interspersed benign-appearing mesonephric-type tubules. Although there is no specific immunophenotype for mesonephric carcinoma, the immunohistochemical profile of both tumors is compatible with a mesonephric phenotype. Since both tumors arise in a cystadenofibromatous background with mesonephric features, we assume that they originate from the rete ovarii. In both cases, the relation of the tumor to the hilus is obscured by extensive ovarian involvement.

To our knowledge, the first report of an ovarian mesonephric carcinoma was published by Hughesdon in 1982 [15]. He elaborately described two "ovarian tumors of Wolffian or allied nature". Case 2 was evidently a FATWO, but his "pleomorphic" case 1 with "four types of histological appearance" was very probably a genuine mesonephric carcinoma. It can also be argued that the single case of "adenocarcinoma of rete ovarii origin", described by Rutgers and Scully in 1988 [3], belongs to the same category. This tumor exhibited a predominant retiform growth pattern and extensive transitional metaplasia. According to Nogales, its distinction from a retiform Sertoli-Leydig cell tumor is problematic [16]. Parenthetically, it is worth pointing out that the histogenesis of the rete ovarii itself is controversial. The contribution of either mesonephric tubules or medullary sex cords to the development of the rete ovarii remains uncertain.

A major problem in the pathologic diagnosis of mesonephric carcinoma of the female genital tract in general, is the fact that its true identity is often concealed behind varying degrees of pseudo-endometrioid Müllerian-like differentiation. A correct diagnosis can be achieved with the aid of immunohistochemistry. Negative staining for ER and PR, and luminal-apical staining for CD10 help to exclude a Müllerian endometrioid carcinoma [12]. Almost all cases of mesonephric carcinoma are strongly reactive for cytokeratin AE1/AE3, EMA, and CK7. Calretinin is usually positive; WT1 is negative. Alpha-inhibin is usually negative, but this may only apply for tumors arising from the distal Wolffian zone. The positive immunoreactivity for alpha-inhibin in our two cases, might be explained by participation of the medullary sex cords in the embryonic development of the rete ovarii.

According to the literature, ovarian mesonephric adenocarcinoma is a virtually non-existent entity. However, accepting this too uncritically, may lead to a low level of suspicion with the result that such tumors are erroneously diagnosed as endometrioid carcinoma. Whenever the diagnosis of Müllerian endometrioid carcinoma is not tenable histologically, because of coexistent unusual growth patterns or associated non-neoplastic mesonephric tubules, the possibility of a

mesonephric carcinoma should be considered and the diagnosis refined by using relevant immunohistochemical stains.

Because of the paucity of reports to date, it is impossible to draw conclusions about prognosis or therapy. Stage is probably an important prognostic factor. At present there are no strong arguments for treating mesonephric carcinomas otherwise than their Müllerian counterparts. Eventually, the correct distinction between Müllerian and Wolffian tumors of the female genital tract may lead to a more suitable and ideally a specifically targeted therapy.

References

1. Nogales FF (1995) Mesonephric (Wolffian) tumors of the female genital tract: is mesonephric histogenesis a mirage and trap? *Curr Diagn Pathol* 2: 94-100.
2. Young RH, Scully RE (1983) Ovarian tumors of probable wolffian origin. A report of 11 cases. *Am J Surg Pathol* 7: 125-135.
3. Rutgers JL, Scully RE (1988) Cysts (cystadenomas) and tumors of the rete ovarii. *Int J Gynecol Pathol* 7: 330-342.
4. Bagué S, Rodríguez IM, Prat J (2004) Malignant mesonephric tumors of the female genital tract: a clinicopathologic study of 9 cases. *Am J Surg Pathol* 28: 601-607.
5. Ram M, Abdulla A, Razvi K, Pandeva I, Al-Nafussi A (2009) Cystadenofibroma of the rete ovarii: a case report with review of literature. *Rare Tumors* 1: e24.
6. Devouassoux-Shisheboran M, Silver SA, Tavassoli FA (1999) Wolffian adnexal tumor, so-called female adnexal tumor of probable Wolffian origin (FATWO): Immunohistochemical evidence in support of a Wolffian origin *Hum Pathol* 30: 856-863.
7. Daya D, Murphy J, Simon G (1994) Paravaginal female adnexal tumor of probable wolffian origin. *Am J Clin Pathol* 101: 275-278.
8. Basheska NT, Yashar G, Kubelka K, Zografski G, Stavric G, et al. (1999) Paravaginal female adnexal tumor of probable Wolffian origin. A case report *Virchows Arch* 435: 230.
9. Ferry JA, Scully RE (1990) Mesonephric remnants, hyperplasia, and neoplasia in the uterine cervix. A study of 49 cases. *Am J Surg Pathol* 14: 1100-1111.
10. Clement PB, Young RH, Keh P, Ostör AG, Scully RE (1995) Malignant mesonephric neoplasms of the uterine cervix. A report of eight cases, including four with a malignant spindle cell component. *Am J Surg Pathol* 19: 1158-1171.
11. Ersahin C, Huang M, Potkul RK, Hammadeh R, Salhadar A (2005) Mesonephric adenocarcinoma of the vagina with a 3-year follow-up. *Gynecol Oncol* 99: 757-760.
12. Ordi J, Nogales FF, Palacin A, Márquez M, Pahisa J, et al. (2001) Mesonephric adenocarcinoma of the uterine corpus: CD10 expression as evidence of mesonephric differentiation. *Am J Surg Pathol* 25: 1540-1545.
13. Marquette A, Moerman P, Vergote I, Amant F (2006) Second case of uterine mesonephric adenocarcinoma. *Int J Gynecol Cancer* 16: 1450-1454.
14. Wani Y, Notohara K, Tsukayama C (2008) Mesonephric adenocarcinoma of the uterine corpus: a case report and review of the literature. *Int J Gynecol Pathol* 27: 346-352.
15. Hughesdon PE (1982) Ovarian tumours of Wolffian or allied nature: their place in ovarian oncology. *J Clin Pathol* 35: 526-535.
16. Nogales FF, Carvia RE, Donné C, Campello TR, Vidal M, et al. (1997) Adenomas of the rete ovarii. *Hum Pathol* 28: 1428-1433.