

Use of a Standardized Learning Tool to Enhance Residents' Ability to Diagnose Pneumonia on Chest Radiographs

Takahiro Matsuo^{1*}, Atsushi Kitamura¹, Naoki Nishimura¹, Genta Ishikawa¹, Hiroshi Nakaoka¹, Sachiko Ohde², Gautam A Deshpande², Daiki Kobayashi², Torahiko Jinta¹ and Naohiko Chohnabayashi¹

¹Division of Pulmonary Medicine, St. Luke's International Hospital, Tokyo, Japan

²Center for Clinical Epidemiology, St. Luke's International Hospital, Tokyo, Japan

Abstract

Objective: Resident doctors are required to gain skills in reading chest X-rays. There have been few studies regarding the effectiveness of resident education in reading chest X-ray. Here, we examined the effectiveness of an educational method we developed for radiographic interpretation.

Methods: A standardized lecture about diagnosis of pneumonia on chest X-ray was developed in 2012 and given to all first-year postgraduate (PGY1) residents at St Luke's International Hospital in Japan. The examination was composed of 30 chest X-ray images representing either no disease or pneumonia. For pneumonia films, respondents identify disease location from a choice of 6 answers (right upper lobe, right middle lobe, right lower lobe, left upper segment, left lingular segment and left lower lobe). Total scores were compared before and after the intervention, and again 1 year later.

Results: Twenty-one residents completed the 1-year follow-up exam. The overall percentage of correct answers for pre-lecture, post-lecture, and 1-year exams was 58%, 72% and 62% respectively. When we analyzed the data by disease location between pre- and post- educational intervention, percentage of correct answers increased only for images of left lower lobe (LLL) disease, rising from 61% to 88 % ($p < 0.01$), and right middle lobe (RML), increasing from 61% to 88 % ($p = 0.015$). For RML disease images, the percentage of correct answers remained 64 % after 1 year ($p = 0.007$).

Conclusion: A standardized lecture on chest X-ray reading enhanced residents' ability to diagnose pneumonia. While improvements were short-lived, the intervention was particularly effective for difficult-to-diagnose areas such as right middle lobe disease.

Keywords: Radiograph; Resident; Education; Reading

Background

Community-acquired pneumonia is a common and potentially serious illness [1]. IDSA/ATS guidelines recommend chest radiograph as part of the routine evaluation for diagnosing pneumonia [2], for which the diagnostic sensitivity and specificity is 47% to 69% and 58% to 75% respectively [3]. Among diseases often encountered by residents in the daily clinical setting, pneumonia is one of the most common; however, the interpretation of chest X-ray by on-duty residents may not be reliable [4,5]. For post graduate residents, the ability to interpret chest X-ray correctly is essential, as there are many clinical situations in which immediate consulting radiologists are unavailable, especially during night shifts or in emergency settings [6,7]. In spite of the great frequency of pneumonia, there are few studies evaluating the effectiveness of learning tools to facilitate the diagnosis of pneumonia on chest X-ray [8].

It is critical that residents gain sufficient competency in reading chest X-rays during residency, regardless of future specialty. The purpose of this study is to evaluate the efficacy of a standardized learning tool developed in our institution to enhance residents' ability to interpret pneumonia on the chest radiograph.

Methods

Study participants

A standardized lecture about diagnosis of pneumonia on chest radiograph was developed in 2012 and given to all first-year postgraduate (PGY1) residents at St Luke's International Hospital in Japan. The lecture was incorporated as a routine part of residents' orientation curriculum at the beginning of the academic year. Our institution is a tertiary-level, 520-bed community teaching hospital

in urban Tokyo, Japan which employed 25 PGY-1 residents in 2012. All participating residents were recent graduates from a standard six-year medical college in Japan (Table 1). As hands-on training is limited in the Japanese medical schools, with substantial curricular variation in clinical training depending on their school, residents are required to train in an accredited clinical practice program for a minimum of two years after graduation. Informed consent for participation in this study was sent to all residents by email. Agreement was confirmed by response to the email, excluding one resident who did not consent to participation (Figure 1).

Standardized lecture

Pulmonologists at our institution developed a 40-minute in-person lecture concerning general approach to and interpretation of chest X-ray.

Number of residents		21
Curricular track	Internal medicine	8
	Surgery	9
	Pediatrics	2
	Gynecology	2

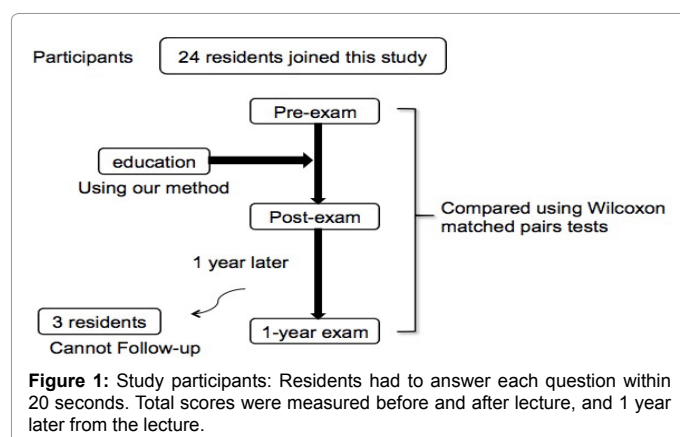
Table 1: Characteristics of study completers (N=21).

*Corresponding author: Takahiro Matsuo, Division of Pulmonary Medicine, St. Luke's International Hospital, 9-1, Akashi-cho, Chuo-ku, Tokyo, Japan, Tel: +81-3-3541-5151 Fax: +81-3-3544-0649; E-mail: tmatsuo@luke.ac.jp

Received May 30, 2016; Accepted July 07, 2016; Published July 11, 2016

Citation: Matsuo T, Kitamura A, Nishimura N, Ishikawa G, Nakaoka H, et al. (2016) Use of a Standardized Learning Tool to Enhance Residents' Ability to Diagnose Pneumonia on Chest Radiographs. J Pulm Respir Med 6: 358. doi:10.4172/2161-105X.1000358

Copyright: © 2016 Matsuo T, et al. This is an open-access article distributed under the terms of the Creative Commons Attribution License, which permits unrestricted use, distribution, and reproduction in any medium, provided the original author and source are credited.



The lecture was delivered by a chief resident in internal medicine and supported by Japanese board-certified pulmonologist. This structure focuses on how to read the normal chest radiograph including; order of reading, condition of photographing (position of light, power of light, whether patient maximally inhales or not), soft tissue and bone (ribs, clavicle, sternum, scapula, thyroid, spine, breast), central shadow (bronchus, aorta, heart, pulmonary hilum, aortic pulmonary window, paratracheal stripe), diaphragm, lung field, lobe anatomy, Silhouette sign and definition of shadow. At the end of the lecture, residents were asked to practice through some question delivered by chief resident and discuss in groups (Table 2). Sample radiograph images used in the lecture were obtained from clinical patients in our hospital database from 2004 to 2011. Prior to use in the lecture, all images were evaluated by boarded radiologists to confirm abnormality, including diagnosis and location of pneumonia.

Outcome measure

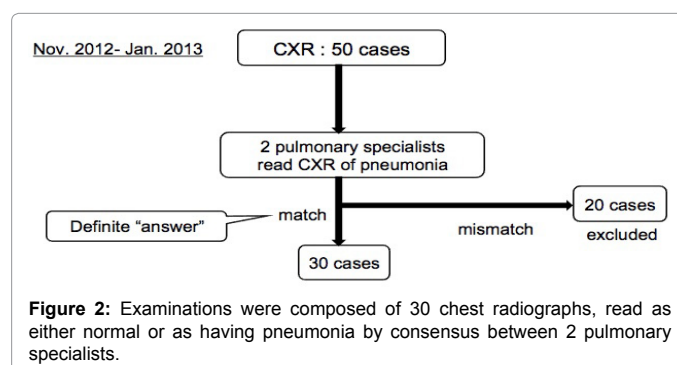
The effectiveness of this lecture-based intervention was evaluated via a pre- and post-lecture examination taken by each participating resident. The examination was composed of 30 chest X-ray images (Posterior-Anterior projection) representing either no disease or pneumonia. All examinees looked at images projected on a screen. As with images used in the lecture, test diagnoses were made and confirmed by two Japanese board-certified pulmonologists independently. Only cases in which the reading was agreed upon by consensus of two pulmonologists were used on examinations (Figure 2). After being presented with an image, examinees answered a multiple choice-style question, choosing from one of the following answers: 1) normal; 2) abnormality on right upper lobe; 3) abnormality on right middle lobe; 4) abnormality on right lower lobe; 5) abnormality on left upper lobe; 6) abnormality on left lingular segment; or 7) abnormality on left lower lobe. Examinees had to answer each question within 20 seconds. In a short time, residents were asked to focus on especially lung field for the purpose of evaluating whether there is pneumonia or not. For consistency, the same images, in different sequence, were used in each examination. To decrease bias, at no point were correct answers to exam cases provided to examinees. Total scores, representing proportion of images interpreted correctly, were compared before and after the interventional tool, and again 1 year later.

Statistical analyses

Data was analyzed using Wilcoxon matched pairs tests to compare pre-lecture scores with both post-lecture and 1-year follow-up scores. For subgroup analyses testing whether the intervention was more effective for learning the anatomy and pathophysiology of a certain

1	How to read the normal chest radiograph
1-1	Order of reading
1-2	Condition of photographing
1-2-1	Position of light
1-2-2	Power of light
1-2-3	Whether patient maximally inhales or not
1-3	Soft tissue and bone
1-4	Central shadow
1-5	Diaphragm
1-6	Lung field
2	Normal anatomy
3	Lobe anatomy
3	Silhouette sign
4	Definition of shadow (consolidation, ground glass, reticulonodular, nodular)
5	Practice

Table 2: Contents of lecture: Residents took standardized lecture according to this module by using our learning tool.



area on chest X-ray, we also compared respective scores pertaining to each pulmonary lobe. All analyses were performed using SPSS 19.0J statistical software (IBM Japan, Tokyo, Japan) and STATA 11 (STATA Corp., College Station, TX, USA).

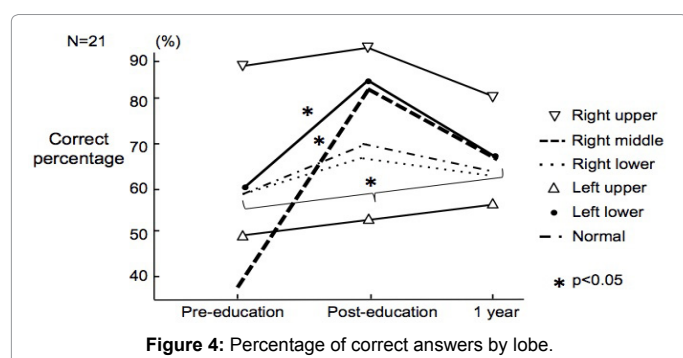
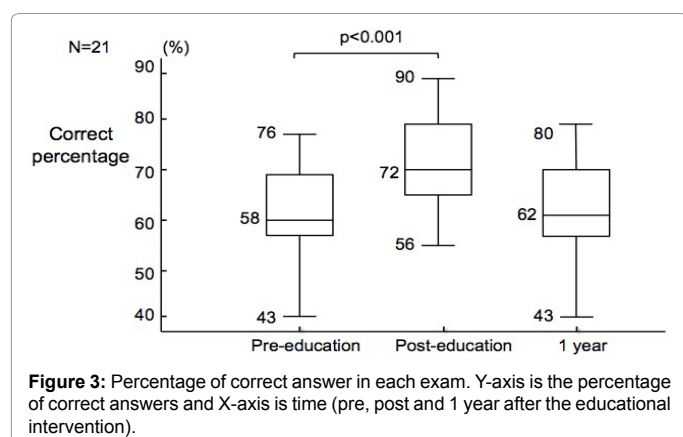
Institutional review board (IRB) approval

This study was approved by the IRB at St. Luke's International Hospital in Tokyo, Japan (Number: 12-J025).

Results

Twenty-four out of twenty-five PGY-1 residents were included in this study, of who twenty-one also completed the 1-year follow-up exam. First, we compared the percentage of correct answers between pre-lecture, post-lecture, and 1-year exams (Figure 3). Before the educational intervention, 58% of all interpretations were correct, compared to a significant increase to 72% on the post-exam ($p < 0.01$). However, at 1-year follow-up, the percentage of correct answers fell to 62%, returning to pre-intervention levels.

We identified several differences in score when analyzing the data by pulmonary lobe (Figure 4). Regarding images demonstrating disease in the left lower lobe (LLL), the mean correct percentage on pre-intervention testing was 61% compared to 86% on post-intervention testing, representing a statistically significant increase ($p = 0.015$). Nonetheless, as seen with overall results, scores fell back to a baseline of 65% at 1-year follow-up. However, for disease in the right middle lobe (RML), the percentage of correct answers rose more substantially from 33% to 83%, and remained significantly increased at 64% after 1 year ($p = 0.007$). Compared to pre-education levels, only RML scores at 1 year remained significantly higher than those at pre-education testing.



Discussion

This study aims to enhance residents' ability to accurately identify abnormal findings on chest radiography, with an emphasis on diagnosing community-acquired pneumonia. Few previous studies have quantitatively evaluated a standardized learning tool for improving residents' ability to diagnose pneumonia, a necessary clinical skill for most general clinical trainees [9]. This study demonstrates that formalized educational intervention, in the form of a standardized, clinically-oriented lecture, helps residents to diagnose pneumonia correctly, though this effect may be short-lived. Overall, the percentage of correctly identified pulmonary infiltrates increased immediately after educational intervention; one year after the intervention, this decreased to pre-education level, a baseline of which appears to hover around 60%.

Prior to educational intervention, residents had difficulty detecting lobar infiltrates, especially in the right middle and left lower lobes. Several factors may result in lobe-dependent error in these areas compared to other regions. First, in the right middle lobe, the S5 segment is located anteriorly and adjacent to the heart. To detect abnormalities in this area, familiarity with the silhouette sign is particularly helpful. Residents with little understanding of this reading technique may have a particularly difficult time identifying disease in this area. It is therefore important to emphasize the absence of a distinct demarcation between the right cardiac border and adjacent lung field. In contrast, in the left lower lobe, there are a large number of overlapping structures including the descending aorta, heart, diaphragm, and lung. A previous study reported on the difficulty of distinguishing disease, such as pneumonia and lung tumors, in the left lower lobe [10]. As such, it is critical to teach residents to systematically focus on possible abnormalities in this region [11].

In terms of persistence of educational effect on residents, the efficacy of our method was relatively short-lived. In the right middle lobe, in which pre-intervention scores were particularly low compared to other lobes, increases in accuracy of diagnosis remained even one year after intervention. While this remained significantly increased, however, correct diagnoses in the RML fell to a baseline of about 60%, similar to 1-year follow up scores for other lobes. This suggests that our educational intervention may be particularly effective in helping residents detect abnormalities in particularly difficult areas, such as the right middle lobe, and that this learning may exhibit enough "stickiness" to correct knowledge deficiencies up to a minimum standard. With respect to residents forgetting radiographic signs, we believe this is because they are only required to evaluate chest X-rays in selective rotations. We believe a potential solution is to provide exposure to chest X-rays on a regular basis. We also believe we should emphasize the importance of focusing particularly on the right middle lobe and left lower lobe, which were often misread in this study. Further discussion on what is an appropriate level for this minimum standard warrants further study, as does exploration of educational interventions to enhance retention of chest X-ray reading skills. To improve the ability to correct diagnosis of pneumonia, some reinforcements could be an effective way. We believe further studies are warranted to test the effects of this on the percentage of correct answers.

This study has several limitations that warrant discussion. First, this study was not designed as a randomized control trial; the pre-post study design introduces the possibility of temporal effects and precludes comparison with a non-intervention arm. In addition, this was a relatively small and exploratory study in a single institution, which we believe to be promising. While we understand that it is necessary to increase the sample size, we wish to publish the current paper as a preliminary report and conduct a larger study over a longer period going forward. And also, implementation and comparison with other hospitals may be useful to confirm external validity. Finally, we did not obtain Computed Tomography (CT) scans for all patients with suspected pneumonia; objective CT images may be a more precise "gold standard" than clinician reads. It is true that chest X-ray (only one projection, Posterior - Anterior) is not able to confirm the diagnosis of pneumonia and its location. And also, "40 minutes in person lecture" is a very limited time and does not cover all fields. In this study, we emphasized anatomy of lung and Silhouette sign for beginners by using chest X-ray within 40 minutes. While the correct answer is not enough confident and accurate by evaluating only chest X-ray, we believed the concordance rate between residents' and pulmonologists' answer is effective to evaluate residents' interpretation skills. Further studies are warranted to evaluate residents' interpretation ability by using CT scan.

Conclusion

A standardized lecture on chest X-ray reading for new physicians, focusing on basic reading techniques and lung anatomy, enhanced residents' ability to diagnose pneumonia. While improvements were short-lived, the intervention was particularly effective for difficult-to-diagnose areas, such as right middle lobe.

Acknowledgements

We appreciate the significant contribution made by residents and fellows at St. Luke's International Tokyo, Japan from 2012 to 2014.

References

- Musher DM, Thorne AR (2014) Community-Acquired Pneumonia. *N Engl J Med* 371: 1619-1628.
- Mandell LA, Wunderink RG, Anzueto A, Bartlett JG, Campbell GD, et al. (2007) Infectious Diseases Society of America/American Thoracic Society consensus

- guidelines on the management of community-acquired pneumonia in adults. *Clin Infect Dis* 44: S27-S72.
3. Wipf JE, Lipsky BA, Hirschmann JV, Boyko EJ, Takasugi J, et al. (1999) Diagnosing pneumonia by physical examination: relevant or relic? *Arch Intern Med* 159: 1082-1087.
 4. Feldmann EJ, Jain VR, Rakoff S, Haramati LB (2007) Radiology residents' on-call interpretation of chest radiographs for congestive heart failure. *Acad Radiol* 14: 1264-1270.
 5. Tomich J, Retrouvey M, Shaves S (2013) Emergency imaging discrepancy rates at a level 1 trauma center: Identifying the most common on-call resident "misses". *Emerg Radiol* 20: 499-505.
 6. Simon HK, Khan NS, Nordenberg DF, Wright JA (1996) Pediatric Emergency Physician Interpretation of Plain Radiographs: Is Routine Review by a Radiologist Necessary and Cost-Effective? *Ann Emerg Med* 27: 295-298.
 7. Scott Jr. WW, Bluemke DA, Mysko WK, Weller GE, Kelen GD, et al. (1995) Interpretation of emergency department radiographs by radiologists and emergency medicine physicians: teleradiology workstation versus radiograph readings. *Radiology* 195: 223-229.
 8. Towbin AJ, Paterson B, Chang PJ (2007) A Computer-Based Radiology Simulator as a Learning Tool to Help Prepare First-Year Residents for Being On Call. *Acad Radiol* 14: 1271-1283.
 9. Boutis K, Pecaric M, Pusic M (2009) Teaching X-ray interpretation: selecting the radiographs by the target population. *Med Educ* 43: 434-441.
 10. Ely JW, Berbaum KS, Bergus GR, Thompson BH, Levy BT, et al. (1996) Diagnosing left lower lobe pneumonia: usefulness of the "spine sign" on lateral chest radiographs. *J Fam Pract* 43: 242-248.
 11. Thompson BH, Berbaum KS, George MJ, Ely JW (1998) Identifying left lower lobe pneumonia at chest radiography: performance of family practice residents before and after a didactic session. *Acad Radiol* 5: 324-328.