

# The Broad Ligament Leiomyosarcoma Metastasis to the Abdominal Wall

Ali Akhavan\*

Department of Radiation Oncology, Shahid Sadoughi University of Medical Sciences, Yazd, Iran

## Introduction

Leiomyosarcoma of the broad ligament is a rare tumor and according to our knowledge only twenty cases have been reported in the English literature. Gardner et al. emphasize that, "these tumors occur on or in the broad ligament, but are completely separated from and in no way connected with either the uterus or the ovary" [1]. On the other hand metastasis of leiomyosarcoma to the abdominal wall is very rare and there is no any report of leiomyosarcoma of broad ligament with more than 33 months follow up and metastasis to the abdominal wall [2]. In this paper an Iranian 60 year old lady with metastatic leiomyosarcoma of abdominal wall five years following to than resection of leiomyosarcoma of the broad ligament is presented. It seems that the tumor's grade has worsened by time. metastatic tumor became worst with timing.

## Case Presentation

The patient was a housekeeper lady referring to our department due to palpating a mass in the lower part of her abdominal wall. The mass was painless, however it caused some fullness. The patient explained that she had noticed this bump since six months earlier and it had become larger however, as it did not make any serious problem, she had not sought any treatment. On physical examination a fairly firm mass on a point lower than the umbilicus in the midline and extended laterally and inferiorly to the right side was felt. In past medical history she was a known case of leiomyosarcoma of the right broad ligament that had been treated with external beam radiation in our center subsequent to total abdominal hysterectomy and bilateral salpingo-oophorectomy five years earlier. When we reviewed her documents it was revealed that she had a 10 cm tumor with 10 mitotic figures /10 high power fields and mild to moderate atypia.

An abdominopelvic and thoracic CT scanning was carried out which showed an oval shaped well defined soft tissue mass measuring 73 mm×44 mm just under the skin in the lower part of the abdomen attached to the rectus abdominis muscles exerting pressure on the contiguous bowel loops (Figures 1a and 1b). Other parts of the abdomen and lungs were normal.

Differential diagnosis of intramuscular masses on CT scanning

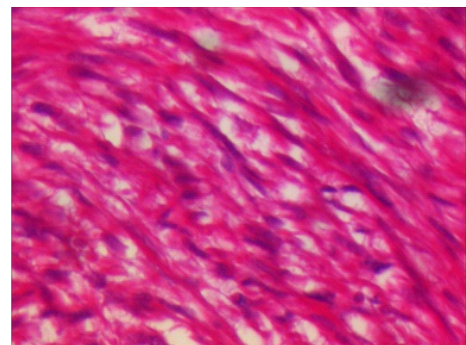
includes: lipoma, angiomatous lesions, intramuscular cysts, myxoma, desmoids tumor, sarcomas and metastatic lesions.

The pathologic differential diagnosis of leiomyosarcomas traditionally includes other sarcomas composed of fascicles of moderately differentiated spindle cells, such as fibrosarcoma and malignant peripheral nerve sheath tumor.

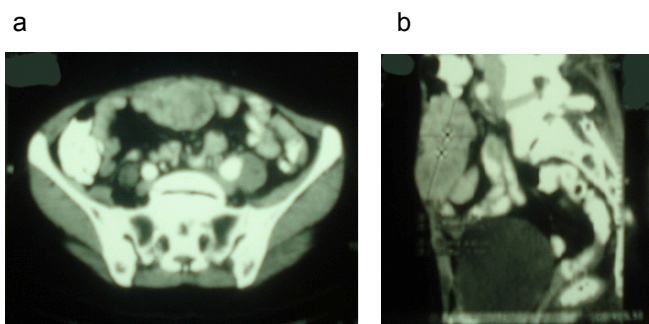
The patient was referred to the surgeon and her tumor was resected with negative margins. The tumor originated from rectus abdominis muscles. Pathological examination showed a cream-brownish colored lobulated mass composed of neoplastic cells with spindle shaped nuclei and slender cytoplasm arranged in fascicles and a herringbone pattern with more than 20 mitotic figures/10 high power fields. Giant

Monstrous cells were also present (Figure 2). Immunohistochemical study showed positive staining for Alpha smooth muscle actin (Figure 3), Desmin and Vimentin and negative staining for CD117 (Figure 4). Diagnosis was metastatic high grade leiomyosarcoma. Repeated abdominal CT scanning did not show any residual disease. At least inferior part of the tumor was located in the previous radiation field and therefore we omitted radiation therapy, however because tumor was metastatic and high grade chemotherapy with Gemcitabine 900 mg/m<sup>2</sup> on days 1 and 8 and Docetaxel 100 mg/m<sup>2</sup> on day 8 was prescribed for four cycles.

Now nine months after completing of chemotherapy the patient is well. We will perform abdominopelvic CT scanning three months later.



**Figure 2:** Section shows long intersecting fascicles of spindle cells with eosinophilic fibrillary cytoplasm and elongated blunt-ended nuclei. There is diffuse moderate to marked nuclear atypia with hyperchromatic pleomorphic nuclei.



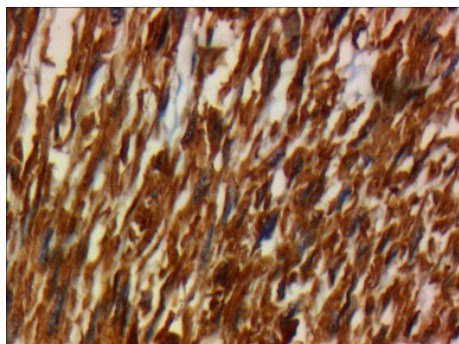
**Figure 1:** CT scanning (axial and coronal view) shows a soft tissue mass just under skin attached to the rectus abdominis muscles.

\*Corresponding author: Ali Akhavan, Radiation Oncologist, Department of Radiation Oncology, Shahid Sadoughi University of Medical Sciences, Yazd, Iran, E-mail: ali52akhavan@yahoo.com

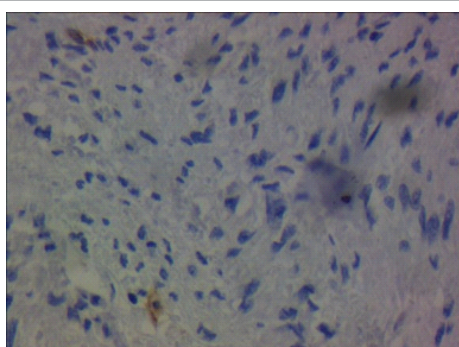
Received April 29, 2013; Accepted May 20, 2013; Published May 22, 2013

**Citation:** Akhavan A (2013) The Broad Ligament Leiomyosarcoma Metastasis to the Abdominal Wall. J Nucl Med Radiat Ther S6:013. doi:10.4172/2155-9619.S6-013

**Copyright:** © 2013 Akhavan A. This is an open-access article distributed under the terms of the Creative Commons Attribution License, which permits unrestricted use, distribution, and reproduction in any medium, provided the original author and source are credited.



**Figure 3:** IHC shows positive staining for alpha smooth muscle actin.



**Figure 4:** IHC shows negative staining for CD117.

## Discussion

The broad ligament is a peritoneal fold attaching the uterus, fallopian tubes, and ovaries to the pelvis. It is composed of a double-layered sheet of mesothelial cells. Between these two layers there is an extraperitoneal tissue referred to as the parametrium and consists of connective tissue, smooth muscles, nerves, and blood vessels [3]. Tumors of the broad ligaments are rare. Leiomyoma is the most common solid tumor of the broad ligament [2,4]. Primary malignant tumors of the broad ligament are rare and among these rare cases however, leiomyosarcoma is more common. Other malignant tumors have been seen in/on the broad ligament and must be distinguished from leiomyosarcoma including gastrointestinal stromal tumors, endometrial stromal sarcoma, malignant fibrous histiocytoma, carcinosarcoma [2,4]. This tumor commonly occurs in postmenopausal women; however some cases were premenopausal [5,6]. The symptoms are nonspecific and in almost all cases a definitive diagnosis preoperatively is impossible [2,5-7].

One of the most important issues in the management of these tumors and predicting the patients' prognosis is differentiation of leiomyosarcoma from leiomyoma and its variants.

The diagnosis of uterine LMS relies on the presence of three criteria: coagulative tumor cell necrosis, cytologic atypia and mitotic activity. Zaloudek and Hendrickson [8] proposed that presence of coagulative necrosis itself is enough for diagnosis of leiomyosarcoma. In the absence of cell necrosis the diagnosis of leiomyosarcoma needs diffuse moderate to severe cellular atypia and more than 10 mitosis/10 HPF [8,9]. Histological grading of soft tissue sarcomas and their effect on survival is a gray zone in these tumors. There are two major grading systems for grading of soft tissue sarcomas: the NCI

(United States National Cancer Institute) system and the FNCLCC (French Fédération Nationale des Centres de Lutte Contre le Cancer) system. The NCI system uses a combination of histological type, cellularity, pleomorphism and mitotic rate for attributing grade 1 or 3. The FNCLCC system is based on a score obtained by evaluating three parameters: tumor differentiation, mitotic rate (0-9, 10-19 and  $\geq 20$  mitotic figures/10HPF) and the amount of tumor necrosis ( $<50\%$  tumor necrosis and  $\geq 50\%$  tumor necrosis). According to both of them leiomyosarcoma is classified into low, intermediate and high grade.

Lung, liver and peritoneal cavity are the most common sites of metastasis. In this patient the metastatic lesion's grade has increased gradually. Metastasis of leiomyosarcoma to the abdominal wall is very rare and was not reported in leiomyosarcoma of the broad ligament.

Controversies exist regarding the effectiveness of adjuvant therapy. Although radiation therapy improves local control, it does not mean any survival advantage for these patients. Chemotherapy in adjuvant setting did not show a survival benefit. Fixed-dose Gemcitabine (900 mg/m<sup>2</sup> on day 1 and 8) combined with Docetaxel (100 mg/m<sup>2</sup> on day 8) has been shown to achieve high objective response rates as the first line therapy in metastatic uterine leiomyosarcomas [10]. From the twenty one previous reported cases only nine patients had received chemotherapy or radiotherapy or both and only for seven patients less than one year survival was reported.

## References

- Gardner Gh, Greene Rr, Peckham B (1957) Tumors of the broad ligament. *Am J Obstet Gynecol* 73: 536-554.
- Najoua B, Hanane S, Sanae, Kawtar Z, Simohamed S, et al. (2011) Leiomyosarcoma of the broad ligament: a case report and the review of the literature. *Anatol J Obstet Gynecol* 2: 1-4.
- Miller A, Hong MK, Hutson JM (2004) The broad ligament: a review of its anatomy and development in different species and hormonal environments. *Clin Anat* 17: 244-251.
- Duhan N, Singh S, Kadian YS, Duhan U, Rajotia N, et al. (2009) Primary leiomyosarcoma of broad ligament: case report and review of literature. *Arch Gynecol Obstet* 279: 705-708.
- Mirsadraee S, Mansouri A, Ataei R, Kakhi S (2008) Leiomyosarcoma of The Broad Ligament: A Case Report and Literature Review. *Iranian Journal of Pathology* 3: 104-108.
- Stita W, Trabelsi A, Hmissa S, Sriha B, Mokni M, et al. (2008) Leiomyosarcoma of the broad ligament: a case report and literature review. *Eur Clinics Obstet Gynaecol* 3: 127-129.
- Agarwal U, Dahiya P, Sangwan K (2003) Leiomyosarcoma of the broad ligament mimicking as ovarian carcinoma--a case report. *Arch Gynecol Obstet* 269: 55-56.
- Zaloudek C, Hendrickson MR Mesenchymal tumor of uterus chapter. (5th edn), *Pathology of the Female Genital Tract* By Ancel Blaustein.
- O'Brien JM, Brennan DD, Taylor DH, Holloway DP, Hurson B, et al. (2004) Skeletal muscle metastasis from uterine leiomyosarcoma. *Skeletal Radiol* 33: 655-659.
- Hensley ML, Blessing JA, Mannel R, Rose PG (2008) Fixed-dose rate gemcitabine plus docetaxel as first-line therapy for metastatic uterine leiomyosarcoma: a Gynecologic Oncology Group phase II trial. *Gynecol Oncol* 109: 329-334.

This article was originally published in a special issue, **Cancer Radiation Therapy** handled by Editor(s). Dr. Xin Chen, University of Arkansas for Medical Sciences, USA