

11C-Choline PET-CT Detection of Osseous Metastases versus Bone Scan in Newly Diagnosed High Risk Prostate Cancer Patients-A Pilot Study

Nasarachi E Onyeuku^{1*}, Diandra N Ayala-Peacock¹, Pradeep Garg² and William Blackstock A³

¹Comprehensive Cancer Center of Wake Forest University, Winston Salem, North Carolina, USA

²Executive Director, Molecular Imaging Center, Biomedical Research Foundation, Shreveport, Louisiana, USA

³Professor, Department of Radiation Oncology, Comprehensive Cancer Center of Wake Forest University, Winston-Salem, North Carolina, USA

Abstract

Purpose: Identification of osseous metastatic prostate adenocarcinoma (PCa) is traditionally based on bone scan and computerized tomography (CT) imaging. Positron emission tomography (PET) has been investigated to improve detection of metastatic disease. Given the high number of false positive and false negative results with 18-fluorodeoxyglucose (18F-FDG) PET, novel tracers including 11C-Choline have been investigated for earlier identification metastatic disease. We present a prospective pilot study comparing 11C-Choline PET/CT against traditional bone scan in detecting osseous metastases in newly diagnosed high risk PCa.

Methods: High-risk PCa patients underwent a standard initial workup: H&P, transrectal US-guided biopsy, PSA evaluation, CT scan, and bone scan. An experimental 11C-Choline PET/CT scan served to evaluate the extent of disease and predict for occult metastases. Pre-treatment bone scan and 11C-Choline PET/CT interpretations were compared with follow-up imaging, PSA, and clinical assessments to determine the predictive value of pre-treatment 11C-Choline imaging and overall outcomes.

Results: Nine patients were successfully enrolled with 11C-Choline PET imaging during the initial workup. Three patients had evidence of osseous metastases on both CT and bone scans. Two of three patients had clinical findings consistent with their imaging, with all three patients exhibiting baseline PSA levels >50. Of the three patients deemed metastatic by conventional radiography, only two of the three corresponding 11C-Choline PET/CT images were in agreement with conventional imaging. The final patient had a negative 11C-Choline study with a T10 sclerotic focus on conventional imaging that was unchanged in follow-up scans despite post-treatment biochemical failure. A fourth patient without evidence of osseous metastatic disease on conventional scans demonstrated a positive 11C-Choline PET/CT scan on initial workup. In follow-up, the patient had evidence of diffuse osseous metastatic disease visualized on conventional imaging.

Conclusion: In this limited prospective series, our results suggest an increased sensitivity of 11C-Choline PET/CT in identifying active lytic lesions and true bony metastasis.

Keywords: Nuclear medicine; Cancer radiation; Radiation therapy

Introduction

Prostate cancer is the most common cancer among men and the second most common cause of cancer death among men in the United States [1]. In 2013, estimates project over 238,000 men will be diagnosed with adenocarcinoma of the prostate (PCa) and approximately 30,000 will die of their disease. Patients with high risk prostate cancer are at increased risk for metastatic disease. Traditionally, identification of metastatic disease is based on findings on bone scan and a computerized tomography (CT) scan of the pelvis, both of which are insensitive studies for detection of metastatic prostate cancer [2].

Adenocarcinoma of the prostate continues to be a significant health problem in the United States. Treatment of localized prostate cancer includes surgery, radiation therapy, hormonal therapy or a combination of these modalities with the intent of cure [2]. Metastatic prostate cancer is typically treated with hormonal therapy and radiation only for symptom palliation. Despite advances in freedom from prostate specific antigen (PSA) failure [3-6], little progress has been made in improving survival among high risk prostate cancer patients [7]. One hindrance to the development of effective therapies is insensitive and inaccurate staging studies [8]. A significant portion of patients may be treated with curative intent when micrometastatic disease is present and not detected on current imaging studies, including bone scan and CT scan. Patients with micrometastatic disease may undergo aggressive local therapy when systemic therapy would be more appropriate.

Molecular imaging approaches including positron emission tomography (PET) have been investigated to improve the detection of metastatic disease in patients presenting with prostate cancer [9]. Initial results with 18-fluorodeoxyglucose (18F-FDG) PET demonstrated discouraging outcomes including a high number of false positives and false negatives with failure to distinguish between cancer and benign hyperplasia, and high urinary excretion and bladder concentration limiting its application in imaging of the prostate and pelvic lymph nodes [10,11]. The results of the 18-FDG PET studies have led to the evaluation of other tracers including 11C-Choline.

Choline is a critical molecule in phospholipid metabolism, transmembrane signaling, and lipid transport and metabolism [12].

***Corresponding author:** Nasarachi E Onyeuku, Comprehensive Cancer Center of Wake Forest University, Winston Salem, North Carolina, USA, E-mail: nonyeuku@wakehealth.edu

Received September 20, 2013; **Accepted** October 17, 2013; **Published** October 22, 2013

Citation: Onyeuku NE, Ayala-Peacock DN, Garg P, William Blackstock A (2013) 11C-Choline PET-CT Detection of Osseous Metastases versus Bone Scan in Newly Diagnosed High Risk Prostate Cancer Patients-A Pilot Study. J Nucl Med Radiat Ther S6: 017. doi:10.4172/2155-9619.S6-017

Copyright: © 2013 Onyeuku NE, et al. This is an open-access article distributed under the terms of the Creative Commons Attribution License, which permits unrestricted use, distribution, and reproduction in any medium, provided the original author and source are credited.

Intracellular choline is phosphorylated to phosphoryl choline by the enzyme choline kinase. Phosphoryl choline is then trapped within the cell. Prior investigations have demonstrated increased phosphoryl choline as well as increased choline kinase activity in prostate cancer cells relative to normal prostatic tissue [13]. Thus, the integration of radiolabeled choline into prostate cancer cell membranes serves as an attractive imaging possibility. The advantages of 11C-Choline over 18-FDG include a shorter half life and minimal urinary excretion [14].

The primary goal of this pilot study was to evaluate the sensitivity and specificity of PET/CT with 11C-Choline compared to bone scan in detecting osseous metastases in newly diagnosed high risk prostate cancer patients. The PET/CT findings were correlated with standard imaging findings including CT of the abdomen and pelvis and bone scan. Positive findings on PET/CT were then biopsied when feasible. Ultimately, we aimed to determine whether the presence of 11C-Choline PET/CT positivity in a population at high risk for metastatic disease was accurate for determining occult metastatic disease not discerned on conventional imaging.

Materials and Methods

Patient eligibility

Eligible patients were 30 years of age or older with histologically confirmed adenocarcinoma of the prostate. Only patients with high risk disease defined as PSA ≥ 20 or Gleason ≥ 8 or digital rectal examination revealing $\geq T2c$ (tumor involving more than one half of one lobe of the prostate), were included. Patients were not allowed to have received prior radiation therapy, hormonal therapy, surgery or cryotherapy for their prostate cancer. Patients with any prior treatment (other than biopsy) were excluded from the study. Furthermore, patients with a prior diagnosis of any cancer in the last 5 years except non-melanoma skin cancer were excluded, and patients with poorly controlled diabetes were also excluded. Eligible patients were able to tolerate IV and oral contrast in addition to 11C-PET, CT, and bone scan imaging. Patients agreed to undergo biopsy in the case of positive findings on 11C-PET/CT, CT, or bone scan. All patients were consented and the study was IRB approved.

Patient evaluation

Within 6 weeks prior to registration, eligible patients underwent a workup that included a history/physical examination including digital rectal examination, transrectal ultrasound guided biopsy, and PSA evaluation. As normal standard of care, patients underwent evaluation including a CT scan with IV contrast and a bone scan. These scans were performed pre- or post-enrollment. Any abnormality suspicious for metastatic disease underwent biopsy.

Pathologic specimen

All pathology specimens were reviewed by board certified pathologists and evaluated for Gleason score, prostatic intraepithelial neoplasia, perineural invasion and lymphovascular space invasion. Biopsies performed outside of the sponsoring institution were reviewed by our institutional pathologists.

Participant preparation

Participants fasted for a minimum of 4 hours prior to injection of 11C-Choline. 11C-Choline was synthesized and prepared in accordance with Wake Forest PET Center's standard procedures. Briefly, 11C-Choline was synthesized from N-N'-dimethylethanolamine and 11C-methyl triflate at the molecular imaging and ligand development

laboratory of Wake Forest Baptist Medical Center PET research laboratory as described previously by Hara et al. [15].

11C-choline PET-CT scan

All 11C-Choline CT PET/CT scanning was performed on a GE Health care ST-8-PET/CT simulator located in the Department of Radiation Oncology, Outpatient Comprehensive Cancer Center. This PET/CT scanner has 8 slice helical CT scanning, flat carbon-fiber table with indexing, CT-based attenuation correction, 10,080 BGO PET crystal detectors, 2D and 3D PET acquisition, and a laser positioning system. PET scanning in the PET Research Center was performed on a GE Healthcare NXi PET Scanner. No PET scans were performed at an outside institution.

After acquiring the transmission scan, 15 mCi 11C-choline was administered intravenously as a bolus. The emission scans were acquired 5 min after the tracer injection starting over the prostate region and continued over the lower abdominal region and the whole body with 7 min per bed position and for 30 min of total acquisition time. The imaging field of view of the scanner is 55 cm in diameter and 15.2 cm in axial length.

CT-Attenuation corrected images from PET/CT scan were obtained using an iterative reconstruction algorithm (OSEM) with two iteration and 28 subsets, loop filter 4.30 mm full width at half max (FWHM) and post reconstruction filter 6.0 mm FWHM.

Imaging interpretation

Interpretation of the CT of the Abdomen and Pelvis was performed by a board certified radiologist. Bone scan and 11C-Choline PET/CT interpretation were also performed by a board certified nuclear medicine physician blinded to the results of the other studies.

Visual assessments were used to interpret the PET/CT findings as positive or negative at baseline. Abnormal (positive) choline tumor uptake using visual assessment were defined as any focal or diffuse choline uptake above background that is incompatible with normal anatomy. To objectively assess the degree of 11C-Choline uptake, a semi-quantitative approach using the SUV (standard uptake value) was employed.

SUV is the ratio of activity in a tissue (in $\mu\text{Ci/ml}$) divided by the decay corrected activity injected into the patient (in $\mu\text{Ci/g}$). The resultant number is almost unitless (actually g/ml) and is a crude measure of degree of uptake of choline into the tissue. The decision to utilize the SUV method is based on a number of factors-most importantly this method does not require blood sampling and has been found to be highly reproducible (mean difference between two measurements performed within 1-week intervals was 10%), further supporting its use in serial semiquantitative analysis in 11C- choline PET/CT [16]. Injected activity was measured in a dose calibrator, corrected for residual activity in the syringe after injection, and decay corrected to time of injection. The SUV's obtained were not corrected for body-surface area or other measure of patient size/shape.

The primary reasons for determining the SUV's on the baseline 11C-choline PET/CT is to establish the area of uptake is choline-avid by visual interpretation and that the tumor-to-background SUV max is ≥ 1.5 . For the purpose of this calculation, a tight background ROI with a width of about 2.0 cm was drawn surrounding the lesion except for areas of increased physiologic activity (bowel, liver, spleen, heart)-in which the background ROI will include this normal organ activity.

For the purposes of this study, the relevant SUVs for calculation and reporting were the “peak SUV” and “max SUV” within the tumor volume. These were determined by the nuclear medicine physician visually identifying the region or regions on the PET images that qualitatively appear to have the most intense 11C-Choline uptake and correspond to known tumor based on other data (such as a CT scan). Both the peak SUV and the max SUV were calculated and reported because they each have advantages and disadvantages. Specifically, the peak SUV is less prone to “noise bias” than the max SUV [17]. However, peak SUV is more difficult to measure, especially for some PET software systems, and thus the max SUV may have a better inter-observer reliability.

For peak SUV determination, a circular region of interest (ROI) 0.75-1.5 cm in diameter centered on the maximum-value pixel will be drawn, and the manufacturer’s algorithm was used to calculate the mean SUV within this ROI; this value was reported as the peak SUV.

Treatment

No treatment decisions were made on the results of the 11C-choline PET/CT scan alone. If an abnormality was only seen on 11C-Choline PET/CT and the biopsy was negative for metastatic disease, the patient was treated definitively with radiation and hormonal therapy. If a biopsy was positive for metastatic disease in a draining lymph node region, the patient was treated definitively with radiation therapy and hormonal therapy. If a biopsy was positive for metastatic disease in any other site, the patient received hormonal therapy alone.

Draining lymph node regions that were positive by CT or PET/CT were included in the radiotherapy portals unless in the judgment of the radiation oncologist, this made the portals excessively large and unsafe. Local regional areas that were equivocal by PET/CT may or may not be included in the radiotherapy portals. The clinical judgment of the radiation oncologist was used in evaluating these areas.

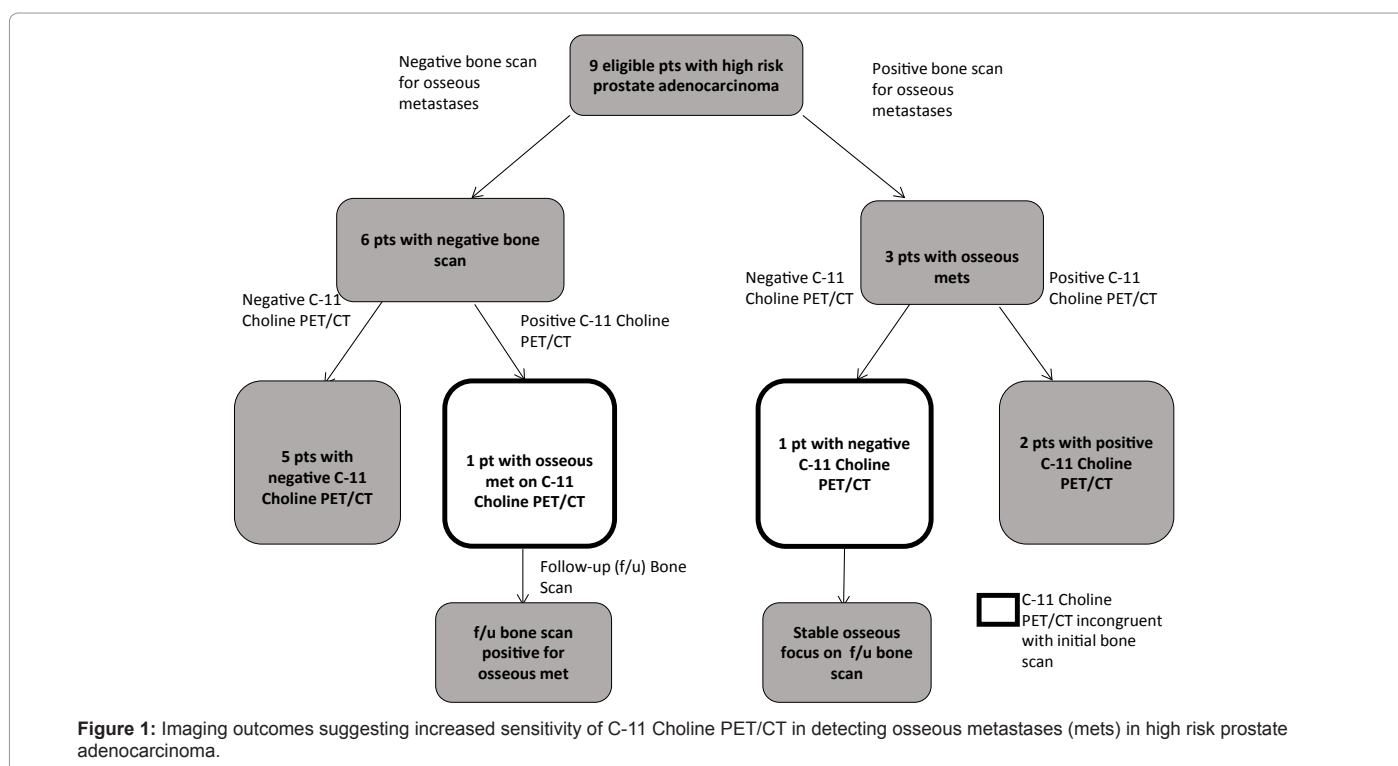
Results

Nine patients with high risk disease underwent 11C-Choline PET/CT imaging along with their initial imaging workup. Of the nine patients imaged, three had radiographic evidence of osseous metastatic disease on both CT scan and corresponding nuclear medicine bone scan. Two of the three patients presented with complaints of back pain with all three patients with baseline PSA levels >50. Of the three patients deemed metastatic by conventional radiographic methods, only two of the three corresponding 11C-Choline PET/CT images were compatible with conventional methods. The one patient who did not have complementary CT/Bone Scan and 11C-Choline PET/CT scans, had a negative C-11 image with a T10 focus identified on CT and bone scan at presentation. On follow-up imaging, that patient had stable appearance of his T10 sclerotic focus despite laboratory values consistent with post-treatment biochemical failure. Patient outcomes are depicted in Figure 1.

An additional patient was deemed to be without evidence of osseous metastatic disease by conventional methods, with a positive 11C-Choline PET/CT scan identifying 6 separate osseous metastatic sites, including involvement of the skull, spine, upper and lower extremities, left pubic symphysis and right ischium (Figures 2a and 2b). The patient was found to have PSA levels >50 and pathologically confirmed pelvic LN disease on initial workup. His follow-up imaging 5 months after initial diagnosis was then remarkable for a bone scan demonstrating new regions of increased bony uptake involving the right hemipelvis (including the right iliac crest, right sacroiliac joint and right sacrum). A Cervical and Thoracic Spine MRI performed 9 months after his initial presentation ultimately identified diffuse osseous metastasis within the spine.

Discussion and Conclusion

The extent of osseous metastatic disease is an independent



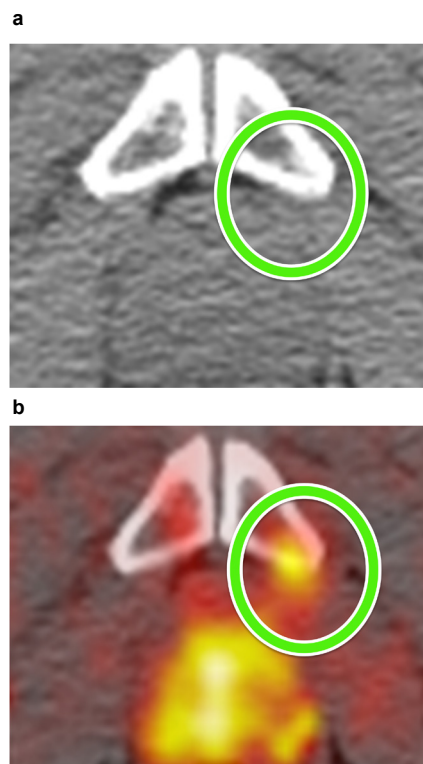


Figure 2: Computed Tomography vs. 11C-Choline

Osseous metastases in the pubic symphysis in 11C-Choline study, but absent on conventional imaging (CT scan shown, bone scan image unavailable). Follow-up bone scan demonstrated new areas of osseous involvement (image unavailable).

prognostic factor in evaluating newly diagnosed advanced prostate cancer [18,19]. The accuracy of FDG-PET in the diagnosis of metastatic prostate cancer has been put into question for several reasons. Aside from the known limitations of visualizing localized prostate cancer [inability to distinguish between benign hypertrophy and tumor and difficulty visualizing due to artifact from the bladder], prostate cancer may have low FDG uptake due to its slower metabolic rate as compared to other malignancies. Given the natural history of prostate cancer and its known low FDG avidity on PET scan, there has been a movement to identify new technologies that can better delineate metastatic lesions, which has culminated in several publications investigating the role of C-11 labeled imaging in prostate cancer diagnosis and staging [20-25]. There is also a growing collection of reported data supporting the use of 11C Choline PET/CT imaging in assessing androgen suppression therapy response in prostate cancer patients [20,24].

In a study with 26 patients with pathologically proven PCa, Reske et al. reported that 11C-Choline PET/CT demonstrated a sensitivity, specificity, and accuracy of 81%, 87%, and 84%, respectively [26]. Investigators have also reported the utility of radiolabeled choline in the evaluation of patients with rising PSA after prostatectomy [27]. The data on 11C-Choline in the evaluation of bony metastatic disease is less robust but encouraging [9,28]. In one reported series by Scher et al., 11C-Choline identified osseous metastases in 5 out of 6 patients with metastatic lesions confirmed by bone scintigraphy [29]. A more recent study of 45 patients by Tuncel et al. demonstrated the use of 11C-Choline PET/CT in the identification of 44 malignant bone lesions from a total of 61 consensus osseous lesions [30].

In 2005, Farsad et al. reviewed the results of 11C-choline PET/CT scans in 36 patients with prostate cancer and of 5 control subjects with bladder cancer. Results suggested that 11C-Choline PET could be used to detect cancer foci within the prostate, however, with a high false-negative rate and no clear way to delineate between uptake from malignancy versus benign prostatic disorders that also accumulated the tracer [31,32]. In 2008, an Italian prospective study involving 19 patients failed to show significant correlations between SUV max and PSA levels, Gleason score or pathologic stage. However, it did suggest a negative correlation between SUV and anti-androgenic therapy in both univariate and multivariate analysis [20]. Data in the biochemical recurrence setting has suggested a possible correlate between PSA levels and PSA kinetics following initial therapy [33,34]. There was also a recent 2012 prospective study investigating 11C-Choline PET/CT and bone scan in 78 patients with biochemical progression [35]. The data from Picchio et al. suggested a higher specificity, although lower sensitivity of 11C-Choline PET/CT imaging when compared to bone scan [35]. The authors hypothesized that due to its high positive predictive value, 11C-Choline could potentially predict for the presence of bone metastases at even lower-end PSA values. More recently, Beheshti et al. has shown promising results with F-18 Fluoro Choline PET/CT, suggesting a sensitivity, specificity, and accuracy in detecting bone metastases from prostate cancer of 79%, 97%, and 84%, respectively [36].

In this current study investigating 11C-Choline PET imaging, we have prospectively followed patients with sufficient follow-up to validate observed changes seen on imaging. We observed similar radiographic results to Beheshti et al. when compared to conventional methods in two of the four patients with positive findings on imaging [36]. There was one patient who had a negative 11C-Choline study with positive bone scan for a sclerotic T10 lesion that remained unchanged on subsequent imaging. Another patient was found to have a positive 11C-Choline PET study with no findings on conventional imaging. In follow-up, the patient was found to be metastatic with diffuse osseous metastasis on bone scan and MRI>5 months after his initial 11C-Choline PET/CT scan. These observations suggest an increased sensitivity of C-11 Choline PET/CT, although limited because of the size of our patient series. Nevertheless, while no definitive conclusions can be made from the limited number of observations in this series, we find our results to be encouraging regarding the utility of C-11 PET/CT in the early detection of osseous metastases in prostate cancer patients.

When reviewing our limited prospective institutional data with the growing retrospective and prospective literature, these findings add support to the recent FDA approval for 11C-Choline PET for the detection of potential sites of prostate recurrence for subsequent histologic confirmation. Early detection of metastatic disease may allow intervention with more aggressive systemic treatments that could improve outcomes for individual patients while sparing some patients from potentially morbid local therapy when systemic therapy is more appropriate. This series provides clinicians with additional evidence to support the use of C-11 Choline PET/CT for the detection of early osseous metastatic disease in newly diagnosed prostate cancer patients.

References

1. Landis MD, Lehmann BD, Pietenpol JA, Chang JC (2013) Patient-derived breast tumor xenografts facilitating personalized cancer therapy. *Breast Cancer Res* 15: 201.
2. NCCN Clinical Practice Guidelines in Oncology (NCCN Guideline®): Prostate.
3. Pollack A, Zagars GK, Starkschall G, Antolak JA, Lee JJ, et al. (2002) Prostate

- cancer radiation dose response: results of the M. D. Anderson phase III randomized trial. *Int J Radiat Oncol Biol Phys* 53: 1097-1105.
4. Dearnaley DP, Sydes MR, Graham JD, Aird EG, Bottomley D, et al. (2007) Escalated-dose versus standard-dose conformal radiotherapy in prostate cancer: first results from the MRC RT01 randomised controlled trial. *Lancet Oncol* 8: 475-487.
 5. Zelefsky MJ, Reuter VE, Fuks Z, Scardino P, Shippy A (2008) Influence of local tumor control on distant metastases and cancer related mortality after external beam radiotherapy for prostate cancer. *J Urol* 179: 1368-1373.
 6. Zelefsky MJ, Yamada Y, Fuks Z, Zhang Z, Hunt M, et al. (2008) Long-term results of conformal radiotherapy for prostate cancer: impact of dose escalation on biochemical tumor control and distant metastases-free survival outcomes. *Int J Radiat Oncol Biol Phys* 71: 1028-1033.
 7. Viani GA, Stefano EJ, Afonso SL (2009) Higher-than-conventional radiation doses in localized prostate cancer treatment: a meta-analysis of randomized, controlled trials. *Int J Radiat Oncol Biol Phys* 74: 1405-1418.
 8. Turkbey B, Pinto PA, Choyke PL (2009) Imaging techniques for prostate cancer: implications for focal therapy. *Nat Rev Urol* 6: 191-203.
 9. Jadvar H (2011) Prostate cancer: PET with 18F-FDG, 18F- or 11C-acetate, and 18F- or 11C-choline. *J Nucl Med* 52: 81-89.
 10. Effer PJ, Bares R, Handt S, Wolff JM, Büll U, et al. (1996) Metabolic imaging of untreated prostate cancer by positron emission tomography with 18fluorine-labeled deoxyglucose. *J Urol* 155: 994-998.
 11. Als C, Taton G, Van Gansbeke D, Zalman M, Lallemand LB, et al. (1990) Spect Anti-CEA Immunoscintigraphy (IS) and 18FFDG PET In the Evaluation of Colorectal Carcinoma. *Eur J Nucl Med* 16.
 12. Podo F (1999) Tumour phospholipid metabolism. *NMR Biomed* 12: 413-439.
 13. Janardhan S, Srivani P, Sastry GN (2006) Choline kinase: an important target for cancer. *Curr Med Chem* 13: 1169-1186.
 14. Torizuka T, Kanno T, Futatsubashi M, Okada H, Yoshikawa E, et al. (2003) Imaging of gynecologic tumors: comparison of (11)C-choline PET with (18) F-FDG PET. *J Nucl Med* 44: 1051-1056.
 15. Hara T, Kosaka N, Shinoura N, Kondo T (1997) PET imaging of brain tumor with [methyl-11C]choline. *J Nucl Med* 38: 842-847.
 16. Eckelman WC, Tatum JL, Kurdziel KA, Croft BY (2000) Quantitative analysis of tumor biochemistry using PET and SPECT. *Nucl Med Biol* 27: 633-635.
 17. Adams MC, Turkington TG, Wilson JM, Wong TZ (2010) A systematic review of the factors affecting accuracy of SUV measurements. *AJR Am J Roentgenol* 195: 310-320.
 18. Rigaud J, Tiguert R, Le Normand L, Karam G, Glemain P, et al. (2002) Prognostic value of bone scan in patients with metastatic prostate cancer treated initially with androgen deprivation therapy. *J Urol* 168: 1423-1426.
 19. Sabbatini P, Larson SM, Kremer A, Zhang ZF, Sun M, et al. (1999) Prognostic significance of extent of disease in bone in patients with androgen-independent prostate cancer. *J Clin Oncol* 17: 948-957.
 20. Giampiero Giovacchini, Maria Picchio, Elisa Coradeschi, Vincenzo Scattoni, Valentino Bettinardi, et al. (2008) [(11)C]choline uptake with PET/CT for the initial diagnosis of prostate cancer: relation to PSA levels, tumour stage and anti-androgenic therapy. *Eur J Nucl Med Mol Imaging* 35: 1065-1073.
 21. Yoshida S, Nakagomi K, Goto S, Futatsubashi M, Torizuka T (2005) 11C-choline positron emission tomography in prostate cancer: primary staging and recurrent site staging. *Urol Int* 74: 214-220.
 22. Sutinen E, Nurmi M, Roivainen A, Varpula M, Tolvanen T, et al. (2004) Kinetics of [(11)C]choline uptake in prostate cancer: a PET study. *Eur J Nucl Med Mol Imaging* 31: 317-324.
 23. Piert M, Park H, Khan A, Siddiqui J, Hussain H, et al. (2009) Detection of aggressive primary prostate cancer with 11C-choline PET/CT using multimodality fusion techniques. *J Nucl Med* 50: 1585-1593.
 24. Hara T, Kosaka N, Kishi H (1998) PET imaging of prostate cancer using carbon-11-choline. *J Nucl Med* 39: 990-995.
 25. Kotzerke J, Prang J, Neumaier B, Volkmer B, Guhlmann A, et al. (2000) Experience with carbon-11 choline positron emission tomography in prostate carcinoma. *Eur J Nucl Med* 27: 1415-1419.
 26. Reske SN, Blumstein NM, Neumaier B, Gottfried HW, Finsterbusch F, et al. (2006) Imaging prostate cancer with 11C-choline PET/CT. *J Nucl Med* 47: 1249-1254.
 27. Picchio M, Messa C, Landoni C, Gianolli L, Sironi S, et al. (2003) Value of [(11)C]choline-positron emission tomography for re-staging prostate cancer: a comparison with [18F]fluorodeoxyglucose-positron emission tomography. *J Urol* 169: 1337-1340.
 28. Fuccio C, Castellucci P, Schiavina R, Santi I, Allegri V, et al. (2010) Role of 11C-choline PET/CT in the restaging of prostate cancer patients showing a single lesion on bone scintigraphy. *Ann Nucl Med* 24: 485-492.
 29. Scher B, Seitz M, Albinger W, Tiling R, Scherr M, et al. (2007) Value of 11C-choline PET and PET/CT in patients with suspected prostate cancer. *Eur J Nucl Med Mol Imaging* 34: 45-53.
 30. Tuncel M, Souvatzoglou M, Herrmann K, Stollfuss J, Schuster T, et al. (2008) [(11)C]Choline positron emission tomography/computed tomography for staging and restaging of patients with advanced prostate cancer. *Nucl Med Biol* 35: 689-695.
 31. Fuccio C, Schiavina R, Castellucci P, Rubello D, Martorana G, et al. (2011) Androgen deprivation therapy influences the uptake of 11C-choline in patients with recurrent prostate cancer: the preliminary results of a sequential PET/CT study. *Eur J Nucl Med Mol Imaging* 38: 1985-1989.
 32. Farsad M, Schiavina R, Castellucci P, Nanni C, Corti B, et al. (2005) Detection and localization of prostate cancer: correlation of (11)C-choline PET/CT with histopathologic step-section analysis. *J Nucl Med* 46: 1642-1649.
 33. Krause BJ, Souvatzoglou M, Tuncel M, Herrmann K, Buck AK, et al. (2008) The detection rate of [(11)C]choline-PET/CT depends on the serum PSA-value in patients with biochemical recurrence of prostate cancer. *Eur J Nucl Med Mol Imaging* 35: 18-23.
 34. Castellucci P, Fuccio C, Nanni C, Santi I, Rizzello A, et al. (2009) Influence of trigger PSA and PSA kinetics on 11C-Choline PET/CT detection rate in patients with biochemical relapse after radical prostatectomy. *J Nucl Med* 50: 1394-1400.
 35. Picchio M, Spinapolice EG, Fallanca F, Crivellaro C, Giovacchini G, et al. (2012) [(11)C]Choline PET/CT detection of bone metastases in patients with PSA progression after primary treatment for prostate cancer: comparison with bone scintigraphy. *Eur J Nucl Med Mol Imaging* 39: 13-26.
 36. Beheshti M, Vali R, Waldenberger P, Fitz F, Nader M, et al. (2010) The use of F-18 choline PET in the assessment of bone metastases in prostate cancer: correlation with morphological changes on CT. *Mol Imaging Biol* 12: 98-107.

Citation: Onyeuku NE, Ayala-Peacock DN, Garg P, William Blackstock A (2013) 11C-Choline PET-CT Detection of Osseous Metastases versus Bone Scan in Newly Diagnosed High Risk Prostate Cancer Patients-A Pilot Study. *J Nucl Med Radiat Ther* S6: 017. doi:[10.4172/2155-9619.S6-017](https://doi.org/10.4172/2155-9619.S6-017)

This article was originally published in a special issue, **Cancer Radiation Therapy** handled by Editor(s). Dr. Xin Chen, University of Arkansas for Medical Sciences, USA

Submit your next manuscript and get advantages of OMICS Group submissions

Unique features:

- User friendly/feasible website-translation of your paper to 50 world's leading languages
- Audio Version of published paper
- Digital articles to share and explore

Special features:

- 250 Open Access Journals
- 20,000 editorial team
- 21 days rapid review process
- Quality and quick editorial, review and publication processing
- Indexing at PubMed (partial), Scopus, EBSCO, Index Copernicus and Google Scholar etc
- Sharing Option: Social Networking Enabled
- Authors, Reviewers and Editors rewarded with online Scientific Credits
- Better discount for your subsequent articles

Submit your manuscript at: www.editorialmanager.com/biochem