

Research Article

Open Access

# Actocardiographic Analysis of Fetal Hypoxia Detected by the Bradycardia, Loss of Fetal Heart Rate Acceleration, and Long Term Variability

Kazuo Maeda\*

Honorary Professor, Department of Obstetrics and Gynecology, Tottori University Medical School, Yonago, Japan

## Abstract

**Aims:** To clarify the mechanism of hypoxic Fetal Heart Rate (FHR) by the actocardiogram.

**Methods:** Hypoxic rabbit heart rate and  $\text{PaO}_2$  were studied. Long Term FHR Variability (LTV) was studied in physiologic sinusoidal FHR and anencephalic fetus, the acceleration in hypoxia, and by its electronic simulation and adult heart rate.

**Results:** Anencephalic neonatal bradycardia was caused by the excitation of remained medulla oblongata. Rabbit's bradycardia was parallel to  $\text{PaO}_2$  under 50 mm Hg, which disappeared after urethane anesthesia. Human fetal bradycardia was caused by the hypoxia, because fetal  $\text{PaO}_2$  is less than 50 mm Hg. FHR acceleration was evoked in the midbrain by the large fetal movement bursts, and minor movements evoked LTV. Physiologic sinusoidal FHR was a particular form of LTV. Triangular acceleration was simulated by the electronic integral circuit, and by the triangular heart rate in adult exercises. Fetal outcome was correlated to the acceleration duration. Hypoxia damaged fetal brain in nonreactive FHR, losing acceleration, and advanced hypoxia further damaged brain a few days after the loss of acceleration, showing the loss of LTV and bradycardia. The loss of LTV which was confirmed by the frequency power spectrum was rare, but its brain damage was as severe as the apnea of anencephalic neonate, which lost cerebral respiratory center.

**Conclusion:** Hypoxic bradycardia was evoked by the excited medulla oblongata in the decreased  $\text{PaO}_2$ , which was lower than 50 mm Hg. The hypoxia damaged fetus in fetal bradycardia, the losses of acceleration and LTV, in relation to fetal movements.

**Keywords:** Actocardiogram; Fetus; Heart rate; Hypoxia; Bradycardia; Acceleration; LTV; Anencephaly; Simulation

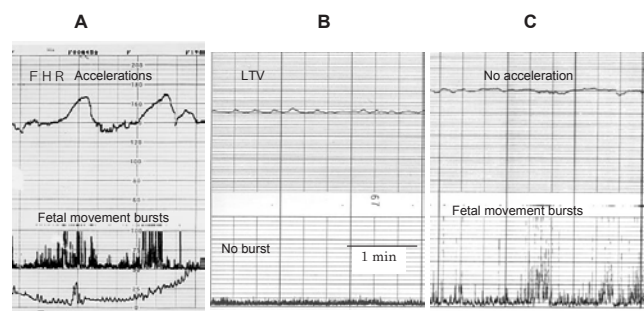
## Background

Actocardiogram records fetal heart rate, fetal movement and uterine contraction, simultaneously with single ultrasonic Doppler probe, and invented by Maeda [1]. Since the fetus in utero was unable to see, the fetal cardiogram (CTG) monitored intrapartum Fetal Heart Rate (FHR), with fetal ECG detected by fetal scalp Needle electrode, and external monitor with ultrasonic Doppler fetal heart signal at maternal abdomen, for the external monitoring to enable the test, even in pregnancy. Perinatal deaths, neonatal asphyxia and neurological sequela were reduced by the fetal monitoring, and fetal movements were studied using the same ultrasound, as fetal heart beat detection in the Actocardiogram (ACG) (Figure 1), for the further precise fetal diagnosis. Main signs to detect fetal hypoxia were continuous or transient fetal bradycardia in common monitoring, while the loss of long term FHR variability (LTV), and the loss of fetal

heart rate acceleration were in controversy in their origin and the mechanism of their disappearance, thus we intended to study the ACG by the added information of fetal movement.

## Materials and Methods

Initial prototype actocardiograph was hand-made by K Maeda. Basic functions of actocardiogram was clarified. Recorded actocardiograms in 1984 to 2010 were clinically studied. Four fetal behaviors were classified by the actocardiograms. Five numeric actocardiographic parameters were evaluated. Fetal outcomes were studied with actocardiograms of central nervous system lesion and common fetal disorders. The relation of hypoxic rabbit heart rate and  $\text{PaO}_2$  were studied. Long Term FHR Variability (LTV) and FHR accelerations were studied in physiologic sinusoidal FHR, hypoxic fetuses and anencephalic fetus. The LTV was compared to irregular minor fetal movements. FHR acceleration was compared to electronic simulation and the heart rate change in adult movements.



**Figure 1:** Three actocardiograms. (A) Normal active fetal state, (B) normal fetal resting state, (C) Abnormal non-reactive FHR with the loss of acceleration.

**\*Corresponding author:** Kazuo Maeda, Honorary Professor, Department of Obstetrics and Gynecology, Tottori University Medical School, 3-125, Nadamachi, Yonago, Tottoriken, 683-0835 Japan, Tel: 81-859-22-6856; Fax: 81-859-22-6856; E-mail: [maedak@mocha.ocn.ne.jp](mailto:maedak@mocha.ocn.ne.jp)

**Received** October 04, 2012; **Accepted** November 23, 2012; **Published** November 28, 2012

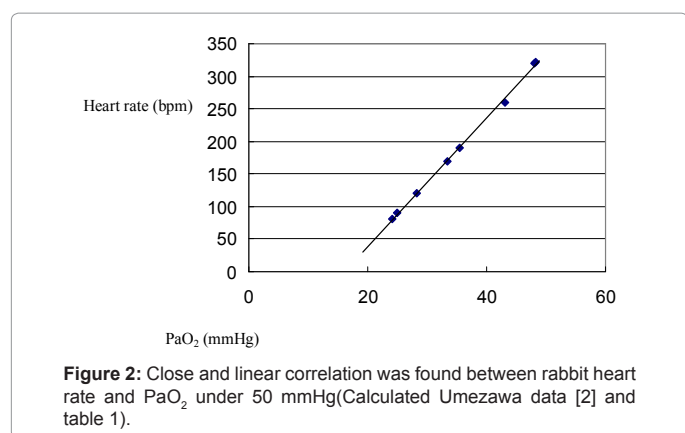
**Citation:** Maeda K (2013) Actocardiographic Analysis of Fetal Hypoxia Detected by the Bradycardia, Loss of Fetal Heart Rate Acceleration, and Long Term Variability. J Health Med Inform 4: 118. doi:10.4172/2157-7420.1000118

**Copyright:** © 2013 Maeda K. This is an open-access article distributed under the terms of the Creative Commons Attribution License, which permits unrestricted use, distribution, and reproduction in any medium, provided the original author and source are credited.

Heart rate (bpm);Y	PaO <sub>2</sub> (mm Hg);X
322	48.2
320	48.0
260	43.0
190	35.5
170	33.5
120	28.3
90	25
80	24.2

Y=9.98X-162.30, R<sup>2</sup>=1.00, P<0.001

**Table 1:** Although no correlation was found between heart rate and PaO<sub>2</sub> higher than 50 mm Hg, close correlation of rabbit heart rate (X, bpm) and PaO<sub>2</sub> (Y, mm Hg), lower than 50 mm Hg was noticed (Calculated Umezawa data [2]).



**Figure 2:** Close and linear correlation was found between rabbit heart rate and PaO<sub>2</sub> under 50 mmHg(Calculated Umezawa data [2] and table 1).

## Study Design

Experimental rabbit hypoxia and bradycardia in the PaO<sub>2</sub> less than 50 mm Hg [2] was analysed. FHR of anencephalic fetus, the bradycardia of anencephalic neonate, physiological sinusoidal FHR associated with periodic fetal respiratory movements, augmented LTV and fetal movements in resting and active fetal states, frequency spectral analysis of FHR baseline, electronic simulation of the changing fetal movement burst into triangular FHR acceleration, in signal delaying integral circuit, and adult heart rate curve in the exercise, were studied to solve various doubts in FHR in hypoxia.

## Results

### Fetal bradycardia

FHR decreases and forms bradycardia when the fetus is affected by hypoxia, while adults show no heart rate change in reduced oxygen, Umezawa [2] studied adult rabbit heart rate in hypoxia produced by the nitrous gas inhalation. The heart rate showed no change when the PaO<sub>2</sub> was above 50 mm Hg, while the heart rate decreased parallel to the lowering PaO<sub>2</sub>, if the PaO<sub>2</sub> was under 50 mm Hg (Table 1, figure 2).

Fetal heart rate decrease (bradycardia) will indicate the presence of hypoxia because the PaO<sub>2</sub> was lower than 50 mm Hg in umbilical arterial blood, in almost all of human fetuses [3,4].

What is the role of bradycardia in hypoxia? The anencephalic neonate lost most of cortical brain and remained brain stem, that meant the fetus was apnea because of the lack of respiratory center, thus fell into severe hypoxia due to low PaO<sub>2</sub> after birth. Remained brain stem of anencephalic neonate still preserved medulla oblongata constructed of para-sympathetic nerve center. The autonomic nerve

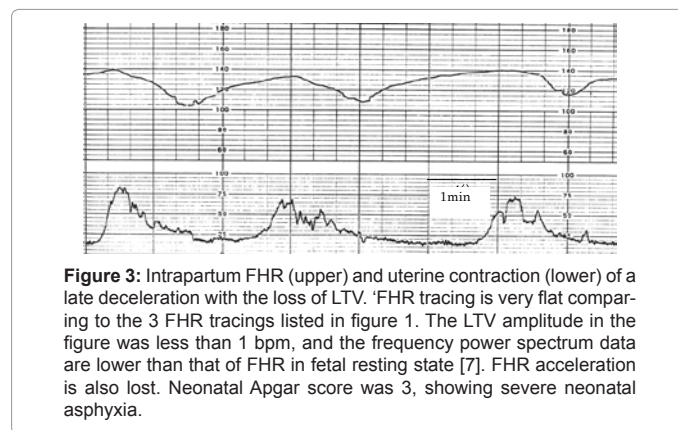
center may excite against the hypoxia, suppressing heart beats and producing bradycardia. This vagal center excitation was confirmed by the infusion of oxygenated blood into the anencephalic neonatal vein, to sedate the vagal center and recover the bradycardia to normal heart rate [5]. The experimental rabbit hypoxia did not produce bradycardia after the urethane anesthesia, which might be caused by the paralysis of rabbit medulla oblongata, where vagal nerve center did not excite and heart rate failed to decrease [2]. The vagal center may reduce hypoxic damages by its excitation to produce bradycardia in human fetus [6-8]. Thus, the bradycardia is diagnosed as the sign of hypoxia in fetal monitoring. There is continuous bradycardia, as well as transient bradycardia in late deceleration, severe variable and prolonged deceleration in fetal hypoxia.

### Loss of LTV in fetal hypoxia

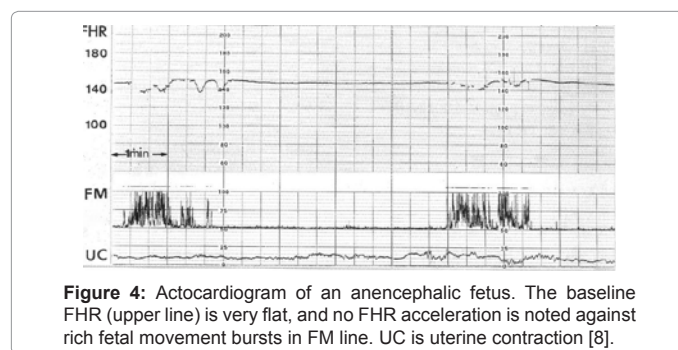
Long term FHR baseline variability (LTV) disappeared and the FHR baseline changes to a flat line in advanced hypoxia and anencephalic fetus (Figure 3 and 4).

### Developing mechanism of Long Term Variability (LTV) of FHR

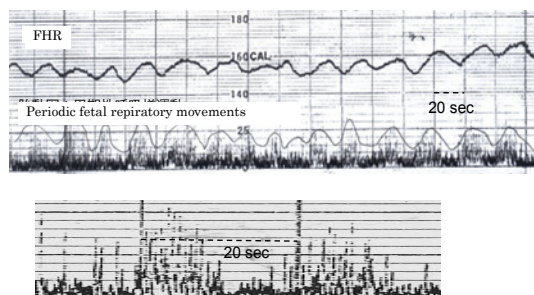
The FHR in figure 5 is physiologic sinusoidal fetal FHR, i.e. sine wave like FHR changes are repeated against sine wave-like periodic fetal respiratory movements, separating the tracing from ominous sinusoidal FHR [9]. Sine wave like FHR is evoked by small fetal periodic respiratory movements. The FHR change delayed for 7 seconds to fetal movement in the cross correlation of FHR and fetal movement [10]. The figure shows a particular case of LTV which is evoked by fetal periodic respiratory movements, though it has been told that LTV is formed by the competition of sympathetic and parasympathetic nerves. LTV is provoked by minor fetal movements, while acceleration develops by large fetal movement burst in the same variability developing center.



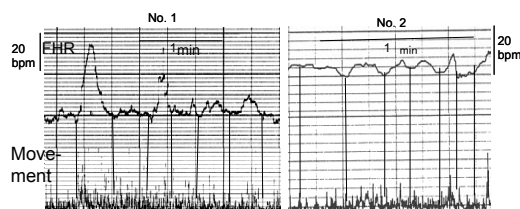
**Figure 3:** Intrapartum FHR (upper) and uterine contraction (lower) of a late deceleration with the loss of LTV. FHR tracing is very flat comparing to the 3 FHR tracings listed in figure 1. The LTV amplitude in the figure was less than 1 bpm, and the frequency power spectrum data are lower than that of FHR in fetal resting state [7]. FHR acceleration is also lost. Neonatal Apgar score was 3, showing severe neonatal asphyxia.



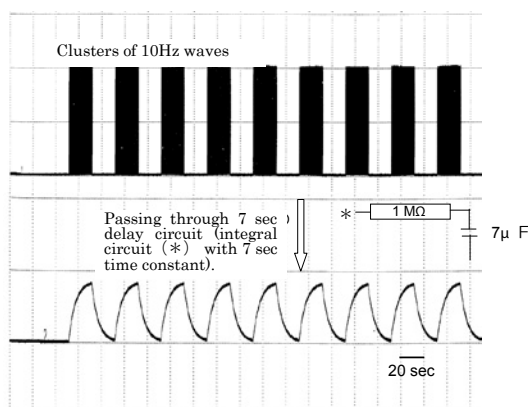
**Figure 4:** Actocardiogram of an anencephalic fetus. The baseline FHR (upper line) is very flat, and no FHR acceleration is noted against rich fetal movement bursts in FM line. UC is uterine contraction [8].



**Figure 5:** The most upper line shows physiologic sinusoidal FHR synchronized to the Envelope of fetal periodic respiration signals recorded in the second line. FHR change delayed to the movement for 7 seconds. The lowest line is augmented sine wave-like periodic changes composed of 1 Hz movements, which shows fetal respirations.



**Figure 6:** Minor fetal movements provoke LTV in 2 cases of for about twice augmented actocardiograms in active states. No.1 accompanied FHR acceleration evoked by a large fetal motion, and No.2 merely minor movements.



**Figure 7:** Electronic simulation of developing FHR acceleration. Clusters of waves (bursts) were passed through 7 sec delay circuit (integral circuit with 7 sec time constant), and triangular waves were obtained (Courtesy T. Ando). The function of FHR acceleration forming center may be similar to the delay system shown in this figure.

That will be the reason that the loss of LTV frequently accompanies no acceleration in hypoxic suppression, or paralysis of the variability producing center as the part of brain damage in fetal hypoxia, because the phenomena are the same as the lack of LTV and acceleration in the anencephalic FHR, who lost the major part of brain (Figure 4).

The physiological sinusoidal FHR will be a particular case of LTV, i.e. irregular minor fetal movements will provoke irregular LTV (Figure 6), while regular fetal movements evoked regular FHR changes (Figure 5), under the same developmental mechanism. Actually, the FHR baseline LTV tracings were similar to the minor and irregular fetal movements in actocardiogram (Figure 6). The LTV would be

formed by minor and irregular fetal movements in fetal brain, because no LTV was recorded in anencephalic fetus, who lost the major part of brain (Figure 4).

### Hypoxic brain damage in the loss of LTV

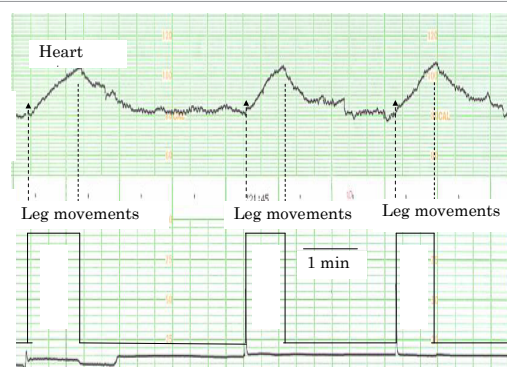
The LTV will be lost in advanced hypoxia as shown in figure 3. FHR acceleration was lost in non-reactive FHR, but the LTV is preserved (Figure 1C), before the loss of LTV and the appearance of bradycardia, a few days after the onset of non-reactive FHR. Therefore, the loss of LTV will be advanced sign of hypoxia because the loss of LTV is the same as the anencephalic FHR, of which neonate showed apnea due to the lack of respiratory center, and therefore the brain of apneic Apgar 3 neonate after the loss of fetal LTV would be severely damaged, and may have neurological sequelae. The loss of LTV is, however, rare among clinical hypoxic cases in our experience, because the cases are usually treated by cesarean section, before severe brain damage at present.

Where will be located the center of LTV formation? It will be estimated that the LTV center is the same center of FHR acceleration where minor fetal movement produces LTV, while large movement burst may provoke large acceleration. The location of LTV developing center will be discussed in the chapter of FHR acceleration.

### Loss of FHR acceleration in fetal hypoxia

Transient FHR rise with the duration >15 seconds and amplitude >15 bpm in triangular shape, is the acceleration which synchronized to fetal movement burst (Figure 1A). Since fetal movement burst provokes FHR acceleration, the developmental mechanism will be the same as the LTV, of which center will be located in the brain, because the anencephalic fetus who lost major part of brain did not produce acceleration against fetal movement burst (Figure 4). Terao et al. [4] reported that the center of acceleration was located in the midbrain, in his studies on FHR of anencephalic fetus.

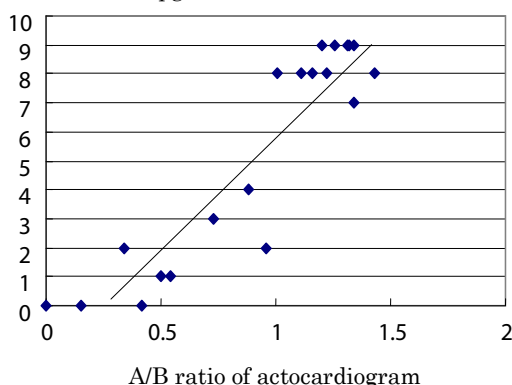
The damage or paralysis of fetal brain will cause the loss of acceleration in the cases of non-reactive FHR, where no acceleration was noted against fetal movement burst. Since the loss of LTV usually accompanies the loss of acceleration, the center of the development of acceleration will be the same as the LTV, i.e. it will be located in the brain, maybe in the midbrain.



**Figure 8:** FHR acceleration was simulated in adult. Heart rate was recorded placing the heart probe on anterior chest wall and the legs were moved continuously on the chair for 1 minute, and heart rate was recorded by an ultrasonic fetal monitor. The onset and stop of movements were marked on the chart by touching the sensor of uterine contraction. Triangular heart rate changes similar to fetal accelerations were recorded, but the heart rate change was not recognized by the subject person. Therefore, the center for the LTV and acceleration will be located not at the brain cortex, but maybe in the midbrain.



One minute Apgar score



$Y = 7.68X - 1.75$ ,  $R^2 = 0.86$ ,  $P < 0.001$  in the correlation of A/B ratio (X) and 1min Apgar score (Y). If Y is 5 min Apgar score,  $Y = 6.71X - 0.35$ ,  $R^2 = 0.74$ ,  $p < 0.01$ .

**Figure 9:** Close correlation of fetal A/B ratio (X) and 1 min Apgar score (Y) [12]. Apgar 6-4 is mild to moderate neonatal asphyxia and Apgar 3-0 is severe asphyxia.

The shape of acceleration is commonly triangular, despite the movement burst is not always triangular, but it takes various shapes (Figure 1A). We intended to show the mechanism of triangular shape by the delay of FHR for 7 seconds to the movement burst in the acceleration, provoked by the movement. An electronic simulation was tried, managing the burst signals inserting 7 seconds delay circuit (integral circuit with the time constant of 7 seconds), then the input and output of the delay system were compared. The output of the delay system was triangular wave, when the input is the cluster of waves with the duration of 30 seconds (Figure 7). Fetal movement burst may change to triangular acceleration by passing through the FHR delay system.

Also, we tried to study adult heart rate increase in the continuous leg motion for about 1 minute. The leg motion took nearly square form, but the heart rate increases were invariably triangular waves (Figure 8). The same acceleration developing center as the adult will be located in fetal brain. Since the heart rate change was insensitive for the subject person; the center is located in the brain but not in the cortex, as it will be located probably in the midbrain.

### Fetal outcome prediction by the acceleration

As mentioned before, the loss of acceleration is non-reactive FHR in fetal monitoring, and it is the sign of fetal hypoxia, followed by non-reassuring fetal status [11]. Maeda et al. [12] expected that the medium reduction of FHR acceleration would show the change of fetal outcome from the experience in the central nervous system lesion cases, where the ranking with the FHR acceleration was the same as the behavioral ranking [11]. The duration of the acceleration, standardized by the duration of movement burst was studied with fetal outcome. Actually the sum of acceleration duration in a study period is divided by the sum of fetal movement burst duration, and then the A/B ratio was obtained and compared to fetal outcome. Since the A/B ratios did not significantly differ among active, intermediate and highly active states, the ratio was considered appropriate to study the relation to fetal outcome.

The correlation of A/B ratio to the short term outcome, including 1 and 5 minutes Apgar scores and numerized long term outcome were studied. The A/B ratio of 20 cases of fetal disorders, closely correlated

to the Apgar scores and numerized outcome, thus the detailed outcome will be predicted by the A/B ratio (Figure 9) [12].

### Comments

As oxygen is supplied to the fetus from maternal arterial blood via placenta, fetal  $\text{PaO}_2$  is lower than 50 mm Hg and lower than adult, thus a fetus tends to be hypoxic in various occasion.

Severe fetal hypoxia damages fetal organs including the brain, heart, kidney, peripheral vessels, particularly damages the function of brain cortex and white matter, while medulla oblongata excites by the low  $\text{PaO}_2$ , as discussed before. As the result, neonatal motion, reflex, respiration and circulation are suppressed in the neonatal asphyxia, which damages neonatal outcome. Hypoxic brain damage results into Hypoxic-Ischemic Encephalopathy (HIE) and Periventricular Leukomalacia (PVL), frequently followed by the cerebral palsy. Fetal heart rate monitoring detects fetal hypoxia in its early stage, and the rapid delivery prevents the severe hypoxia followed by various sequelae, i.e. severe neonatal asphyxia almost disappeared, perinatal mortality reduced to 1/3 of simultaneous control of no fetal monitoring [13], and cerebral palsy reduced to 1/3 of historical control [14], after the introduction of fetal monitoring. Neonatal asphyxia, perinatal mortality and cerebral palsy were reduced significantly after full intrapartum monitoring in all births in a general hospital [15,16]. The actocardiogram reduced false positive FHR changes to further precisely confirm ominous hypoxia.

Fetal bradycardia has been a marker of hypoxia as stated before, where sudden continuous bradycardia below 80 bpm, late deceleration with the loss of LTV, severe variable deceleration, and prolonged deceleration are the sign of hypoxia, and indicators for the rapid delivery. Controversy developing and disappearing mechanisms of FHR LTV and acceleration were clarified in this article, to further contribute to the correct diagnosis of fetal hypoxia in non-reassuring fetal status.

### Conclusion

The bradycardia developed if the  $\text{PaO}_2$  decreased in the situation of  $\text{PaO}_2$  below 50 mm Hg, thus fetal bradycardia was diagnosed as hypoxia. Continuous 80 or less bpm bradycardia after acute FHR fall indicated immediate C-section to prevent neurological damages. The Loss of Baseline Variability (LTV) and the loss of acceleration were the sign of fetal hypoxia, where minor movement causes LTV and large movement burst provokes acceleration. The unique triangular shape of accelerations may be related to the presence of FHR delay system to fetal movement. The studies on the LTV and acceleration in FHR will contribute further precise diagnosis of fetal hypoxia.

### References

1. Maeda K (1984) New ultrasonic Doppler fetal actograph and continuous recording of fetal movement. Nihon Sanka Fujinka Gakkai Zasshi 36: 280-288.
2. Umezawa J (1976) Studies on the relation between heart rate and  $\text{PaO}_2$  in hypoxic rabbits: A comparative study for fetal heart rate change during labor. J Japan Soc Obstet Gynecol 28: 1203-1212.
3. Maeda K, Kimura S, Nakano H (1969) Pathophysiology of Fetus. Fukuoka Fukuoka Printing.
4. Terao T, Kawashima Y, Noto H, Inamoto Y, Lin TY, et al. (1984) Neurological control of fetal heart rate in 20 cases of anencephalic fetuses. Am J Obstet Gynecol 149: 201-208.
5. Maeda K, Kimura S, Nakano H (1969) Studies on fetal pathophysiology. Nihon Sanka Fujinka Gakkai Zasshi 21: 877-886.

6. Sameshima H (2011) Fetal hypoxia – physiological approach. J Japan Soc Obstet Gynecol 63: 2054-2059.
7. Maeda K, Nagawawa T (2010) Loss of FHR variability diagnosed by frequency analysis. J Perinat Med 38: 197-201.
8. Takahashi H, Sekijima A, Maeda K (1989) Unique fetal movement pattern in an actocardiogram of an anencephalic fetus. J Japan Chuushikoku Soc Obstet Gynecol 37: 295-298.
9. Ito T, Maeda K, Takahashi H, Nagata N, Nakajima K, et al. (1994) Differentiation between physiologic and pathologic sinusoidal FHR pattern by fetal actocardiogram. J Perinat Med 22: 39-43.
10. Takahashi H (1990) Studies on the cross correlation of fetal heart rate and fetal movement with actocardiogram. Nihon Sanka Fujinka Gakkai Zasshi 42: 443-449.
11. Maeda K, Morokuma S, Yoshida S, Ito T, Pooh RK, et al. (2006) Fetal behavior analyzed by ultrasonic actocardiogram in cases with central nervous system lesions. J Perinat Med 34: 398-403.
12. Maeda K, Iwabe T, Yoshida S, Ito T, Minagawa Y, et al. (2009) Detailed multigrade evaluation of fetal disorders with the quantified actocardiogram. J Perinat Med 37: 392-396.
13. Maeda K (1979) Healthy baby and reduced fetal death by improved obstetric management. In: SMM Karim and Tan KL eds Problems in Perinatology, University of Singapore, Proc 1<sup>st</sup> Asia Oceania Cong Perinatology 526-529.
14. Takeshita K, Ando Y, Ohtani K, Takashima S (1989) Cerebral palsy in Tottori, Japan. Benefits and risks of progress in perinatal medicine. Neuroepidemiology 8: 184-192.
15. Tsuzaki T, Sekijima A, Morishita K, Takeuchi Y, Mizuta M, et al. (1990) The survey on the perinatal variables and the incidence of cerebral palsy for 12 years before and after the application of the fetal monitoring systems. Nihon Sanka Fujinka Gakkai Zasshi 42: 99-105.
16. Teshima N (1993) Non-reactive pattern diagnosed by ultrasonic Doppler actocardiogram and outcome of the fetuses with non-reactive pattern. Nihon Sanka Fujinka Gakkai Zasshi 45: 423-430.