

# 4<sup>th</sup> European Otolaryngology-ENT Surgery Conference & 3<sup>rd</sup> International Conference on **Craniofacial Surgery**

August 15-17, 2019 Rome, Italy

## Auricular schwannoma: A case report

Raid M. AL-Ani and Haidar Khudair Abd  
University of Anbar, College of Medicine, Iraq

Schwannoma is a benign tumour of schwann cells and is seldom to be seen in the auricle. In the literature, very few cases of schwannomas originating in the pinna were reported. In this article, we described a 35-year-old female patient who presented with right painless auricular mass which was treated by excision under general anesthesia. The clinical and histopathologic features, the differential diagnosis, and the treatment of auricular schwannoma are discussed.

**Key words:** auricle, schwannoma, Iraq.

**Introduction:** Schwannomas are slowly growing benign tumour of neuro-ectodermal origin. Schwannomas are well known to arise from schwann cell of the branches of peripheral, cranial or autonomic nerves. They are usually presented as a painless solitary swelling. They are affecting the head and neck in a 25-45%, where the vestibular schwannoma is the commonest. The presentation of head and neck schwannomas depends on their location. Auricle is a rare site of affection by schwannoma (1). The first case of external ear schwannoma was reported in 1977 (2). When we were reviewing the literatures, only five cases of auricular schwannomas were reported in the world (1-5). In the present article we describe a further case of auricular schwannoma.

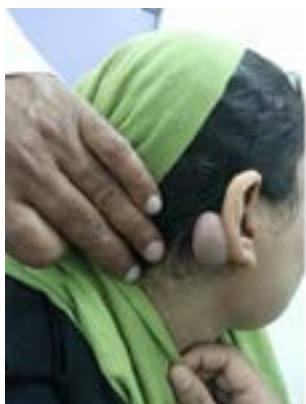

Figure 1: The patient with right auricular mass.

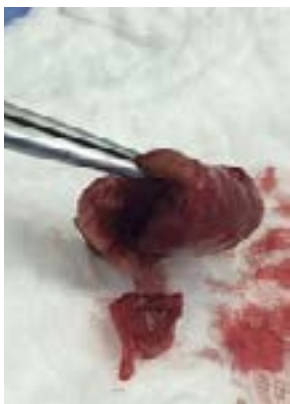

Figure 2: The excised mass contains a blood with in its cavity and has a thick wall.

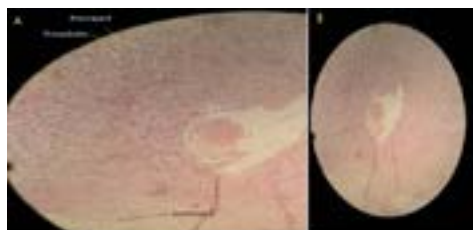


Figure 3: Microscopic section of the tumor showing areas of compact spindle cells arrayed in a palisade pattern known as Antoni type A, Antoni type B, Verocay bodies and an area of hemorrhage within a cavity. (H&E staining, A: 40× and B: 4× magnification power)

Verocay in 1908 was the first who describe the solitary schwannoma and gave it the name of neurinoma; the name schwannoma was assigned by Batsakis in 1974. Schwannoma is also known by other terms, such as neurinoma, neurilemmoma, mioschwannoma, schwannoglioma, etc (6). The first case of auricular schwannoma was reported by Fodor et al in 1977. Following this case only 4 cases were reported in the world (1-5).

# 4<sup>th</sup> European Otolaryngology-ENT Surgery Conference

&

## 3<sup>rd</sup> International Conference on **Craniofacial Surgery**

August 15-17, 2019 Rome, Italy

Schwannoma is a slowly growing, painless, benign, encapsulated tumour arising from schwann cell, so any nerves could be affected by this kind of tumour except the olfactory and optic nerves. Affection of the external ear by schwannoma is extremely rare (7).

The nerve supply to the auricle are derived from auriculotemporal, greater auricular, lesser occipital and partly from facial and vagus nerves (1). Owing to the location of the presenting case, the swelling may have originated from the branch of greater auricular nerve.

Due to its rarity occurrence, auricular shwannoma is rarely put in the differential diagnosis of the swelling of the pinna. The final diagnosis of the schwannoma depends on histopathological evaluation and immunohistochemical study. The treatment of choice for such tumour is by complete surgical excision. The recurrence is rare after complete surgical removal (7).

**Conclusion:** Despite auricular schwannoma is extremely rare tumour, it should be considered in the differential diagnosis of a benign looking swellings of the pinna.

### Biography

Dr. Raid M. Al-Ani , I got MBChB from Kufa College of Medicine in 1989. He is working as a Otolaryngologist since 2000 when I achieved the Fellowship of Iraqi Board for Medical Specializations in Otolaryngology and Head and Neck Surgery. In 2015, he achieved the MRCS from Edinburgh. I got the fellowship of European board in Otolaryngology and Head and Neck Surgery in 2017. In addition to his practice as an Otolaryngologist and an instructor, he received many positions like a chief of department, Assistant Dean for Scientific affairs and Post graduate Studies and others.

raedalani2003@yahoo.com

### Notes: