

## Congenital syphilis and neonatal cholestasis: A case report

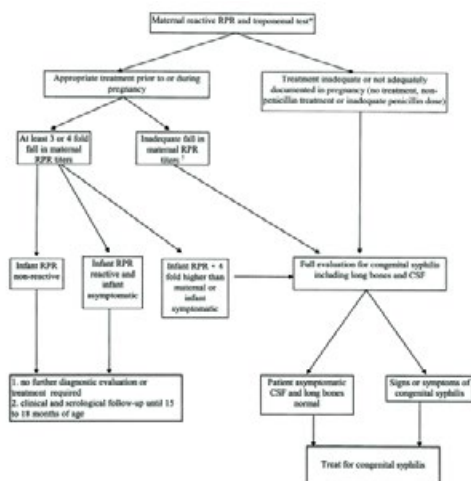
**Silvina Dignani**

Hospital San Felipe, Argentina

Congenital syphilis remains a disease that leads to a significant number of mortality and morbidity in neonates and new-borns, despite the widespread availability of affordable diagnosis and treatment options for the entire population.

**Clinical Case:** A new-born, born at full term after 41 weeks of gestation, with a low weight of 2850 kg and an Apgar score of 9/10, was admitted exhibiting refusal to feed, jaundice, and skin desquamation. The mother of the new-born, aged 20 and having had three pregnancies (G3P2), had recently tested negative for syphilis during the third trimester, including a nonreactive VDRL test. Once admitted to the neonatology unit, the new-born underwent a VDRL test, which revealed values of 256 dilutions, along with thrombocytopenia, elevated liver enzymes and hyperbilirubinemia with a predominance of direct bilirubin. A lumbar puncture was performed, and the cerebrospinal fluid (CSF) analysis showed a VDRL value of 2 dilutions, confirming the diagnosis of neurosyphilis. Treatment with penicillin was administered for duration of 10 days. The subsequent course of the disease was complicated by chronic cholestasis during follow-up.

**Conclusions:** It is crucial to maintain a high level of suspicion for congenital syphilis as a diagnostic approach, even when the mother presents negative test results. This is due to the fact that congenital syphilis remains one of the most prevalent infectious diseases during pregnancy in our environment.



Joint Event

# 36<sup>th</sup> World Pediatrics Conference

37<sup>th</sup> International Conference on

# Neonatology and Perinatology

August 07-08, 2023

Webinar

## Biography

Silvina Dignani is a doctor in the neonatology service at the Hospital San Felipe de San Nicolás, where she trained and continues to work, having rotated at the Jackson Memorial Hospital in Miami. She was a physician following high-risk premature infants and is currently working in the neonatal ICU service.

---

**Received:** April 03, 2023; **Accepted:** April 05, 2023; **Published:** August 07, 2023

---