

# Evaluation of Clinical Safety and Effectiveness of Hyaluronic Acid-based Temporary Dermal Filler Used in Nasolabial Folds

Lúcia Helena Fávaro Arruda<sup>1\*</sup>, Adilson Costa<sup>2</sup>, Elisangela Samartin Pegas Pereira<sup>3</sup>, Margareth de Oliveira Pereira<sup>4</sup> and Elvira Cancio Assumpção<sup>4</sup>

<sup>1</sup>Dermatologist, Head of the Service of Dermatology at the Pontifícia Universidade Católica de Campinas, Campinas (SP), Brazil

<sup>2</sup>Dermatologist, Clinical Director, KOLderma Instituto de Pesquisa Clínica Ltda. Campinas (SP), Brazil

<sup>3</sup>Dermatologist, Coordinator of the outpatient clinics of Phototherapy, Urticaria and Hansen's Disease at the Pontifícia Universidade Católica de Campinas (PUC - Campinas), Campinas (SP), Brazil

<sup>4</sup>Physician, Resident in Dermatology, Service of Dermatology at the Pontifícia Universidade Católica de Campinas (PUC - Campinas), Campinas (SP), Brazil

## Abstract

**Basis:** Hyaluronic acid-based temporary dermal filler are used in the treatment of facial folds and wrinkles.

**Objectives:** Evaluate the effectiveness and safety of Rennova®, a hyaluronic acid-based filler used in nasolabial folds.

**Methods:** An open label, single-center, phase IV, prospective, observational clinical study, with duration of 360 days, totaling 11 visits. The study included 30 female volunteers, between 30 and 60 years of age, presenting nasolabial folds classified as 3 and 4 according to the Wrinkle Severity Rating Scale and skin phototypes I to V, according to the classification of Fitzpatrick. The effectiveness was subjectively evaluated using the wrinkle severity scale and the Global Aesthetic Improvement Scale and objectively analyzed using photographs and biopsies. The volunteers gave their opinions about the procedure and results in a questionnaire. The safety was evaluated by observing adverse events; pain, discomfort and local sensitivity; tolerability and biopsies.

**Results:** In the beginning of the study, 76% of the volunteers presented moderate wrinkles and 24% severity. At the end, 8% presented severe, 56% moderate and 36% mild wrinkles. The adverse events with positive causal nexus were: local erythema/edema, ecchymosis, hematoma and local pain. They presented mild to moderate intensity, short to medium duration.

**Conclusions:** In relation to the wrinkle severity rating scale and global aesthetic improvement scale, the results were satisfactory ( $p < 0.05$ ). The adverse events with positive causal nexus were temporary and the biopsy did not show any inflammatory process, which demonstrates the product safety.

**Keywords:** Hyaluronic acid; Face; Aging

## Introduction

The aging process, as well as the measures against it, has been increasingly studied, due to the constant and current concern about a better and healthier aspect [1-4]. Facial aging affects not only the skin, but also the subcutaneous tissue and bones. The fat distribution is altered, promoting a facial volume loss [4]. Bone and cartilage remodeling is part of this process, as well as the gravitational force [4]. With the natural process of aging, the endogenous hyaluronic acid is reduced, making the skin less hydrated and, consequently, less elastic [5,6]. All these factors, as well as the photodamage, lead to wrinkles and folds on the face [4].

The hyaluronic acid is a polysaccharide, component of the extracellular matrix, which has the same chemical structure in all species and tissues [4,7-9]. In the skin, it is located among the collagen fibers [6]. It has a hydrophilic capability promoting skin hydration and contributing to skin turgidity [4-7].

For this reason, the hyaluronic acid is useful as an option for the treatment of wrinkles, lines and scars [10,11]. The synthetic improvement of hyaluronic acid by products in the form of gel intends to provide longer results of the filler, considering that, if used in the natural form as found in tissues, it would be quickly degraded in the skin [6,7]. Synthetically, it can be obtained through the bacterial fermentation process or taken from live tissues [6,7]. The hyaluronic acid-based filler presents low risk of allergic reactions and does not require any sensitivity test before the application [5,8,12].

Today, fillers, in particular the hyaluronic acid-based products, constitute a non-invasive and effective option for the treatment of facial soft tissue deformities [11]. When a new product is launched, clinical studies are required to evaluate its safety and effectiveness [1,10].

## Materials and Methods

An open label, single-center, phase IV, prospective, observational clinical study was conducted, whose primary objective was to evaluate the effectiveness and safety of a hyaluronic acid-based filler in the treatment of nasolabial folds. Before this study was conducted, it was approved by the Research Ethics Committee, under the number (CAAE 04450000142-10) and the procedures were performed only after the volunteers read, agreed and signed the Informed Consent Term.

The volunteers were recruited from the database of KOLderma Instituto de Pesquisa Clínica Ltda.

## Inclusion and exclusion criteria

The study included 30 female volunteers between 30 and 60 years old, with wrinkles of scores 3 and 4, according to the wrinkle severity rating scale, phototypes I to V, healthy skin in the facial area and free

**\*Corresponding author:** Lúcia Helena Fávaro Arruda, Dermatologist, Head of the Service of Dermatology at the Pontifícia Universidade Católica de Campinas, Campinas (SP), KOLderma Instituto de Pesquisa Clínica Ltda, Rua Doutor Delfino Cintra, 584 - Centro, 13013-055 - Campinas - São Paulo - Brazil, Email: [luciarruda@hotmail.com](mailto:luciarruda@hotmail.com)

**Received** April 24, 2013; **Accepted** November 09, 2013; **Published** November 16, 2013

**Citation:** Arruda LHF, Costa A, Pereira ESP, de Oliveira Pereira M, Assumpção EC (2013) Evaluation of Clinical Safety and Effectiveness of Hyaluronic Acid-based Temporary Dermal Filler Used in Nasolabial Folds. J Clin Exp Dermatol Res 4: 196. doi: [10.4172/2155-9554.1000196](http://dx.doi.org/10.4172/2155-9554.1000196)

**Copyright:** © 2013 Arruda LHF, et al. This is an open-access article distributed under the terms of the Creative Commons Attribution License, which permits unrestricted use, distribution, and reproduction in any medium, provided the original author and source are credited.

of diseases that could interfere in the cutaneous aging evaluation. The volunteers could not be pregnant, and, if at fertile age, they should use a clinically approved contraceptive method. They could not have history of allergic reaction to facial cosmetic products and/or fillers and could not have been submitted to filling in the nasolabial region in the last 12 months.

The following medications were prohibited seven days before the application: acetylsalicylic acid, vitamin E, Ginkgo Biloba, vasodilators, aminosalicylic acid, non-steroidal anti-inflammatory drugs and antiplatelet drugs and, fifteen days before, topical retinoids.

The exclusion criteria were: history of mental disorders or emotional instability, connective tissue diseases, diabetes mellitus or uncontrolled systemic diseases, immune system degradation, HIV-positive individuals, presence of silicone implant or another non-absorbable substance in the area of product application, cutaneous lesions in the evaluated area, and tendency to keloid formation and/or hypertrophic scars.

### Study plan

In total, the volunteers made 11 visits to the research center. The first visit was 15 days before the procedure, i.e., visit 1 (D15). At visit 2 (D0), the product application was performed. Visits 3, 4, 5, 6, 7, 8, 9 and 10 were 7, 30, 60, 90, 120, 150, 180 and 270 days, respectively, after the filler application, for follow-up. Final visit 11 was 360 days after D0.

At the first visit, the signed Informed Consent Term was obtained, the inclusion and exclusion criteria were analyzed, the demographic data were obtained, the medical history and the use of medication or cosmetic products were verified and the physical examination and pregnancy test were made. On the same day, the subjective and objective evaluation of the wrinkle was made, pictures were taken of the face and nasolabial fold biopsy was made. At all other visits, the exclusion criteria and the medications and cosmetic products used were analyzed, and the physical examination was performed. Biopsy was made at visits 6 and 9. At the second visit (D0), the product was applied and a diary was provided for each volunteer to take notes about the seven days after the application and if any medication was taken in this period. At this moment, notes were made on the ease of product application and tolerability to the procedure. At the third (D7) and following visits, the objective evaluation was made using photographs, as well as a subjective evaluation, based on the wrinkle severity rating scale. The adverse events were questioned and examined. The global improvement evaluation, which was subjectively performed, was made at visit 3 and then repeated at visits 6, 9 and 11, i.e., 90, 180 and 360 days after the procedure. The subjective evaluation of the effectiveness in the volunteer was made at visits 2, 3, 6 and 11.

The filler was applied at D0 by a properly trained and qualified professional, assigned by the main investigator, and who did not participate in the clinical evaluations. The procedure was performed according to labeling studies and guidelines approved by ANVISA (the Brazilian Health Surveillance Agency). A lidocaine-based topical anesthetic cream was used in the application area and asepsis and antisepsis were performed in the region. The volunteer remained in sitting position during the procedure. In case of a nodule after the product application, soft massage was made at the application site to reduce it, preventing vigorous massage that could cause ecchymosis.

The directions provided to the volunteers after the filler application were: use cold compress at the side in the first 24-48 hours; avoid local handling and aggressive movements; do not use prohibited medications

and return within 7 days. If necessary, the physician prescribed the use of analgesics, which was included in the clinical records.

The filler used in this study was Rennova® Fill (Innovapharma - Pirouet House, Union Street, St. Helier, Jersey, JE48ZQ, Jersey, UK), a hyaluronic acid-based sterile gel of non-animal origin, obtained through bacterial biofermentation. It is a reabsorbable, viscoelastic, biocompatible, homogeneous and transparent product. Chemical agent BDDE (1,4-butanediol diglycidyl ether) is used to alter the gel structure, making it more viscous and more resistant to degradation caused by hyaluronidase. The product presentation is in a syringe with 1.0 ml of monofasic crosslinked hyaluronic acid (23 mg/ml).

### Effectiveness evaluation

The product effectiveness was subjectively evaluated through clinical observation, using two scales: the Wrinkle Severity Rating Scale (WSRS) and the Global Aesthetic Improvement Scale (GAIS) the latter used at the visits after the filler application (Tables 1 and 2) [12,13].

In the subjective evaluation regarding the volunteer's perception through the questionnaire, the following parameters were analyzed: 1-homogeneity/texture of own skin: evaluated at visits D0 and D7 using a questionnaire with 5 options of answers: excellent; very good; I liked, but nodules were observed; so-so: nodules bother a little; I didn't like it: the presence of nodules bothers me a lot, 2-degree of satisfaction: evaluated at visits D7 and D90 through yes-no answer of the volunteer; 3-willing to use the product again: evaluated at visits D7 and D360, with the following options: would use it again immediately; within the following six months; in one year; more than one year from now; would not use it again, 4-difference observed at the application area: evaluated 3 months after the application, included yes-no questions, and in case of a 'yes' answer, the volunteer could check the following alterations: volume increase; volume reduction; nodule formations; reduction of nodules, and 5-treatment classification: at the final visit, based on the answers: excellent; very good; I liked it, but I don't know if I'd use it again; I didn't like it, I wouldn't use it again.

The objective evaluation of the product effectiveness was based on pictures taken of the face using digital imaging equipment (Visia®, Canfield Imaging System – Fairfield, USA), which analyzed the wrinkle depth. This equipment has 3 evaluation parameters: count, which computes the number of wrinkles; scoring, which evaluates the wrinkle size, total area and intensity; and improvement percentile, which

Score	Category	Description
1	Absent	Fold not visible; continuous line of skin.
2	Mild	Superficial fold, but visible and with a mild depression.
3	Moderate	Moderately deep fold, less than 1 mm deep.
4	Severe	Very long and deep fold, less than 2 mm deep.
5	Extreme	Long and extremely deep fold, 2 to 4 mm deep, producing an older facial aspect.

Table 1: Wrinkle Severity Rating Scale (WSRS).

Score	Category	Description
1	Extremely better	Excellent result
2	Much better	Clear improvement from the initial aspect, but not completely ideal, a touch would improve the result a little
3	Improved	Clear improvement from the initial aspect, but a touch or retreatment is indicated.
4	Unaltered	No change from the initial aspect.
5	Worse	The aspect is worse than the initial condition.

Table 2: Global Aesthetic Improvement Scale (GAIS).

compares the volunteer to other people of the same age, skin type and gender. The pictures were taken considering the following views: front, 45 degrees to the right and 45 degrees to the left. The objective evaluation was also based on biopsy, made before and after the filler application, to evaluate the presence of filler and its adaptation to the tissue. Three cutaneous biopsies were performed with a #2 punch in the nasolabial region in all volunteers, the first 15 days before the procedure on the right side of the face, the second 3 months after the procedure (at D90) on the left side of the face, and the third 6 months after the application (at D180) on the right side of the face. The following stains were used: Masson's trichrome for collagen fibers, Verhoeff for elastic fibers, Alcian Blue for mucin and HE for filler analysis.

**Safety evaluation:** The safety evaluation was performed using the following parameters: 1-presence of pain/discomfort: evaluated at visits D0 and D7 through the volunteer's yes-no answer; 2-sensitivity at the application site: evaluated at visits D0, D7 and D90 using a questionnaire with 5 options of answers (very sensitive and very painful, very sensitive and slightly painful, no alteration to sensitivity but the site was very painful, sensitive but no pain, normal, not sensitive, not painful); 3-tolerability to filler: in this investigation, it corresponded to the presence of adverse events resulting from the procedure, evaluated at D0 and D7 and classified as excellent (no adverse events), good (easily tolerated adverse events), moderate (events were tolerated and did not lead to interrupted procedure) and bad (the procedure was interrupted); 4-monitoring of adverse events, their severity and relation with the treatment, and 5-biopsy: evaluated the presence any inflammatory process.

Besides these parameters, the physician observed if there was any nodule formation after the procedure and provided the degree of difficulty involving the product application, using a 0-10 scale (0=very easy and 10=very difficult).

## Results

The study started with 30 volunteers and ended with 25. Two volunteers took back their consents after visit D60 and two after visit D90, for personal reasons, and one was excluded from the investigation after D150, due to a femur fracture. The statistical analyses were made in the volunteers that concluded the investigation. The Wilcoxon test was used for quantitative data and the marginal homogeneity test for qualitative data.

In the effectiveness evaluation using the wrinkle severity scale at the visit before the application, 76% of the volunteers presented moderate wrinkles and 24% severe wrinkles. Seven days after the application (D7), 12% of the volunteers presented moderate wrinkles, 64% had mild wrinkles and 24% had no wrinkles. At D360 (360 days after the procedure), 8% of the volunteers presented severe wrinkles, 56% had moderate wrinkles and 36% had mild wrinkles. Figure 1a shows the results of each visit. When comparing each visit to D15, the results were statistically significant, with  $p < 0.05$ .

Also in the subjective clinical evaluation, regarding the global aesthetical improvement of wrinkles, at the visit made seven days after the filler application, 12 volunteers (48%) presented very good improvement, 10 (40%) had good improvement, 3 (12%) had mild improvement and none was classified as unaltered. At the final visit, 2 volunteers (8%) presented wrinkles with very good improvement, 13 (52%) had improvements and 10 (40%) were unaltered ( $p < 0.001$ ). At the final visit, no volunteer had worsened fold depth. Figure 1b shows the results of each visit. When comparing each visit to D7, the results

were statistically significant, with  $p < 0.05$  (D30  $p = 0.046$ ; D90  $p = 0.025$ ; D180  $p = 0.001$ ; D360  $p < 0.001$ ).

Regarding the evaluation made by the volunteer of the skin homogeneity/texture, at the visit of filler application (D0), 28% of the volunteers ( $n = 7$ ) evaluated it as excellent, 64% ( $n = 16$ ) as very good and 8% ( $n = 2$ ) liked it, but they observed the presence of some nodules. Seven days after the filler application, 60% ( $n = 15$ ) classified as excellent, 36% ( $n = 9$ ) as very good and 4% ( $n = 1$ ) liked it, but they observed the presence of some nodules. When comparing visits D0 and D7, the results were statistically significant ( $p = 0.029$ ). Regarding the degree of satisfaction with the treatment, at visit D7, all volunteers were satisfied and at visit D90, 96% of the volunteers were satisfied.

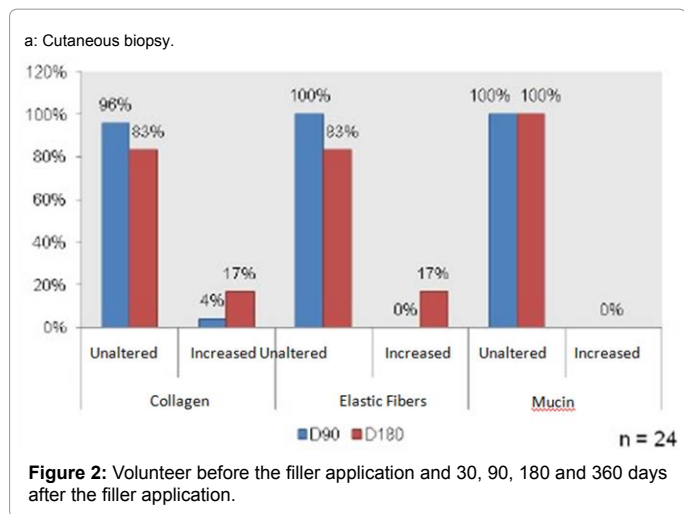
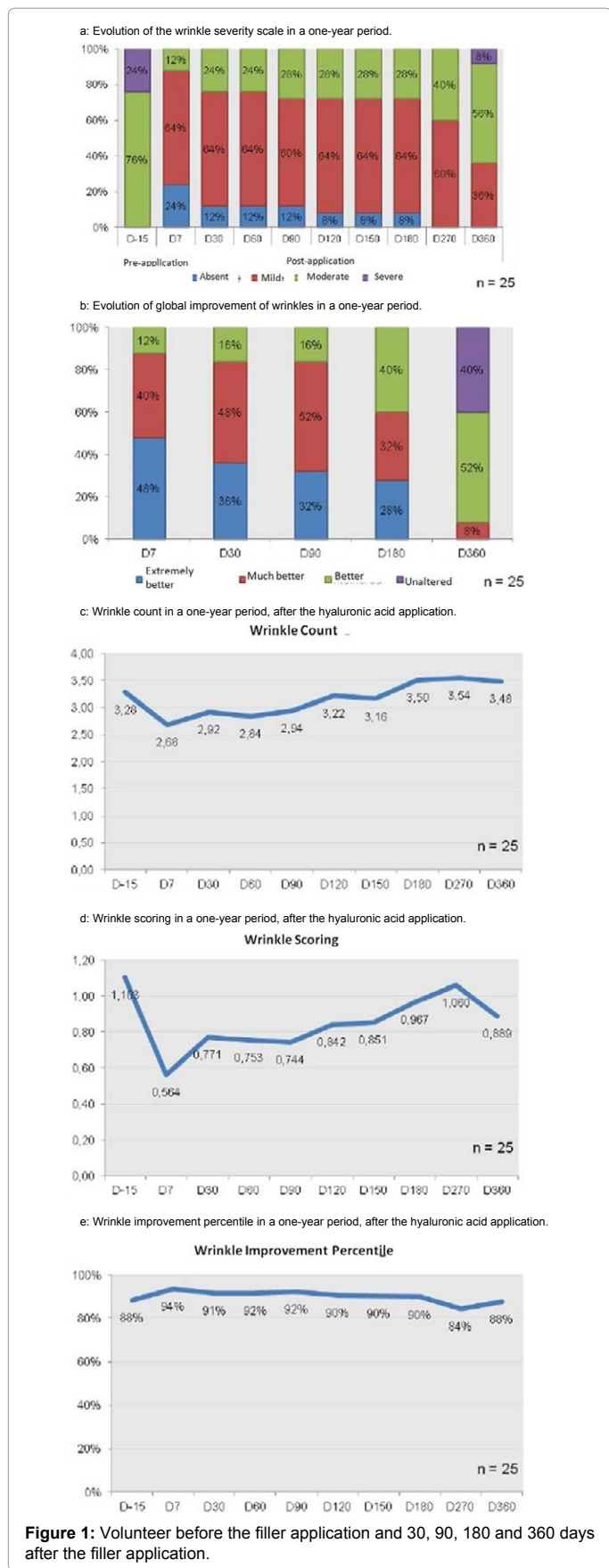
The questionnaire answered by the volunteers 7 and 360 days after the filler application about their inclination to use the product again showed that 44% ( $n = 11$ ) would do the treatment again immediately, 44% ( $n = 11$ ) would do it within the next six months, 8% ( $n = 2$ ) would do it within the next year and 4% ( $n = 1$ ) within more than one year and no volunteer wouldn't do it again. However, at the end of the study, 88% ( $n = 22$ ) would do the treatment again immediately, 4% ( $n = 1$ ) would do it within the next six months and 8% ( $n = 2$ ) wouldn't do it again. When comparing the final visit to D7, the result of  $p = 0.208$  was obtained. Regarding the questionnaire applied at D90 about any difference at the application site, 2 (8%) of them answered volume reduction. At the end of the study, 44% of the volunteers ( $n = 11$ ) classified the treatment as excellent; 28% ( $n = 7$ ) as very good and 28% ( $n = 7$ ) liked it but they didn't know if they would do it again.

Regarding the objective evaluation performed using Visia®, the average count was 3.28 in the beginning of the study and 3.48 at the end of the study. Figure 1c shows the values of average count at each visit. When comparing the values of each visit to the initial visit (D15),  $p \geq 0.05$  were obtained, except for visit D7 ( $p = 0.021$ ). Regarding scoring, the average in the beginning of the study was 1.103 and 0.889 at the end. Figure 1d shows the values of average scoring at each visit. The  $p$  values of each visit, when compared to the initial visit, were statistically significant ( $p < 0.05$ ), except for visit D270 ( $p = 0.313$ ). The average improvement percentile was 88.4% in the beginning and 87.6% at the end of the study. Figure 1e shows the values of average percentile. Figures 1 and 2 show pictures of two volunteers before and after the filler application. The  $p$  values obtained when comparing each visit to the initial visit were statistically significant ( $p < 0.05$ ), except for the final visit ( $p = 0.329$ ).

Also in the objective evaluation, the biopsy showed at visit D90, regarding collagen levels, that 96% of the volunteers had unaltered collagen level and 4% of them had increased collagen level. The study used  $n = 24$ , as the material was insufficient in one sample, and then not used in the analysis. Regarding the elastic fibers and mucin, at D90, 100% of the volunteers showed no alteration. At visit D180, regarding collagen levels and elastic fibers, 83% of the volunteers did not present alterations and 17% presented increased collagen level and elastic fibers. All volunteers did not present alteration in mucin at these visits. Reduced collagen, elastic fiber or mucin was not observed at any visit. Figure 2a shows the comparing of values of visit D90 to the values of visit D180; for collagen level,  $p = 0.250$  was obtained and for elastic fibers,  $p = 0.125$ , that is, no statistically significant values. The filler was not viewed in the biopsies.

In the safety evaluation, the results showed that most volunteers (92%) reported pain or discomfort during the procedure. One week later, only 32% still reported that. Regarding the sensitivity on the





application day, 4% answered that it was very sensitive and painful; 12% said that it was very sensitive and slightly painful; 4% said the site was very painful, but not sensitive; 32% said that it was sensitive, but not painful and 48% said that it was normal (neither sensitive nor painful). At D7, 12% felt that the site was very painful, but not sensitive; 20% said that it was sensitive, but not painful; and 68% said that it was normal. At D90, 100% of the volunteers said that the site was normal.

Regarding tolerability, on the application day, 64% of the volunteers classified it as good, 16% as excellent and 20% as acceptable. One week after the application, the percentage of excellent tolerability was 56%, the percentage of good tolerability was 32% and the acceptable tolerability to 12%. No volunteer reported poor tolerability.

Regarding adverse events, considering that some volunteers had more than one event, 14 occurrences were reported by total 10 volunteers. Some events had positive causal nexus and others no. The events not related with the procedure were: labial herpes (n=1), laryngitis (n=1), flu (n=2), TMJ inflammation (n=1), conjunctivitis (n=1), rhinitis (n=1) and supraventricular tachycardia (n=1). Herpes labial occurred at D150, a long time after the filler application, and for this reason, it was classified as not related to the procedure. The events of positive causal nexus were: erythema/edema at the application site (n=1), ecchymosis (n=2), hematoma (n=2), local pain (n=1), all of mild to moderate intensity and short to medium duration. All adverse events were completely resolved.

The biopsy showed neither formation of granulomas nor inflammatory process.

According to the medical evaluation on the filler application day, only one volunteer presented nodule formation. The evaluation for ease of product application showed average score of 5.2.

## Discussion

Facial aging treatment techniques currently recommend skin surface therapy and the revolumizing of soft tissues. Filling substances are then used to correct wrinkles, folds and for replacing facial volumes lost in the physiological process of aging. Hyaluronic acid is the most used substance for such due to its physical-chemical properties [14].

Several factors influence the filling product: hyaluronic acid concentration, percent and degree of cross linking, capacity to absorb water, among others. This enables each product to present specific

characteristics regarding durability, tissue filling volume; ease of application and also in relation to adverse side effects [15].

Although the procedure is well-tolerated by the patient, some adverse effects can occur in facial filling. The following can be observed in the application site: bruising, erythema, edema, nodules, which may be technical, or product dependent, and pain or discomfort can also be observed, in accordance with patient sensitivity. These effects are generally short in duration and well-tolerated by patients, late reactions, such as hypersensitivity are very rare.

When evaluating the presence of adverse events in this study, the Rennova® filler was considered safe for correcting nasolabial sulci. Most of the volunteers reported only discomfort or minimum pain during the procedure, and this was reduced with asked 7 days after the application. With the observation of the questionnaire applied during scheduled return visits, high tolerability to the procedure is evident, as is a low occurrence of other adverse events. Only erythema and edema could be observed, which the case is in any injectable procedure. During biopsy, no formations of granulomas or any inflammatory process of any importance were observed [16,17].

In relation to the evaluation of efficacy, this study shows that the improvements in treated areas are maintained up to 360 days after applying Rennova® filler. When analyzing the subjective aspects, improvement is observed in the clinical evaluation of wrinkle severity, considering 76% of moderate degree wrinkles and 24% serious compared to 56% of moderate degree wrinkles and 8% serious (p-value=0.01) after the end of the study. This observed reduction demonstrates a significant benefit 360 days after the filling. It is important to underscore that volunteers with light wrinkles were not included in the study, however 36% of the volunteers with this classification were observed at the end of the study, demonstrating the clinical efficacy of Rennova®.

On an overall esthetic improvement scale, 7 days after filling 100% of the volunteers presented an improvement, which remains up to 180 days after filling. At the end of the study, just 10 volunteers (40%) presented an unaltered result; however, the rest still presented improvement when compared to the beginning of the study, that is, 360 days after the procedure (p-value<0.01).

The volunteers did not report any nodules, and the degree of satisfaction, which was 100% 7 days after the procedure, remained at 96% at the end of the study. In the willingness to redo treatment question, 88% replied yes after the end of the study.

In the objective parameters, when Visia® equipment was used, the score best evaluated the results of this study, because this parameter precisely analyzes wrinkle depth, size and intensity. When comparing the initial visit (D-15) to after-treatment visits, average values found are seen to be smaller, and they stayed that way until D-360, with a statistical significance of less than 0.05. This indicates that in this study, the analyzed product made the wrinkle significantly less deep up to 360 days after treatment.

The percentile analyzed the volunteer's skin in comparison to others with the same age, gender and characteristics. An increase in percentile was considered to indicate an improvement. In this study, the percentile was greater than D-15 until D-180, indicating clinical improvement up to 180 days after treatment in a statistically significant manner, with values of p<0.05 compared to the beginning of the study. When analyzing the percentile at D-270, there was a drop in absolute value; however, the persistence of the clinical benefit (p=0.028) was

observed. The D-360 percentile was under the initial percentile, but statistically insignificant (p=0.329), which made it possible to affirm the product did not increase or decrease the percentile, and is not a relevant parameter for analyzing the result.

In relation to the biopsy, despite the increase in collagen in some volunteers, there was no statistical significance regarding alterations in collagen fibers, mucin and in the collagen itself. The increase in collagen detected may have occurred due to the local stimulus of fibroblasts, caused by the filler.

Narins' study demonstrates the greatest durability in facial filling results compared to other materials, in the case of bovine collagen, and it is also easy to waive prior allergy tests. This is also observed in the studies by Monteiro and Parada [18].

Several recent studies, such as those by Arsiwala and Talarico demonstrate efficacy and safety in the use of hyaluronic acid fillers, which corroborates with this study. The exception is the studies oscillate from 3 to 9 months after the procedure and this study proves the safety and effectiveness of Rennova® up to 360 days after filling, as observed in the Salles et al. study [19].

In general, esthetic results with hyaluronic acid base fillers last 6 to 9 months. There are reports of their lasting up to 12 months, depending on filler characteristics. As observed in the aforementioned Salles et al. study with an objective parameter. Analyzing these data and cited studies, it is possible to affirm that the Rennova® filler presented an effect and safety duration compatible with other temporary fillers with a hyaluronic acid base. This filler proved effective and safe for filling nasolabial sulci with the further possibility of presenting improvements in some patients even 360 days after application.

## Conclusion

The availability of hyaluronic acid-based fillers has increased, due to the current tendency towards treatments with less invasive methods and that present less adverse reactions. Then, for being biocompatible, with few adverse effects, reversible and functional, hyaluronic acid-based fillers have been widely used. Although it is a safe product, whenever new filler is launched, it is important to have clinical studies conducted in the target population, to evaluate its effectiveness and, especially, its safety. This study demonstrated that RENNOVA® presented good clinical effectiveness and safety during the evaluated period. The search for more durable products, with few adverse effects, remains.

## Financing Source

Clinical investigation sponsored by INNOVAPHARMA.

## Conflict of Interest

Clinical investigation sponsored by the company mentioned above.

## References

1. Lowe NJ, Maxwell CA, Patnaik R (2005) Adverse reactions to dermal fillers: review. *Dermatol Surg* 31: 1616-1625.
2. Montagner S, Costa A (2009) [Molecular basis of photoaging]. *An Bras Dermatol* 84: 263-269.
3. Smith KC (2008) Reversible vs. nonreversible fillers in facial aesthetics: concerns and considerations. *Dermatol Online J* 14: 3.
4. John HE, Price RD (2009) Perspectives in the selection of hyaluronic acid fillers for facial wrinkles and aging skin. *Patient Prefer Adherence* 3: 225-230.
5. Bogdan Allemann I, Baumann L (2008) Hyaluronic acid gel (Juvéderm)

- preparations in the treatment of facial wrinkles and folds. *Clin Interv Aging* 3: 629-634.
6. Matarasso SL, Sadick NS (2011) Preenchimento Cutaneo. In: Bologna JL, Jorizzo JL, Rapini PR, Dermatologia. (2ndedn.) Elsevier, São Paulo, Brazil 2369-2379
  7. Alves R, Brandao PM (2004) Acido Hialurônico. In: Kede MPV, Sabatovich O, Dermatologia Estética, Atheneu, São Paulo, Brazil 501-505.
  8. Rao J, Chi GC, Goldman MP (2005) Clinical comparison between two hyaluronic acid-derived fillers in the treatment of nasolabial folds: hylaform versus restylane. *Dermatol Surg* 31: 1587-1590.
  9. Vedamurthy M (2004) Soft tissue augmentation--use of hyaluronic acid as dermal filler. *Indian J Dermatol Venereol Leprol* 70: 383-387.
  10. Talarico S, Hassun KM, Monteiro EO, Parada MOB, Buratini LB, et al. (2010) Avaliação da segurança e eficácia de novo preenchedor à base de ácido hialurônico no tratamento dos sulcos nasolabiais e contorno dos lábios. *Surg Cosmet Dermatol* 2: 83-86.
  11. Brandt FS, Cazzaniga A (2008) Hyaluronic acid gel fillers in the management of facial aging. *Clin Interv Aging* 3: 153-159.
  12. Narins RS, Brandt F, Leyden J, Lorenc ZP, Rubin M, et al. (2003) A randomized, double-blind, multicenter comparison of the efficacy and tolerability of Restylane versus Zylplast for the correction of nasolabial folds. *Dermatol Surg* 29: 588-595.
  13. Day DJ, Littler CM, Swift RW, Gottlieb S (2004) The wrinkle severity rating scale: a validation study. *Am J Clin Dermatol* 5: 49-52.
  14. Newman J (2009) Review of soft tissue augmentation in the face. *Clin Cosmet Investig Dermatol* 2: 141-150.
  15. Van Dyke S, Hays GP, Caglia AE, Caglia M (2010) Severe Acute Local Reactions to a Hyaluronic Acid-derived Dermal Filler. *J Clin Aesthet Dermatol* 3: 32-35.
  16. Arsiwala SZ (2010) Safety and persistence of non-animal stabilized hyaluronic acid fillers for nasolabial folds correction in 30 Indian patients. *J Cutan Aesthet Surg* 3: 156-161.
  17. Wang F, Garza LA, Kang S, Varani J, Orringer JS, et al. (2007) In vivo stimulation of de novo collagen production caused by cross-linked hyaluronic acid dermal filler injections in photodamaged human skin. *Arch Dermatol* 143: 155-163.
  18. Monteiro EO, Parada MOB (2010) Preenchimentos faciais – parte um. *RBM* 67: 06-14.
  19. Alessandra Grassi Salles, Adelina Fátima do Nascimento Remigio, Valeria Berton Liguori Zacchi, Osmar Cássio Saito, Marcus Castro Ferreira (2011) Avaliação clínica e da espessura cutânea um ano após preenchimento de ácido hialurônico. *Rev Bras Cir Plast* 26: 66-69.

**Citation:** Arruda LHF, Costa A, Pereira ESP, de Oliveira Pereira M, Assumpção EC (2013) Evaluation of Clinical Safety and Effectiveness of Hyaluronic Acid-based Temporary Dermal Filler Used in Nasolabial Folds. *J Clin Exp Dermatol Res* 4: 196. doi:[10.4172/2155-9554.1000196](https://doi.org/10.4172/2155-9554.1000196)

### Submit your next manuscript and get advantages of OMICS Group submissions

#### Unique features:

- User friendly/feasible website-translation of your paper to 50 world's leading languages
- Audio Version of published paper
- Digital articles to share and explore

#### Special features:

- 300 Open Access Journals
- 25,000 editorial team
- 21 days rapid review process
- Quality and quick editorial, review and publication processing
- Indexing at PubMed (partial), Scopus, EBSCO, Index Copernicus and Google Scholar etc
- Sharing Option: Social Networking Enabled
- Authors, Reviewers and Editors rewarded with online Scientific Credits
- Better discount for your subsequent articles

Submit your manuscript at: [www.editorialmanager.com/clinicalgroup](http://www.editorialmanager.com/clinicalgroup)