

Case Report

Open Access

IgG4-Related Aortitis of the Ascending Aorta in a Patient Undergoing Emergent Coronary Artery Bypass Graft: A Challenging Disease

Benassi Filippo^{1*}, Molardi Alberto¹, Nicolini Francesco¹, Cocconcetti Flavio¹, Corradi Domenico², Cobelli Rocco³, Bozzetti Francesca³ and Gherli Tiziano¹

¹Cardio-Nephro-Pulmonary Department, Cardiac Surgery Unit, University of Parma, Parma, Italy

²Department of Biomedical, Biotechnological, and Translational Sciences (S.Bi.Bi.T.), Unit of Pathology, University of Parma, Parma, Italy

³Department of Radiology, University of Parma, Italy

Abstract

Immunoglobulin G4 (IgG4)-related sclerosing disease in the cardiovascular system is a recently proposed disease entity, which is still unfamiliar to most clinicians. We present a case of IgG4-related periaortitis of the ascending aorta undergoing emergent surgical revascularization. During the operation we found an extremely thick and stiff aorta that led us to an incomplete surgical revascularization due to the impossibility of cross-clamp the vessel. We performed several biopsies of the aorta that confirmed the diagnosis of IgG-4 related aortitis. Before discharging the patients we perform a CT scan in order to better evaluate the real extension of the aortitis. The patient was discharged in good clinical condition and the revascularization was completed three month later performing a percutaneous transluminal angioplasty on right and circumflex coronary artery. IgG4-related periaortitis needs to be considered in the differential diagnosis in a patient with thickened aortic wall.

Keywords: Coronary artery bypass; Aortitis; IgG4

Introduction

Immunoglobulin G4-related systemic disease (IgG4-RSD) is a recently defined emerging entity characterized by a diffuse or mass forming inflammatory reaction rich in IgG4-positive plasma cells associated with fibro sclerosis and obliterative phlebitis. IgG4-RSD usually affects middle aged end elderly patients, with a male predominance. It is associated with an elevated serum titer of IgG4, which acts as a marker for this recently characterized entity. The prototype is IgG4-related sclerosing pancreatitis or autoimmune pancreatitis. Other common sites of involvement are hepatobiliary tract, salivary gland, orbit, and lymph node, however practically any organ can be involved, including upper aerodigestive tract, lung aorta, mediastinum, retroperitoneum, soft tissue, skin, central nervous system, breast, kidney and prostate [1]. Disease progression with involvement of multiple organ-sites may be encountered in a subset of cases and may follow a relapsing-remitting course. The cardiovascular system may be involved as a target organ of multifocal fibrosclerosis, which may manifest as idiopathic retroperitoneal fibrosis, inflammatory aortic aneurysm, inflammatory periartitis, and inflammatory pericarditis [2]. IgG4-RSD in the cardiovascular system, however, had not been reported until 2008 when Kasashima and associates described IgG4-related inflammatory abdominal aortic aneurysm (IAAA). Subsequently, they reported more than half of the cases of IAAA were linked to the periaortic counterpart of IgG4-RSD. There have been only a few case reports of IgG4-related periaortitis of the thoracic aorta [3]. We herein describe a case of a patient undergoing coronary bypass graft surgery with an incidental finding of severe aortitis without aortic dilatation which has not allowed the complete surgical myocardial revascularization. The intraoperative biopsy of the aortic wall confirmed the presence of a IgG4-RSD.

Case Report

A 64 years-old female patient was admitted to a peripheral cardiology unit on August 2012 due to dyspnea and chest pain. The patient suffered from years of high blood pressure and dyslipidemia. In addition, was present an history of an idiopathic retroperitoneal

fibrosis diagnosed by a CT-scan five years and two previous episodes of extrinsic obstruction of both ureters treated by placement of bilateral ureteral stents. The electrocardiogram showed diffuse myocardial ischemia with ST downsloping and an increase in cardiac markers. Laboratory tests showed normal white blood cells with an high erythrocyte sedimentation rate (ESR, 65 mm/hr). PCR was not tested because is not a routine exame in emergency setting. A trans-thoracic echocardiogram was performed showing mild reduction of ejection fraction, showing no other significant findings about valves or thoracic aorta.

The patient underwent urgent coronary catheterization revealing a severe three-vessel coronary artery disease and transferred to our cardiac surgery unit. The clinical features of the patient worsened, with progressive hemodynamic instability (functional class CCS 4 with refractoriness to maximal medical therapy) so we were forced to submit the patient to an emergency surgery without having the chance to investigate further the great vessels conditions.

The operation began in a standard fashion way, but soon after opening the pericardium, the ascending aortic wall appeared extremely thickened, stiff and of gray color. The thickness of the aorta measured with an intraoperative trans-esophageal echocardiography was of about 5 mm. The extreme stiffness and thickness of the aortic wall did not allow us to cross clamp the aorta. For these reason we were unable to carry out a complete surgical myocardial revascularization. We

***Corresponding author:** Dr. Benassi Filippo, Cardio-Nephro-Pulmonary Department, Cardiac Surgery Unit, University of Parma, Via Gramsci 14 – 43126, Parma, Italy, Tel: +39 (0)521 703270; E-mail: filippo.benassi@libero.it

Received August 25, 2013; **Accepted** October 14, 2013; **Published** October 24, 2013

Citation: Benassi F, Molardi A, Nicolini F, Cocconcetti F, Corradi D, et al. (2013) IgG4-Related Aortitis of the Ascending Aorta in a Patient Undergoing Emergent Coronary Artery Bypass Graft: A Challenging Disease. *J Genet Syndr Gene Ther* 4: 188. doi:[10.4172/2157-7412.1000188](http://dx.doi.org/10.4172/2157-7412.1000188)

Copyright: © 2013 Benassi F, et al. This is an open-access article distributed under the terms of the Creative Commons Attribution License, which permits unrestricted use, distribution, and reproduction in any medium, provided the original author and source are credited.

performed an off-pump aorto-coronary bypass graft, anastomosing the internal mammary artery to the left anterior descending branch. Several aortic adventitia biopsies were also performed in order to make diagnosis. The postoperative period was uneventful.

Complete revascularization was achieved three month later performing a percutaneous transluminal angioplasty on right and circumflex coronary artery.

The biopsy showed an aortic adventitia which had largely been replaced by hyaline fibrous tissue composed of wide bands of collagen permeated by an inflammatory infiltrate in perivascular and diffuse patterns. Sometimes, these bands of collagen appear arranged concentrically around the lesional small blood vessels. Interestingly, the immunohistochemical analysis demonstrated a significant amount of IgG4-positive plasma cells (Figure 1 and 2). The above pathological picture was morphologically in keeping with a chronic peri-aortitis in the setting of IgG4-related disease.

Based on this report, the patient underwent a thoracoabdominal aorta angio-CT in order to evaluate the real extent of the disease that showed a maximum thickening of ascending and abdominal aorta respectively of 9 mm and 16 mm (Figure 3 and 4). The patient started low-dose corticosteroids therapy as treatment for the autoimmune disorder [4]. The patient was discharged on the tenth post-operative day in good clinical condition. Subsequently she was referred to regional center for auto-immune disorders after a short rehabilitation period. The patient continued in doing well and after one year from cardiac intervention we repeated an angio-TC showing a reduction of periaortic fibrosis (Figure 5).

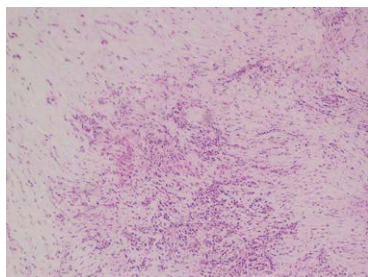


Figure 1: Medium-power view of the chronic periaortitis showing an aortic adventitia extensively replaced by a scar-like fibrous tissue and partially occupied by a chronic inflammatory infiltrate organized in perivascular and diffuse patterns. Hmatoxylin-eosin staining. Original magnification $\times 10$.

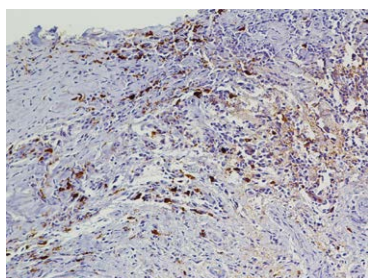


Figure 2: The immunohistochemical analysis demonstrate a significant fraction of plasma cells that are positive for an anti-IgG4 antibody. Original magnification $\times 20$.

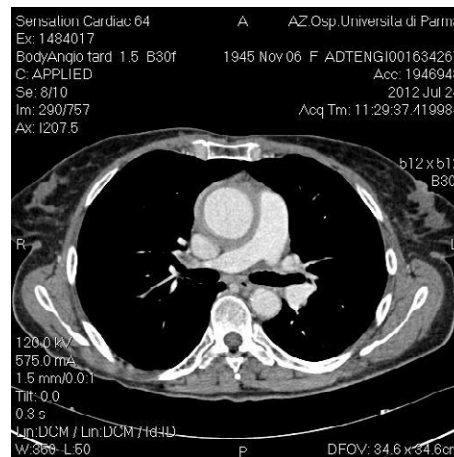


Figure 3: Computed tomography demonstrates increased wall thickness of the ascending aorta. Maximal ascending wall thickness (WTmax) was measured at 9 mm.

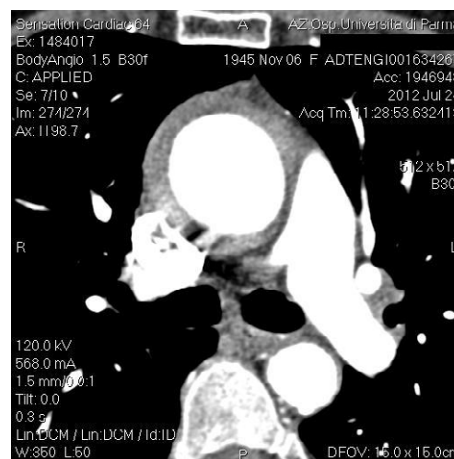

Figure 4: Computed tomography demonstrates increased wall thickness of the ascending aorta. Maximal ascending wall thickness (WTmax) was measured at 9 mm.

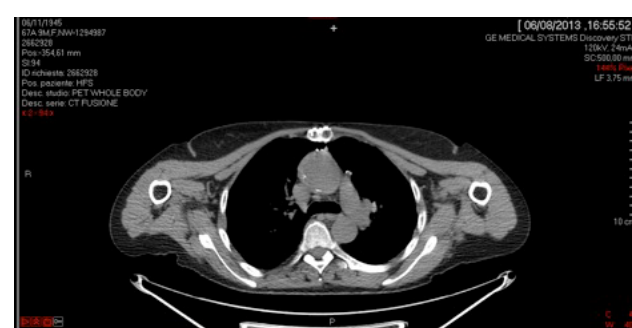


Figure 5: Computed tomography after one year follow-up showing reduction of periaortitis fibrosis.

Discussion

Inflammatory aortic aneurysm and idiopathic retroperitoneal fibrosis may be grouped together under the umbrella of chronic periaortitis according to their common histopathological features

[5]. Chronic periaortitis (CP) is a rare clinico-pathological entity characterised by the presence of a retroperitoneal fibro-inflammatory mass which usually surrounds the abdominal aorta and the iliac arteries and may envelop adjacent structures such as the ureters and the inferior vena cava [6]. The term "chronic" derives from the histological appearance of CP: a chronic inflammatory infiltrate consisting mainly of lymphocytes, monocytes, plasma cells and sparse eosinophils is usually found in a background of abundant fibrous tissue and fibroblasts. CP involves three main disease entities, namely idiopathic retroperitoneal fibrosis (IRF), inflammatory aneurysms of the abdominal aorta (IAAAs) and perianeurysmal retroperitoneal fibrosis (PRF). In IRF the aortic diameter is normal, and the surrounding retroperitoneal mass may or may not encase the neighbouring structures. In IAAAs and PRF the aorta shows aneurysmal dilatation, and while in the former the periaortic mass does not involve the adjacent structures, in the latter it causes obstructive complications. PRF may thus represent an advanced stage of IAAA. IAAAs and PRF may be referred to as "aneurysmal CP", whereas IRF may be referred to as "non-aneurysmal CP" [4]. Idiopathic retroperitoneal fibrosis, which is also called Ormond's disease [7], was first described by Albarran et al. in 1905 [7-9]. Retroperitoneal fibrosis may be caused by certain drugs, infections, radiotherapy, surgery, and malignancies; however, more than two-thirds of cases are idiopathic in nature. CP is a rare disorder; although there are no conclusive data concerning its epidemiologic characteristics, a recent study on IRF has demonstrated that its incidence and prevalence are 1/1,000,000 person-year and 1.38 cases/ 100,000 inhabitants. Recent studies have demonstrated that genetic factors may play a role in the pathogenesis of the disease. In a case-control study involving patients with IAAAs and healthy controls, the prevalence of the HLA alleles HLA-DRB1*15 and HLA-DRB1*0404 was found to be significantly higher in the IAAA group. The strikingly significant association with HLA-DRB1*03, an allele linked to many autoimmune conditions, further supports the hypothesis that CP may belong to the family of autoimmune diseases [4,10]. Diagnosis of this disease relies primarily on imaging studies, most frequently CT scanning; the disease is characterized by a fibroinflammatory soft tissue mass surrounding the aorta and/or adjacent tissues. Biopsy of the retroperitoneal mass is currently less frequently performed due to the potential risks; in some cases, however, the possibility of an alternative condition, such as malignancy or infection, should be ruled out histopathologically [11].

Inflammatory abdominal aortic aneurysm is a pathological condition that is estimated to account for less than 10% of all cases of abdominal aortic aneurysm. Inflammatory abdominal aortic aneurysm may be termed the 'aneurysmal form of chronic periaortitis' and, when accompanied by ureteric blockade, 'perianeurysmal retroperitoneal fibrosis', although these names have not been frequently used to date.

Although chronic periaortitis had been considered to be a relatively rare disorder, its presence has been increasingly recognized with the advent of non-invasive imaging modalities such as computed tomography (CT) scanning. Chronic periaortitis is commonly symptomatic at presentation with the most frequent symptom being abdominal, back or lumbar pain, which is often dull but, in patients with ureteral involvement, also colic-like. Pain is usually associated with constitutional symptoms, such as malaise, anorexia and fever. Other presenting signs or symptoms include leg edema, varicocele, testicular pain, claudication, dysuria, frequency and, in cases with advanced bilateral ureteral stenosis, oligo-anuria. Thrombophlebitis or deep vein thrombosis may also occur. Physical examination is usually unrevealing: diffuse abdominal tenderness and a palpable mass can be found, and in aneurysmal CP a peri-umbilical bruit is usually heard.

Abnormalities in inflammatory markers, such as elevated C-reactive protein and enhanced erythrocyte sedimentation rate, are common laboratory findings, and antinuclear antigen may be detected in about half of all cases [4,12].

The treatment of CP is largely based on the use of corticosteroids. In most patients, they induce remission of the clinical symptoms, normalisation of the acute-phase reactant levels, reduction in size of the retroperitoneal mass and also resolution of the obstructive complications. Given the lack of prospective randomised trials, the best dose, administration route, and duration of steroid therapy have not yet been established. Corticosteroids have significant side effects, which sometimes limit their prolonged use. Corticosteroids have significant side effects, which sometimes limit their prolonged use. The combination of steroids and immunosuppressants (e.g. azathioprine, cyclophosphamide, methotrexate) has recently been reported to yield favourable results in CP patients. It is unknown, however, whether these associations are more effective than steroids alone and if any of these drugs can be used as a steroid-sparing agent. Finally, tamoxifen has also been proposed as a potential treatment for CP; a number of case reports have described its beneficial effects in CP patients and a recent study on a relatively large cohort of CP patients showed that it can be effective in up to 75% of the cases, with very low toxicity. In the aneurysmal forms of CP, the treatment may vary based on the extent of aneurysmal dilatation. When the aortic diameter exceeds 5 cm, surgical aneurysmectomy or endovascular aneurysm repair are usually performed; these procedures are usually followed by regression of peri-aortic fibrosis, although in some cases the tissue may persist or even progress. If there are no indications for aneurysm repair but the patient is symptomatic or suffers from obstructive complications, steroid therapy may be indicated. As is the case in many inflammatory and autoimmune diseases, CP also has a chronic-relapsing course: the frequency of relapses may depend on the treatment approach, as they occur in 10% to 50% of patients treated with surgery alone and in about 10% when combined immunosuppressive and surgical therapies are used [4,13]. In the presented case we were forced to perform a single bypass graft due to the stiffness of thoracic aorta because the patient needed urgent operation. For this reason we could perform only a fast echocardiogram exam without careful examination of the thoracic aorta. A careful retrospective review of symptoms and medical history, accompanied to CT findings could have allowed us to plan the operation and avoid an "incomplete" operation. This is the first report, at our knowledge, of successful coronary bypass graft surgery in patient with IgG-4 periaortitis in an emergency setting. The case has an important clinical implication because IgG4-related periaortitis can also mimic an intramural hematoma at CT scan. This needs to be considered in the differential diagnosis in patients with increased wall thickness in order to avoid unnecessary/incomplete surgical interventions. Additionally, prospective clinical studies are needed to establish the most effective and safest therapeutic approaches as well as the best strategies for a thorough follow-up of patients.

References

1. Inoue D, Zen Y, Abo H, Gabata T, Demachi H, et al. (2011) Immunoglobulin G4-related periaortitis and periarteritis: CT findings in 17 patients. *Radiology* 261: 625-633.
2. Ishizaka N, Sakamoto A, Imai Y, Terasaki F, Nagai R (2012) Multifocal fibrosclerosis and IgG4-related disease involving the cardiovascular system. *J Cardiol* 59: 132-138.
3. Kyeongmin B, Joungho H, Jung-Sun K, Wook Sung K, Yeon H C, et al. (2011) Immunoglobulin G4-Related Periaortitis Mimicking an Intramural Hematoma. *Ann Thorac Surg* 92: 1506-1508.

4. Vaglio A, Greco P, Corradi D, Palmisano A, Martorana D, et al. (2006) Autoimmune aspects of chronic periaortitis. *Autoimmun Rev* 5: 458-464.
5. Mitchinson MJ (1984) Chronic periaortitis and periarteritis. *Histopathology* 8: 589-600.
6. Kasashima S, Zen Y, Kawashima A, Konishi K, Sasaki H, et al. (2008) Inflammatory abdominal aortic aneurysm: close relationship to IgG4-related periaortitis. *Am J Surg Pathol* 32: 197-204.
7. Adler S, Lodermeier S, Gaa J, Heemann U (2008) Successful mycophenolatemofetil therapy in nine patients with idiopathic retroperitoneal fibrosis. *Rheumatology (Oxford)* 47: 1535-1538.
8. ORMOND JK (1948) Bilateral ureteral obstruction due to envelopment and compression by an inflammatory retroperitoneal process. *J Urol* 59: 1072-1079.
9. Albarran J (1905) Rétenionrénale par périurétérite. Libération externe de l'urétére. *AssocFrUrol* 9: 511
10. Martorana D, Vaglio A, Greco P, Zanetti A, Moroni G, et al. (2006) Chronic periaortitis and HLA-DRB1*03: another clue to an autoimmune origin. *Arthritis Rheum* 55: 126-130.
11. Koep L, Zuidema GD (1977) The clinical significance of retroperitoneal fibrosis. *Surgery* 81: 250-257.
12. Yin MD, Zhang J, Wang SY, Duan ZQ, Xin SJ (2010) Inflammatory abdominal aortic aneurysm: clinical features and long term outcome in comparison with atherosclerotic abdominal aortic aneurysm. *Chin Med J* 123: 1255-1258.
13. Yoshizaki T, Tabuchi N, Makita S (2007) Inferior vena cava occlusion secondary to an inflammatory abdominal aortic aneurysm. *Interact Cardiovasc Thorac Surg* 6: 128-129.

Citation: Benassi F, Molardi A, Nicolini F, Cocconcelli F, Corradi D, et al. (2013) Igg4-Related Aortitis of the Ascending Aorta in a Patient Undergoing Emergent Coronary Artery Bypass Graft: A Challenging Disease. *J Genet Syndr Gene Ther* 4: 188. doi:[10.4172/2157-7412.1000188](https://doi.org/10.4172/2157-7412.1000188)

This article was originally published in a special issue, **Genetic Disorders** handled by Editor(s). Dr. Xiaobo Li, Yeshiva University, USA

Submit your next manuscript and get advantages of OMICS Group submissions

Unique features:

- User friendly/feasible website-translation of your paper to 50 world's leading languages
- Audio Version of published paper
- Digital articles to share and explore

Special features:

- 250 Open Access Journals
- 20,000 editorial team
- 21 days rapid review process
- Quality and quick editorial, review and publication processing
- Indexing at PubMed (partial), Scopus, EBSCO, Index Copernicus and Google Scholar etc
- Sharing Option: Social Networking Enabled
- Authors, Reviewers and Editors rewarded with online Scientific Credits
- Better discount for your subsequent articles

Submit your manuscript at: <http://www.editorialmanager.com/omicsgroup/>

