

Case Report

Open Access

## Multiple Primary Urological Tumors in a Patient with Proportionate Dwarfism: A Case Report

Cantile M<sup>1\*</sup>, Marra L<sup>1</sup>, Striano S<sup>2</sup>, Claudio L<sup>2</sup>, Menna L<sup>2</sup>, Botti G<sup>1</sup>, Franco R<sup>1</sup> and Marra L<sup>2</sup>

<sup>1</sup>Pathology Unit, "Istituto Nazionale Tumori Fondazione "G. Pascale"-IRCCS, Naples, Italy

<sup>2</sup>Urology Unit, "Istituto Nazionale Tumori Fondazione "G. Pascale"-IRCCS, Naples, Italy

### Abstract

Multiple primary tumors occur quite rarely in humans. However, malignancies associated with urinary system are highly described in literature. This neoplastic condition, although it is unknown whether it belongs to a precise cancer syndrome, has never been directly observed in individuals with proportionate dwarfism. We describe a case of middle-aged man with endocrine disorders, causing short stature, with two primary urological metachronous tumors, renal and prostate cancers.

**Keywords:** Proportionate dwarf; Renal cancer; Prostate cancer

### Introduction

Multiple primary tumors are defined as two or more malignancies in a single individual without any relationship between cancers [1]. Its clinical manifestation is rare but it has increased in frequency in recent years [2-5].

Since the time between the first and second neoplastic transformation is variable, primary tumors that coexist at the time of diagnosis are defined "synchronous", while if they develop subsequently they are defined "metachronous".

Multiple primary carcinomas often occur in the colon-rectum [6] and urinary system [7]. Particularly, renal cell carcinoma has frequently been reported to be associated with other primary urological malignancies including bladder and prostate [8-12].

Although in most cases the multiple malignancies are not linked, the origin of these tumors in the urogenital system, may also have genetic bases still not investigated at the moment [13]. Furthermore, their simultaneous presence in individuals with structural alterations of body growth, due to endocrine disorders, has never been described.

Endocrine disorders causing short stature are usually diagnosed on the basis of visible symptoms, in fact a physical examination can usually suffice to diagnose many types of dwarfism. However, in order to have the correct definition of the clinical condition an accurate diagnostic imaging and genetic tests are necessary.

There are over 300 different types of disorders associated to abnormal skeletal growth and dwarfism [14], most of which are genetic, that can define two main groups: those with proportionate growth (short-trunk and short limbs) and those with disproportionate development (short limbs). Proportionate dwarfism include pituitary dwarfism congenital or acquired and may be associated with deficiencies of several hormones, including growth tropins, Vasopressin, Gonadotropins, and Adrenocorticotrophic hormone (ACTH) [15].

Rarely, individuals with proportionate dwarfism manifest neoplastic diseases, which are described in the disproportionate dwarfs, especially in those with achondroplasia (mutation in Fibroblast growth factor receptor 3 (FGFR3) resulting in constitutively active receptor) [16-22]. Indeed, in a group of proportionate dwarfs, with a overt genetic diagnosis of Laron syndrome inactive Growth hormone (GH) receptor deficiency resulting in Insulin-like growth factor 1(IGF1), it

was described that this clinical condition could even be protective for certain types of cancer [23].

In this report, we present, for the first time, a patient with congenital proportionate dwarfism, never subjected to genotyping analysis, which has developed two metachronous primary tumors in the kidney and prostate.

### Case Report

A 55-year old man came to our Institution, Fondazione Pascale Hospital, for urinary oncological counseling. He was of proportionate

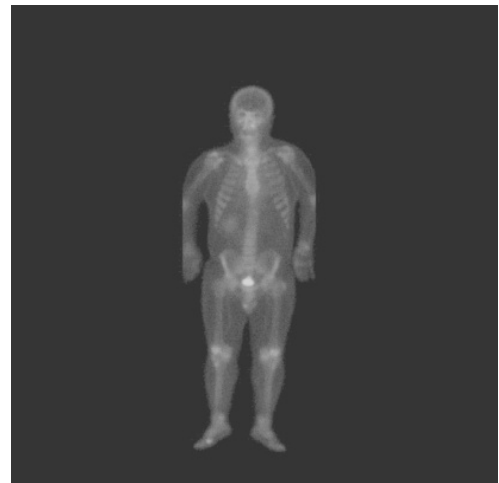

Figure 1: Whole body bone scan.

**\*Corresponding author:** Monica Cantile, Pathology Unit, National Cancer Institute, Pascale Hospital, via Mariano Semmola 80131, Naples, Italy, Tel: +39-081-5903745; Fax: +39-081-5903718; E-mail: [monicantile@libero.it](mailto:monicantile@libero.it)

Received July 02, 2013; Accepted July 05, 2013; Published July 08, 2013

**Citation:** Cantile M, Marra L, Striano S, Claudio L, Menna L, et al. (2013) Multiple Primary Urological Tumors in a Patient with Proportionate Dwarfism: A Case Report. J Genet Syndr Gene Ther 4: 158. doi:10.4172/2157-7412.1000158

**Copyright:** © 2013 Cantile M, et al. This is an open-access article distributed under the terms of the Creative Commons Attribution License, which permits unrestricted use, distribution, and reproduction in any medium, provided the original author and source are credited.

short stature (Figure 1); his height was 138 cm and he weighted was 52 kg. He had never been seen by a geneticist for genotyping analysis to properly classify his dwarfism.

Routine preoperative blood test showed the following hormonal panel: TSH 6,266 mIU/L (hypothyroid patients >5), LH 20,49 mIU/ml (normal range 1,5-14), FSH 74,89 mIU/ml (normal range 1,55-9,74), testosterone 6,41 mIU/ml (normal range 2,5-28), PRL 247,5 mIU/ml (normal range 78-380).

He had history of renal cancer disease diagnosed thirteen years ago at the Cardarelli Hospital, Naples. From the instrumental analysis, performed during the hospitalization, the absence of peritoneal fluid and the presence of neoplastic mass at the height of the left bottom renal pole of dimension 75 x 70 mm have been noted. No involvement of surrounding organs was present, only an increase in prostate volume.

The patient underwent left radical nephrectomy. The following histopathology examination has allowed the diagnosis of a clear cell renal carcinoma, Fuhrman grade II, stage pT3 pNxMx (Figure 2a). In 2010, during a routine follow-up control, in our Institute, the patient showed a great increase in serum PSA value (15 ng/mL) and a prostatic hypertrophy. Subsequently, the patient underwent more prostate biopsies, submitted to histological examination. Three out of the 6 examined biopsies revealed suspect foci of prostate adenocarcinoma. During close follow-up, in few months, a progressive increase of the PSA and of the prostate volume was observed with ultrasonography.

Then, the patient underwent once again prostate multiple biopsies for deciding radical retro pubic prostatectomy (RRP) and pelvic emptying.

After surgery, pathologic analysis and estimation of tumor volume

in RRP specimen was conducted with standard procedures. Prostate specimen was sectioned and entirely embedded according to a standard cutting protocol. All slides involved with tumor were identified, and the areas of carcinoma were highlighted. We evaluated the risk of clinically insignificant disease, defined as pathologic Gleason score 6 or less, <10% estimated tumor volume, no extracapsular extension, positive lymph nodes, seminal vesicle invasion, or positive surgical margin. Alternatively, we evaluated the risk of adverse pathology, defined as pathologic Gleason score 7 or higher, >25% estimated tumor volume, positive extracapsular extension, lymph node involvement, seminal vesicle invasion, or any positive surgical margin.

The histopathology confirmed the presence of prostate adenocarcinoma, Gleason score 7 (4+3), on both lobes with involvement of margins and seminal vesicles (Figure 2b). The lymph nodes were negative (pT3 R1 N0). The subject is still in follow-up.

## Discussion

The manifestation of multiple tumors in the same individual, synchronous or metachronous, are taking in recent years an increasing clinical relevance. Causal mechanism of this event can include environment but mainly relevant genetic events, or combination of both. However, genetically predisposed to develop multiple cancers is still currently the subject of numerous studies [24]. Tumors that develop in the urogenital system, in particular renal, bladder and prostate cancers have been described abundantly in the literature as individual cases report [2-4], because a common problem consists in the fact that generally as endoneurial diagnosis location from the first, is diagnosed later in other hospital structures. The establishment of a cancer registry made available to clinicians and researchers would adequately define the incidence and distribution of this clinical manifestation, and would carry out studies aimed at understanding the possible molecular mechanisms that determine it. In fact, despite their rarity, it is important to consider hereditary cancer syndromes in patients with multiple or early-onset malignancies. This point is especially true for renal tumors, which occur in a number of the more common inherited syndromes [25].

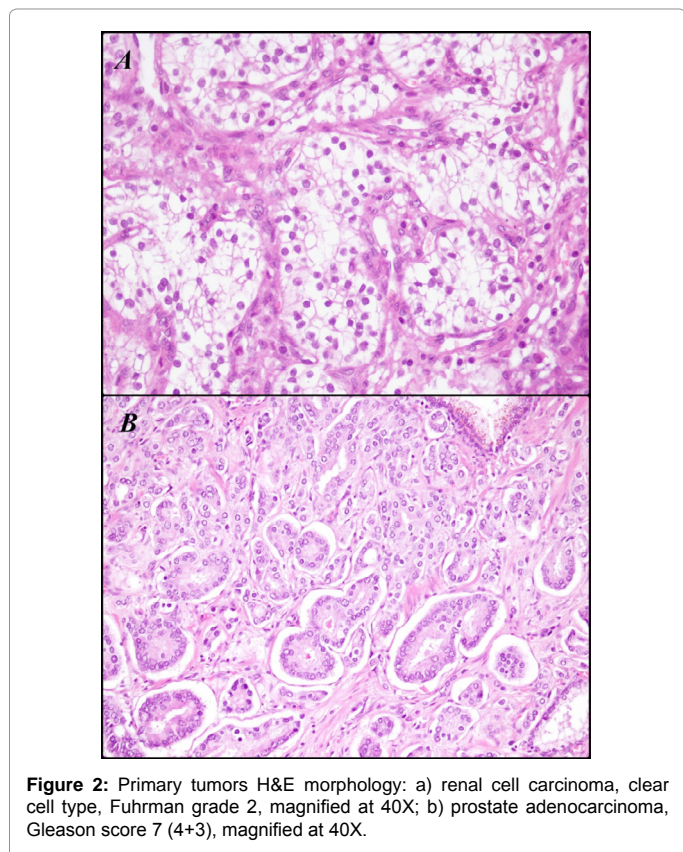
The case described is very interesting in this context, because in addition to occur two metachronous tumors of the urinary system, also presents characteristics of proportionate dwarfism.

There are different forms of dwarfism, some directly associated with genetic defects [14]. For example in Laron syndrome an isolated deficiency of GH occurs. These patients are perfectly proportioned and can mature sexually and may reproduce. In some cases there is normal or even high GH secretion, but there is a hereditary inability to form IGF-1 in response to the GH [26]. A form of disproportionate dwarfism, achondroplasia, which causes a failure of harmonious development of the growth plate of the long bones of the limbs is much studied.

The disease causes severe growth disorders. This pathology is caused by activating mutations in FGFR3 gene and inherited in an autosomal dominant manner [27]. Again, a form of dwarfism very investigated, due to autosomal recessive congenital disorder, is represented by Mulibreyanism associated with a recessive defect in the gene TRIM37 [28].

In our case, the patient, who has never undergone genetic testing, shows a short stature and an hormonal framework, that make lean toward endocrine disorders at the origin of his clinical manifestations.

However, cases of proportionate dwarfism with multiple tumors have never been described in the literature. This is instead an event



**Figure 2:** Primary tumors H&E morphology: a) renal cell carcinoma, clear cell type, Fuhrman grade 2, magnified at 40X; b) prostate adenocarcinoma, Gleason score 7 (4+3), magnified at 40X.

known for achondroplasia [16,17] and for Mulibrey nanism, particularly those associated to the kidney, thyroid gland, and gynaecological cancers [29-31].

On the contrary there is evidence in the literature that proportionate dwarfs, with established Laron syndrome, characterized by congenital IGF-I deficiency, are even protected towards different forms of cancer [32,33].

The patient described shows a very complex clinical presentation. Although the events that led to the development of multiple urological primary tumors, have occurred over time, arising in an individual with problems of body growth, which have allowed us to hypothesize a potential link between these events.

A strong correlation between the abnormal skeletal development and alteration of several body organs and systems is well known for several genetic diseases. For example lumbo-sacral HOX genes, which control the proper formation of limbs, during embryonic development, are also involved with normal kidney development and kidney cancer progression [34,35].

However, we have no elements to classify the dwarfism of the patient in a specific genetic class disorders, thus the description of this case allows us only to speculate on the potential relationship between the two clinical manifestations.

## References

1. Moertel CG, Dockerty MB, Baggenstoss AH (1977) Multiple primary malignant neoplasms. *Cancer* 14: 221-248.
2. Yhim HY, Kim HS, Lee NR, Kwak JY, Yim CY, et al. (2010) Quadruple primary malignancies of liver, bladder, lung and stomach in one patient. *Tumori* 96: 787-791.
3. Mydlo JH, Agins JA, Donohoe J, Grob BM (2001) A review of urologic cancer patients with multiple primary malignancies. *World J Urol* 19: 240-243.
4. Sato S, Shinohara N, Suzuki S, Harabayashi T, Koyanagi T (2004) Multiple primary malignancies in Japanese patients with renal cell carcinoma. *Int J Urol* 11: 269-275.
5. Beisland C, Talleraas O, Bakke A, Norstein J (2006) Multiple primary malignancies in patients with renal cell carcinoma: a national population-based cohort study. *BJU Int* 97: 698-702.
6. Tziris N, Dokmetzioglou J, Giannoulis K, Kesisoglou I, Sapalidis K, et al. (2008) Synchronous and metachronous adenocarcinomas of the large intestine. *Hippokratia* 12: 150-152.
7. Zargar-Shoshtari MA, Saffari H, Moslemi MK (2013) Metachronous occurrence of triple malignancies of kidneys, prostate, and breast. A case report and review of the literature. *Case Rep Urol* 2013: 194620.
8. Rabbani F, Reuter VE, Katz J, Russo P (2000) Second primary malignancies associated with renal cell carcinoma: influence of histologic type. *Urology* 56: 399-403.
9. Koutsopoulos AV, Dambaki KI, Datsis G, Giannikaki E, Froudarakis M, et al. (2005) A novel combination of multiple primary carcinomas: urinary bladder transitional cell carcinoma, prostate adenocarcinoma and small cell lung carcinoma--report of a case and review of the literature. *World J Surg Oncol* 3: 51.
10. Arian-Sengul C, Pehlivan Y, Sevinc A, Karakok M, Kalender ME, et al. (2009) A case of metachronous triple primary urogenital cancer: urinary bladder, prostate, and renal cancer. *Onkologie* 32: 122-124.
11. Mydlo JH, Gerstein M (2001) Patients with urologic cancer and other nonurologic malignancies: analysis of a sample and review of the literature. *Urology* 58: 864-869.
12. Tiwari P, Tripathi A, Bansal P, Vijay M, Gupta A, et al. (2012) Synchronous primary cancers of urinary bladder and kidney and prostate. *Saudi J Kidney Dis Transpl* 23: 786-789.
13. Jefferson KP, Gillatt DA (2007) Hereditary urological cancer syndromes. *Nat Clin Pract Urol* 4: 218-26.
14. Spranger JW, Brill PW, Poznanski AK (2002) Mucopolysaccharidosis IV. In: Bone dysplasias: an atlas of genetic disorders of skeletal development. 2nd ed. Oxford University Press, Inc. New York 281-286.
15. Parks JS, Felner EI (2011) Hypopituitarism. In: Kliegman RM, Behrman RE, Jenson HB, Stanton BF (Eds.), *Nelson Textbook of Pediatrics*. (19th edn), Philadelphia, Pa: Saunders Elsevier 551.
16. Stoll C, Feingold J (2004) Do parents and grandparents of patients with achondroplasia have a higher cancer risk? *Am J Med Genet A* 130A: 165-168.
17. Kimura T, Suzuki H, Ohashi T, Asano K, Kiyota H, et al. (2001) The incidence of thanatophoric dysplasia mutations in FGFR3 gene is higher in low-grade or superficial bladder carcinomas. *Cancer* 92: 2555-2561.
18. Geromin A, Sperotto A, Fanin R, Damiani D, Michieli M, et al. (1997) Bone marrow transplantation in a patient with chronic myeloid leukemia and achondroplasia. *Haematologica* 82: 703-704.
19. Eire PF, Pintos E, Jardon JA, Estevez E, Varela Cives R (1995) Gallbladder carcinoma in an achondroplastic boy. *Eur J Pediatr Surg* 5: 313-314.
20. Dodurga Y, Tataroglu C, Kesen Z, Satioglu-Tufan NL (2011) Incidence of fibroblast growth factor receptor 3 gene (FGFR3) A248C, S249C, G372C, and T375C mutations in bladder cancer. *Genet Mol Res* 10: 86-95.
21. Gyomber D, Angus D, Lawrentschuk N (2009) Anatomic considerations for radical retropubic prostatectomy in an achondroplastic dwarf. *Scientific World Journal* 9: 204-208.
22. Margari L, Presicci A, Ventura P, Bacca SM, Tota T, et al. (2006) The strange association between achondroplasia and neurofibromatosis type 1: molecular analysis of a new patient and review of the literature. *Genet Couns* 17: 237-243.
23. Laron Z (2008) The GH-IGF1 axis and longevity. The paradigm of IGF1 deficiency. *Hormones (Athens)* 7: 24-27.
24. Frank SA (2004) Genetic predisposition to cancer - insights from population genetics. *Nat Rev Genet* 5: 764-772.
25. Lonser RR, Glenn GM, Walther M, Chew EY, Libutti SK, et al. (2003) von Hippel-Lindau disease. *Lancet* 361: 2059-2067.
26. Laron Z (2004) Insulin-like growth factor-I (IGF-I): safety and efficacy. *Pediatr Endocrinol Rev* 2 Suppl 1: 78-85.
27. Horton WA, Hall JG, Hecht JT (2007) Achondroplasia. *Lancet* 370: 162-172.
28. Avela K, Lipsanen-Nyman M, Idänheimo N, Seemanová E, Rosengren S, et al. (2000) Gene encoding a new RING-B-box-Coiled-coil protein is mutated in mulibrey nanism. *Nat Genet* 25: 298-301.
29. Karlberg N, Karlberg S, Karikoski R, Mikkola S, Lipsanen-Nyman M, et al. (2009) High frequency of tumours in Mulibrey nanism. *J Pathol* 218: 163-171.
30. Seemanová E, Bartsch O (1999) Mulibrey nanism and Wilms tumor. *Am J Med Genet* 85: 76-78.
31. Karlberg S, Lipsanen-Nyman M, Lassus H, Kallijärvi J, Lehesjoki AE, et al. (2009) Gynecological tumors in Mulibrey nanism and role for RING finger protein TRIM37 in the pathogenesis of ovarian fibrothecomas. *Mod Pathol* 22: 570-578.
32. Laron Z (2008) The GH-IGF1 axis and longevity. The paradigm of IGF1 deficiency. *Hormones (Athens)* 7: 24-27.
33. Shevah O, Laron Z (2007) Patients with congenital deficiency of IGF-I seem protected from the development of malignancies: a preliminary report. *Growth Horm IGF Res* 17: 54-57.
34. Cantile M, Franco R, Schiavo G, Procino A, Cindolo L, et al. (2011) The HOX genes network in uro-genital cancers: mechanisms and potential therapeutic implications. *Curr Med Chem* 18: 4872-4884.
35. Cantile M, Schiavo G, Franco R, Cindolo L, Procino A, et al. (2011) Expression of lumbosacral HOX genes, crucial in kidney organogenesis, is systematically deregulated in clear cell kidney cancers. *Anticancer Drugs* 22: 392-401.