

## Acute Myopericarditis due to Hepatitis E Virus Infection: The First Reported Case in the Western Hemisphere

Timothy Dougherty, Showkat Bashir, Mahmuda Khan Jason Adam and Marie Borum\*

Division of Gastroenterology and Liver Diseases George Washington University, Washington, D.C., USA

\*Corresponding author: Marie L. Borum, MD, EdD, MPH Professor of Medicine Director, Division of Gastroenterology and Liver Diseases George Washington University, Washington, D.C., USA, Tel: 1-202-741-2160; E-mail: [mborum@mfa.gwu.edu](mailto:mborum@mfa.gwu.edu)

Rec date: Dec 28, 2015, Acc date: Jan 28, 2016, Pub date: Feb 5, 2016

Copyright: © 2016 Dougherty T, et al. This is an open-access article distributed under the terms of the Creative Commons Attribution License, which permits unrestricted use, distribution, and reproduction in any medium, provided the original author and source are credited.

### Abstract

Hepatitis E is a single stranded RNA virus endemic to parts of Asia and Africa. Presentation ranges from asymptomatic to fulminant hepatic failure. Extrahepatic manifestations include acute pancreatitis, Guillain-Barre syndrome, neuralgic amyotrophy, hemolytic anemia, thrombocytopenia, glomerulonephritis, and mixed cryoglobulinemia.

**Keywords:** Hepatitis E infection; Acute myopericarditis

### Introduction

Hepatitis E is a single stranded RNA virus endemic to parts of Asia and Africa. Presentation ranges from asymptomatic to fulminant hepatic failure. Extrahepatic manifestations include acute pancreatitis, Guillain-Barre syndrome, neuralgic amyotrophy, Hemolytic anemia, Thrombocytopenia, glomerulonephritis, and mixed Cryoglobulinemia [1,2]. Believed to be transmitted via the fecal-oral route, it has a short prodromal phase, and a self-limited symptomatic period lasting days to weeks [3,4] Hepatitis E is a common cause of acute hepatitis in the world, but it is uncommon in the United States where it has typically been encountered in patients returning from developing countries or after consumption of undercooked pork.

Here we report a case of HEV-associated myopericarditis which we believe to be the first involving a patient who lives and travels in the western hemisphere. Our patient's disease was relatively mild. The other reported cases of HEV-myocarditis have occurred in India and in patients with severe illness [5].

### Case Report

A 50-year-old woman with history of Gilbert syndrome presented to our hospital with a two-day history of chest pain, palpitations, dyspnea on exertion, and a single syncopal episode. She had felt chilled but denied fever, abdominal pain, nausea, vomiting, icterus, jaundice, and any change in stool or urine color. She had returned from a two-week trip to Panama ten days earlier and noted a period of rhinorrhea and malaise while she was there.

During the trip, she spent time in the rainforest, pastures, and cities. She denied any contact with live mammals. She had not used any medications, supplements, or herbal preparations. She denied alcohol and drug abuse. Physical exam was notable for mild, fluid-responsive hypotension and a pericardial friction rub. She was free of rashes, arthritis, and fever.

Laboratory studies included an elevated Troponin I at 1.32 ng/mL (reference range 0–0.034) and creatinine phosphokinase MB of 5.4 ng/mL (reference range 0-2.3).

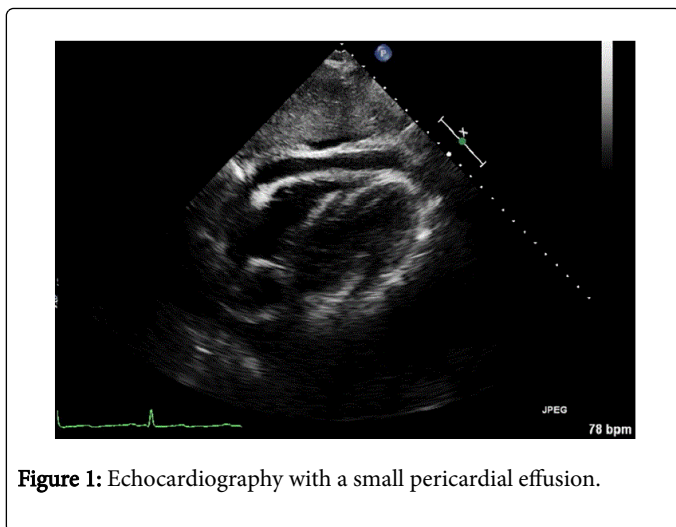
An electrocardiogram revealed generalized PR segment depression. Echocardiography demonstrated a small pericardial effusion. (Figure 1) Computed tomography ruled out pulmonary embolism. These findings support a diagnosis of myopericarditis.

In addition, she was also noted to have elevated transaminases (serum AST 292 units/L, ALT 307 units/L) and bilirubin 1.7 mg/dL (all unconjugated).

Laboratory values are shown in Table 1. A sonogram of the right upper abdomen showed a normal liver and gallbladder. Assays for hepatitis A, B, and C were negative as were those for cytomegalovirus and coxsackie A virus.

White Blood Cells	7.05 X 10 <sup>3</sup> cells/ML
Red Blood Cells	4.32 X 10 <sup>6</sup> cells/ML
Hemoglobin	13.5 g/dL
Hematocrit	41.30%
Platelets	170 X 10 <sup>3</sup> cells/ML
AST	292 units/L
ALT	307 units/L
Total Bilirubin	1.7 mg/dL
Direct Bilirubin	0.0 mg/dL
Troponin I	1.32ng/mL (ref 0 – 0.034)
Creatinine Phosphokinase MB	5.4ng/mL (ref 0-2.3).
Prothrombin Time	14.3 sec

**Table 1:** Laboratory values of elevated transaminases.



**Figure 1:** Echocardiography with a small pericardial effusion.

The patient was treated for myopericarditis with non-steroid anti-inflammatory drugs. Her chest pain and dyspnea resolved and EKG changes normalized. Between her discharge and a follow up appointment two weeks later, positive results of an assay for immunoglobulin M directed against HEV were received. Her transaminase activity normalized and she was completely asymptomatic, so testing for HEV RNA was not obtained.

## Discussion

This is, to our knowledge, the only case of Hepatitis E myocarditis or pericarditis reported in the Western Hemisphere. Furthermore, it is the only reported case of myocarditis in the setting of a relatively minor HEV-related illness. While cardiac biopsy is the old standard, and cardiac MRI can be useful in the diagnosis, this patient had mild a mild course that did not justify invasive testing. Her cardiac troponin I was elevated, a finding that signifies myocarditis with 89% specificity [6].

The clinical presentation of myopericarditis is variable. While some cases are discovered incidentally, manifestations may range from pleuritic chest pain, decreased exercise tolerance, palpitations, and dyspnea to arrhythmia, dilated cardiomyopathy, and cardiogenic shock. Chest pain might be indistinguishable from ischemic pain; signs of myocarditis can mimic those of acute coronary syndrome. The development of concomitant pericarditis in the setting of myocardial inflammation is common [7].

Viral infection is the most common cause of myocarditis [7,8] and viral hepatitis have been associated with myocarditis [9]. Theories of pathogenesis include viral cytopathic changes, activation of the innate immune system, TNF over-expression, dysregulation of helper and regulatory T lymphocyte populations, and molecular mimicry resulting in autoimmune cardiomyocyte damage [7,10]. Hepatitis C virus in particular has shown evidence of cardiac tropism and has been shown to result in myocarditis and cardiomyopathies in patients with chronic hepatitis C [10]. A few cases of Hepatitis A-related carditis have also been reported [11,12]. Three cases of Hepatitis E-associated

myocarditis have been reported in India [5,13]. All of those patients were male and were critically ill. It is not clear why this patient had such a mild course. One possibility is that different virus genotypes may produce milder disease. Although there is significant geographic overlap with respect to the genotype isolates, Genotype 3 is common in North America but not in India and is associated with milder disease [1]. Other potential explanations include variations in host immunity or environmental factors such as selenium deficiency or mercury exposures [7].

This case of a Western hemisphere traveler with Hepatitis E-associated myocarditis is unique and serves as a reminder that Hepatitis E should be considered in patients who present with elevated liver transaminases and that the virus, known to result in severe disease in South Asia, can have significant consequences in the West as well. It also reminds clinicians that myopericarditis and HEV infection may vary widely in terms of clinical severity; while the severe presentations of these illnesses may be life-threatening, establishing the diagnosis in a mild illness can be valuable and reassuring.

## References

1. Aggarwal R, Naik S (2009) Epidemiology of hepatitis E: current status. *J Gastroenterol Hepatol* 24: 1484-1493.
2. Bazerbachi F, Haffar S, Garg SK, Lake JR (2015) Extra-hepatic manifestations associated with hepatitis E virus infection: a comprehensive review of the literature. *Gastroenterology Reports* 1-15.
3. Kamar N, Bendall R, Legrand-Abraham F, Xia NS, Ijaz S, et al. (2012) Hepatitis E. *Lancet* 379: 2477-2488.
4. Dalton HR, Stableforth W, Thuraiajah P, Hazeldine S, Remnarace R, et al. (2009) Autochthonous hepatitis E in Southwest England: natural history, complications and seasonal variation, and hepatitis E virus IgG seroprevalence in blood donors, the elderly and patients with chronic liver disease. *Eur J Gastroenterol Hepatol* 20: 784-790.
5. Premkumar M, Rangegowda D, Vashishtha C, Bhatia V, Khumuckham JS, et al. (2015) Acute viral hepatitis e is associated with the development of myocarditis. *Case Reports Hepatol* 2015: 458056.
6. Smith SC, Ladenson JH, Mason JW, Jaffe AS (1997) Elevations of cardiac troponin I associated with myocarditis: experimental and clinical correlates. *Circulation* 95: 163-168.
7. Cooper LT Jr (2009) Myocarditis. *N Engl J Med* 360: 1526-1538.
8. Pollack A, Kontorovich AR, Fuster V, Dec GW (2015) Viral myocarditis--diagnosis, treatment options, and current controversies. *Nat Rev Cardiol* 12: 670-680.
9. Omura T, Yoshiyama M, Hayashi T, Nishiguchi S, Kaito M, et al. (2005) Core protein of hepatitis C virus induces cardiomyopathy. *Circ Res* 96: 148-150.
10. Sanchez MJ, Bergasa NV (2008) Hepatitis C associated cardiomyopathy: potential pathogenic mechanisms and clinical implications. *Med Sci Monit* 14: RA55-63.
11. Yazu T, Miyata Y, Matsuura H, Kimura H, Koga S (1988) [A case of hepatitis A accompanied with acute myocarditis]. *Nihon Shokakibyo Gakkai Zasshi* 85: 1304-1307.
12. Jagtap R, Sethi R, Jeloka T (2008) Hepatitis A leading to myocarditis. *J Assoc Physicians India* 56: 391-392.
13. Goyal BK, Mishra DK, Kawar R, Kalmath BC, Sharma A, et al. (2009) Gautam S. Hepatitis E associated myocarditis: an unusual entity. *Bombay Hospital Journal* 51: 361-362.