

Anal Canal Electrosensitivity Test on Child Patients after Total Colectomy, Mucosal Proctectomy and Ileal J Pouch-Anal-Anastomosis

Ryouichi Tomita*

Department of Pediatric Surgery, Nihon University School of Medicine, Japan

*Corresponding author: Prof Ryouichi Tomita, M.D., Ph.D., Department of Surgery, Nippon Dental University Hospital at Tokyo, 2-3-16 Fujimi, Chiyoda-ku, Tokyo, 102-8158, Japan, Tel: +81-3-3261-5511; Fax: +81-3-3261-3924; E-mail: rtomita@tky.ndu.ac.jp

Received date: October 13, 2016; Accepted date: November 2, 2016; Published date: November 9, 2016

Copyright: © 2016 Tomita R. This is an open-access article distributed under the terms of the Creative Commons Attribution License, which permits unrestricted use, distribution, and reproduction in any medium, provided the original author and source are credited.

Abstract

Objectives: To clarify the role of anal canal sensitivity in soiling (minor incontinence; the seepage of mucus and/or stool during nighttime and/or daytime) in child patients after ileal J pouch-anal-anastomosis (IPAA), the author studied the sensory function of the anal canal. Twelve patients one year after IPAA for ulcerative colitis were studied (8 males, 4 females; aged 10.5 to 14.5 years, average 13.0 years).

Setting: Nihon University Hospital at Itabashi/Department of Pediatric Surgery

Methods: Four patients showed soiling (group A) and 8 patients showed continence (group B). Group C serving as controls consisted of 12 children with normal defecation (9 males, 3 females; aged 6 to 15 years, average 11.7 years). The anal canal sensitivity thresholds (ACST) on the oral side of the dentate line (ODL) and the anal side of the dentate line (ADL) were measured by anal canal electrosensitivity test.

Results: No patients in group A could discriminate between flatus and feces, but all those in group B could discriminate between them. In terms of ACST at the ODL, sensitivity levels of groups A and B were significantly lower than that of group C ($P=0.0249$, $P=0.0004$, respectively). In terms of ACST at the ADL, significantly lower sensitivity was found in patients of group A than in groups B and C ($P=0.0039$, $P=0.0021$, respectively).

Conclusion: The anal transitional zone may not contribute to discrimination between flatus and feces and not influence soiling following IPAA. Soiling after IAPP may be caused by damage to the sensory nerves in the ADL.

Keywords: Child; Anal canal sensitivity threshold; Soiling; Anal transitional zone; Ileal J pouch-anal-anastomosis

Introduction

The functional outcomes after total colectomy, mucosal proctectomy and the ileal J pouch-anal-anastomosis procedure (IPAA) in children with ulcerative colitis (UC) are better than those in adults [1-3]. However, some child patients experience impairments of defecation function after IPAA, including soiling (i.e., minor fecal incontinence; the seepage of mucus and/or stool during nighttime and/or daytime), incontinence, increased bowel movement, urgency of defecation, evacuation difficulty, irregular bowel habits and difficulty in distinguishing flatus from liquid or solid stool [4-7]. The most common abnormality is soiling [8-10]. Soiling in both children and adults is usually more severe in the early postoperative period of about 3 to 6 months after operation and improves with time, but may become permanent more than 1 or 1.5 years after IPAA [5]. Generally, the frequency of soiling in child patients more than 1 year after IPAA is 0 to 30% [1,2,4,5] and that in adults 30 to 40% [7-9]. It is suggested that patients after IPAA who have had soiling and/or incontinence showed anorectal motor disorders such as dysfunctions of anal sphincter and neorectum. Moreover, anal canal sensory function has been accepted as an important factor in the pathogenesis of anorectal disorders [10-13].

In histological studies, Duthie et al. [14] reported that the anal canal mucosa, especially the anal transitional zone (ATZ), has rich sensory innervation consisting of free nerve ending and sensory organs. The ATZ has been thought to have an important role in the ability to discriminate flatus from liquid or solid stool [13-15]. In a clinical context, Miller et al. [16] concluded that anal canal sensory function is very important to prevent soiling and incontinence. In contrast, the opposite opinion was proposed from the results of anal canal sensory function using electrosensitivity test [15]. Therefore, it is unclear whether the integrity of sensory function in the anal canal with or without the ATZ plays a role in the maintenance of continence. Generally, in the procedure of the IPAA for UC, mucosectomy of the anal canal including ATZ from the oral side of the dentate line (DL) has been performed and anastomosis between the ileal J pouch and the DL is carried out at the DL by handsewn anastomosis.

Thus, to clarify the role of anal canal mucosal sensory function in soiling in patients after IPAA for UC, the author assessed the sensory function of the anal canal in child patients after IPAA by measurement of the anal canal sensitivity threshold (ACST) by electrical sensitivity test.

Methods and Patients

From August 2000 to July 2015, IPAA was performed in 15 child patients for UC; 3 of these 15 patients refused to participate in this

study. The author thus studied a total of twelve children with UC (8 males and 4 females aged 10.5 to 14.5 with a mean age of 13.0 years) who had undergone IPAA. Four patients showed soiling 1 year after IPAA (the seepage of mucus and/or stool during nighttime and/or daytime, every day, with a pad needed to protect against soiling) (group A). Eight patients showed continence 1 year after IPAA (group B). Child patients with good control of bowel function from our clinics acted as controls (group C). Group C consisted of 12 subjects (9 males and 3 females aged 6 to 15 years old with a mean age of 11.7 years). All

patients after IPAA in this study had an uneventful postoperative course without severe complications (Table 1). All patients were tolerating a general diet at the time of the study, and all medications were withheld for 48 hours prior to this study. No patients had other diseases (without surgical histories, psychiatric diseases, metabolic diseases, endocrinological disorders, functional digestive tract impairments and organic digestive tract diseases) before undergoing the IPAA.

	Group A	Group B	Total
Cases	4	8	12
Sex (Male/Female)	3/1	5/3	8/4
Range of lesion			
Total colon and rectum	100% (4/4)	100% (8/8)	100% (12/12)
Operative indications			
Refractory symptoms	25.0% (1/4)	50.0% (4/8)	41.7% (5/12)
Chronic symptoms	25.0% (1/4)	37.5% (3/8)	33.3% (4/12)
Steroid side effect	25.0% (1/4)	12.5% (1/8)	16.7% (2/12)
Toxic dilatation	25.0% (1/4)	0% (0/8)	8.3% (1/12)
Surgical complications			
Wound infection	0% (0/4)	25.0% (2/8)	16.7% (2/12)
Intestinal ileus	25.0% (1/4)	12.5% (1/8)	16.7% (2/12)
Pouchitis	0% (0/4)	0% (0/8)	0% (0/12)
Soiling	100% (4/4)	0% (0/8)	33.3% (4/12)
Can you discriminate between flatus and feces?			
Yes	0% (0/4)	100% (8/8)	66.7% (8/12)
No	100% (4/4)	0% (0/8)	33.3% (4/12)
Group A: Patients with soiling 1 year after IPAA; Group B: Patients without soiling 1 year after IPAA; IPAA: Ileal J-pouch-anal-anastomosis			

Table 1: Characteristics of the child patients after IPAA for ulcerative colitis.

Operative technique

All patients underwent at a 2-stage operation. The first stage consisted of a total colectomy, complete mobilization of the small bowel mesentery and complete rectal mobilization. Rectal resection at the portion 5 cm at the oral side from the DL was carried out to make a short rectal cuff.

The terminal 20 cm of the ileum was used to construct an ileal J-pouch as a reservoir 10 cm in length. The ileal J-pouch-anal anastomosis was then completed by mucosectomy of the rectal short cuff including ATZ from the DL and hand sewing of the pouch to the anal canal. The hand-sewn anastomosis allowed accurate apposition of the apex of the J-pouch to the border of the transitional epithelium without retaining any unwanted colonic mucosa. A diverting ileostomy was performed in all patients. The second stage of the operation comprising closure of the ileostomy was carried out 1 month later.

Experiment procedure

The ACST values were measured by a special catheter. The special catheter was equipped with platinum electrodes and a stimulating probe, consisting of a 12 Fr Foley catheter (Balloon Catheter Type 94001, Unique Medical, Tokyo, Japan), which had two platinum wire electrodes 1 cm apart near the tip. This device was connected to a battery-powered constant current generator producing a square wave stimulus with a frequency of 5 Hz and 0.1 ms duration (Electric Stimulator SMN-7203, Nippon-koden, Tokyo, Japan). The current across the electrodes was then gradually increased in 1 mA increments until the subject felt the stimulus, which was often described as a tingling, pulsing or prickling sensation. The maximum stimulus was 20 mA in this system. The ACST was assessed on the oral side from the DL (ODL) and on the anal side from it (ADL) (Figure 1). In the experimental procedure, no bowel preparation was carried out, and after an overnight fast, subjects were given the opportunity to empty their bowel before the experiment. No sedative was given.

Measurements of the ACST were performed at 9:00 a.m. with the subjects in the left lateral decubitus position with the knees drawn up.

Bonferroni correction was used. A P-value less than 0.05 was regarded as significant.

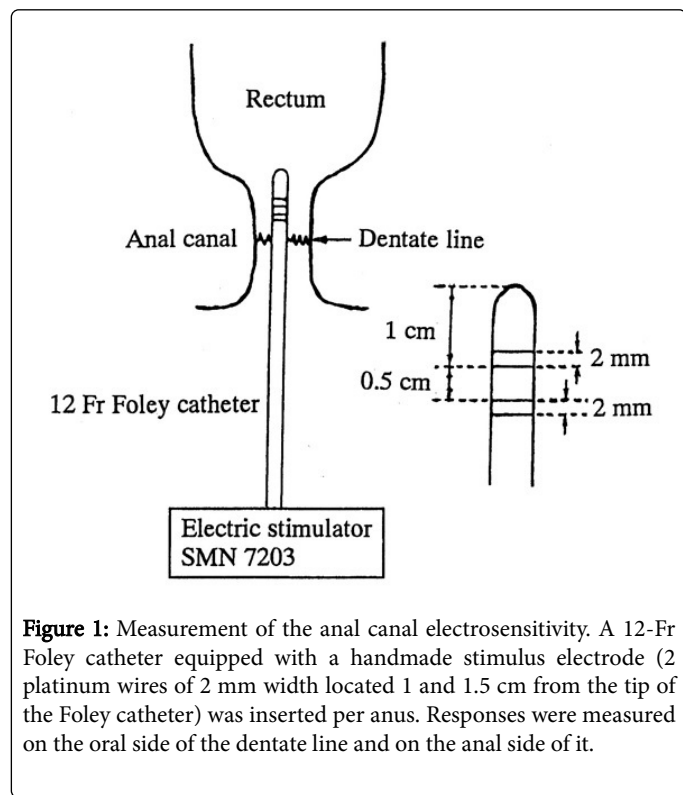


Figure 1: Measurement of the anal canal electrosensitivity. A 12-Fr Foley catheter equipped with a handmade stimulus electrode (2 platinum wires of 2 mm width located 1 and 1.5 cm from the tip of the Foley catheter) was inserted per anus. Responses were measured on the oral side of the dentate line and on the anal side of it.

Results

Characteristics of the child patients after IPAA for ulcerative colitis

In all children after IPAA, range of lesions were total colon and rectum. The frequencies of soiling (group A) were 25.0% (4/12) and those of continence (group B) 75.0% (8/12) 1 year after IPAA. The operative indications were refractory symptoms (41.7%, 5/12); chronic symptoms (33.3%, 4/12); steroid side effects (16.7%, 2/12); and toxic dilatation (8.3%, 1/12). The surgical complications were wound infection (16.7%, 2/12) and intestinal obstruction (16.7%, 2/12). These patients did not have severe complication such as pouchitis in their daily life. In regard to discrimination of flatus, liquid or solid stool, no patients in group A could discriminate flatus from liquid or solid stool. All patients in group B could discriminate between them (Table 1).

Comparative studies of the ACST in groups A, B and C

The values of the ACST at the ODL were 4.8 ± 0.8 mA in group A, 5.0 ± 0.9 mA in group B and 3.3 ± 0.6 mA in group C. There was no significant difference between groups A and B ($P=0.6874$). However, anal canal sensitivity in groups A and B was significantly lower than that in group C ($P=0.0249$, $P=0.0004$, respectively). The values of the ACST at the ADL were 4.1 ± 0.4 mA in group A, 3.0 ± 0.8 mA in group B and 2.8 ± 0.9 mA in group C. Significantly lower sensitivity was found in patients in group A than in groups B and C ($P=0.0039$, $P=0.0021$, respectively). However, there was no significant difference between groups B and C ($P=0.4988$) (Table 2). According to these results, no importance of preserving the ATZ was recognized from the clinical questionnaire. The ACST also demonstrated that anal canal sensory disorder in the ADL may influence soiling following IPAA.

Statistical analysis

The results are presented as mean \pm standard deviation. For statistical analysis of the ACST, the Mann-Whitney U test with

Oral side of the anal canal from the dentate line	
Group A	4.8 ± 0.8 mA ^a
Group B	5.0 ± 0.9 mA ^b
Group C	3.3 ± 0.6 mA ^c
Anal side of the anal canal from the dentate line	
Group A	4.1 ± 0.4 mA ^d
Group B	3.0 ± 0.8 mA ^e
Group C	2.8 ± 0.9 mA ^f
Group A: Patients with soiling; Group B: Patients without soiling; Group C: Control subjects; a vs. b, $P=0.6874$; a vs. c, $P=0.0249$; b vs. c, $P=0.0004$; d vs. e, $P=0.0039$; d vs. f, $P=0.0021$; e vs. f, $P=0.4988$	

Table 2: The ACTS in groups A, B and C.

Discussion

Generally, the ATZ located in the anal canal has been thought to have an important role in the ability to discriminate flatus from liquid or solid stool, and this role mainly prevents soiling or incontinence [10,13,14]. However, Read et al. [12] showed that application of local anesthesia to the ATZ did not impair results of the saline infusion test

for continence. It is also reported that, after excision of the anorectum including anal mucosa and restoration by coloanal anastomosis, continence was not impaired [16,17]. In contrast, there are also some reports describing that removal of anal mucosa including the ATZ for restorative proctocolectomy resulted in impaired anal canal sensitivity [18,19]. These results suggest that the importance of the ATZ in maintaining continence remains controversial. Thus, it is unclear

whether the integrity of sensory function in the anal canal with or without preserving the AZT plays a role in the maintenance of continence. In the present study, no child patients with soiling after IPAA could discriminate flatus, liquid or solid stool. However, patients without soiling after IPAA could discriminate between them. According to these results, it can be considered that preserving the ATZ may not be important for discriminating flatus from liquid or solid feces.

To assess the anal canal sensory function by electrosensitivity test, measurement of the ACST is the most important technique [17]. The ACST using anal canal electrosensitivity enables more objective and quantitative assessment of the sensory functions in the anal canal [20-22]. The technique of the ACST provides simple and rapid assessment of anal canal sensation. For the first time, Roe et al. [17] reported that sensory impairment in the anal canal of soiling and/or incontinent patients could be detected by mucosal electrosensitivity test. To clarify the significance of the anal canal sensory function in patients with or without soiling after IAPP, the author studied the anal canal sensory function by measurement of the ACST using anal canal electrosensitivity test.

In the present study, patients with soiling also showed impairment of electrosensitivity function at both ODL and ADL. Although patients without soiling showed impaired electrosensitivity function at the ODL, these patients exhibited nearly normal electrosensitivity at the ADL. Therefore, soiling due to anal canal sensory disturbance at oral side from DL in patients after IAPP may be detectable by measurement of the ACST at the ADL. The reasons why the ACST in patients with soiling after IPAA was lower may be as follows:

1) In childhood, there were practical difficulties derived from the intra-pelvic procedures and operative interventions through the anus because the pelvis is narrow. In particular, patients with soiling had a very narrow pelvis and surgery was more difficult than in patients without soiling. Therefore, the sensory nerve (i.e., inferior rectal branch of the pudendal sensory nerve) was excessively extended and injury might have been inflicted on patients with soiling more than in patients without soiling.

2) The inferior rectal branch of the pudendal sensory nerve runs into the anal canal from the anal verge to the upper anal canal and it gradually becomes narrower in the upper side of the anal canal than in the lower side of the anal canal. Therefore, pudendal sensory nerve innervating the upper anal canal from the DL may be more easily damaged than that on the anal side of the anal canal from the DL during operation. Although upper anal canal sensory function disappears after anal canal mucosectomy including the ATZ from the DL, anal canal sensory function may be maintained by the lower anal canal from the DL.

According to these results, the ATZ may not be necessary to prevent soiling, and sensory nerves in the ADL may be important to protect against soiling, rather than those in the ODL.

In conclusion, the ATZ may not be necessary to prevent soiling in patients after IPAA. The ACST at the ODL in patients with or without soiling was lower than in control subjects. The ACST at the ADL in patients with soiling was lower than that in patients without soiling. In addition, the ACTS at the ADL showed no difference between patients without soiling and normal subjects. Therefore, soiling after IAPP may be caused by damage to the sensory nerves innervating the ADL. In this study, the sample size was small. It is important an increased number of pediatric patients after IPAA be examined in the future so

that a more powerful statistical analysis can be performed. Recently, it has been considered that continence depends on the functional integrity of both sensory and motor functions of the anorectum. Therefore, it is necessary for us to study the relationships between anorectal motor functions (internal anal sphincter, external anal sphincter and puborectalis muscle functions) and sensory function in the future.

References

1. Telander RL, Spencer M, Perrault J, Telander D, Zinsmeister AR (1990) Long-term follow-up of ileoanal anastomosis in children and young adults. *Surgery* 108: 717-725.
2. Matikainen M, Aitola P, Hiltunen KM (2000) Ileal pouch-anal anastomosis operation in children versus adults. *Ann Chir Gynecol* 89: 104-106.
3. Lillehei CW, Leichtner A, Bousvaros A, Shamberger RC (2009) Restorative proctocolectomy and ileal pouch-anal anastomosis in children. *Dis Colon Rectum* 52: 1645-1649.
4. Uchida K, Kawamata A, Hashimoto K, Inoue M, Otake K (2013) Self-reported assessment of health-related quality of life in children who underwent restorative proctocolectomy with ileal-pouch anal anastomosis for ulcerative colitis. *Pediatr Surg Int* 29: 287-291.
5. Ceriati E, Peppo FD, Rivosecchi M (2013) Role of surgery in pediatric ulcerative colitis. *Pediatr Surg Int* 29: 1231-1241.
6. Hait EJ, Bousvaros A, Schuman M, Shamberger RC, Lillehei CW (2007) Pouch outcomes among children with ulcerative colitis treated with calcineurin inhibitors before ileal pouch anal anastomosis surgery. *J Pediatr Surg* 42: 31-35.
7. Hahnloser D, Pemberton JH, Wolff BG, Larson DR, Crownhart BS, et al. (2007) Results at up to 20 years after ileal pouch-anal anastomosis for chronic ulcerative colitis. *Br J Surg* 94:333-340.
8. Patton D, Gupta N, Wojcicki JM, Garnett EA, Nobuhara K, et al. (2010) Postoperative outcome of colectomy for pediatric patients with ulcerative colitis. *J Paediatr Gastroenterol Nutr* 51:151-154.
9. Tomita R (2009) Ano-neorectal function using manometry on patients with soiling at 10 years or more after ileal J pouch-anal anastomosis for ulcerative colitis. *Hepatogastroenterology* 59: 1326-1330.
10. Robb BW, Gang GI, Hershko DD, MM Stoops (2003) Restorative proctocolectomy with ileal pouch-anal anastomosis in very young patients with refractory ulcerative colitis. *J Pediatr Surg* 38: 863-867.
11. Gaward KA, Wenske S, von Schrenck T, Izbicki JR (2007) Ileoanal-pouch reconstruction does not impair sphincter function or quality of life. *Hepatogastroenterology* 54: 1477-1482.
12. Read MG, Read NW (1982) Role of anorectal sensation in preserving continence. *Gut* 23: 345-347.
13. Ho YH, Goh HS (1995) Unilateral anal electrosensation. *Dis Colon rectum* 38:239-244.
14. Duthie HL, Gairns FW (1960) Sensory nerve-endings and sensation in the anal region of man. *Br J Surg* 47: 585-595.
15. Chattopadhyay G, Newbold M, Kumar D (1993) Anal transition zone and the distribution of neuroendocrine cells in the anorectum. *Dig Surg* 10: 29-32.
16. Miller R, Bartolo DC, Orrom WJ, Mortensen NJ, Roe AM, et al. (1990) Improvement of anal sensation with preservation of the anal transition zone after ileoanal anastomosis for ulcerative colitis. *Dis Colon Rectum* 33: 414-418.
17. Roe AM, Bartolo DCC, Mortensen NJMcC (1986) New method for assessment of anal sensation in various anorectal disorders. *Br J Surg* 73: 310-312.
18. Keighley MRB, Winslet MC, Yoshioka K, Lightwood R (1987) Discrimination is not impaired by excision of the anal transition zone after restorative proctocolectomy. *Br J Surg* 74: 1118-1121.
19. van Laarhoven CJ, Andriessse GI, Schipper ME, Akkermans LM, van Vroonhoven TJ, et al. (1999) Ileoneorectal anastomosis: early clinical

-
- results of a restorative procedure for ulcerative colitis and familial adenomatous polyposis without formation of an ileoanal pouch. *Ann Surg* 230: 750-757.
20. Holdsworth PJ, Johnston D (1988) Anal sensation after restorative proctocolectomy for ulcerative colitis. *Br J Surg* 75: 993-996.
21. Gemlo BT, Belmonte C, Wiltz O, Madoff RD (1995) Functional assessment of ileal pouch-anal anastomotic techniques. *Am J Surg* 169: 137-142.
22. Ikeda T, Tomita R, Koshinaga T (2005) Anal mucosal electric sensation in postoperative patients with anorectal malformations. *J Pediatr Surg* 40: 1146-1150.