

Chromosomal Aberrations of a Pediatric Intra Oral Lipoma: A Rare Case Report and Cytogenetic Forecasting

Rapala Harika^{1*}, Daneshwari V¹, Parsa Arun² and Raveen Teja P³

¹Department of Pedodontics and Preventive Dentistry, Mamata Dental College and Hospital, Khammam, Telangana, India

²Department of Pedodontics and Preventive Dentistry, Meghana Institute of Dental Sciences, Nizamabad, Telangana, India

³Departments of Prosthodontics, GSL Dental College and Hospital, Andhra Pradesh, India

Abstract

Lipomas are the most virtual type of soft tissue mesenchymal tumors which develop on the trunk and proximal portions of the extremities in elderly people of age supra 40 years. However, intraoral lipomas are very rare in children. Cytogenetic abnormalities have been found to be common in lipomatous tumors and to correlate reliably with morphological subtypes. We present a rare case of an intraoral lipoma in a five year old child along with its cytogenetic review. While histological diagnosis is a paragon of excellence for diagnosis in lipomatous tumors, cytogenetic analysis is quickly expanding its horizons to be an integral part of the diagnostic work up.

Keywords: Lipoma; Intramuscular; cytogenetic profile

Introduction

Lipoma is defined as a benign, slow growing neoplasm composed of mature fat cells [1]. The etiology persists unclear. About 15 to 20% of the cases affect the head and neck region, while 1-4% involves the oral cavity, an uncommon site for the occurrence of lipoma [2]. The foremost description of oral lipomas was given by Roux in 1848 in a review of alveolar mass; he referred it as a “yellow epulis” [1]. Usually, they are localized superficially to the enclosing fascia in the subcutaneous tissues (subcutaneous lipoma). However, lipomas may be restricted deep under the enclosing fascia; these are called deep-seated lipomas. The lipoma which originate within the muscles are referred as intra muscular lipomas [3]. Specific chromosomal aberrations such as translocation involving 12q13-15, interstitial deletion of 13q and rearrangement involving 6p21-23 had been described in intramuscular lipomas [4]. Universally tumors with complicated chromosome aberrations are affiliated with a poor disease course. Hence, to our knowledge it may be the first case to present cytogenetic review of an intraoral lipoma in a five year old child, a rare entity allowing clinician for appropriate treatment and prognosis.

Case Report

A five year old boy presented with a chief complaint of swelling in the right side of his face since one year, with no history of pain or pus discharge. His medical history was noncontributory. On extraoral examination, a diffused ovoid swelling of 3 x 2 cms was seen on the right middle and lower third of the face extending anteroposteriorly from the nasolabial fold to the tragus of ear and superoinferiorly from the zygomatic arch to ramus of the mandible (Figure 1). The overlying skin was normal in colour and texture. The swelling was more prominent with the teeth clenched and while contracting the masseter muscle (Figure 2)

There was no intraoral extension of the swelling. Ultrasonography revealed 3.2 x 1.4 x 2.7 cm fat echogenic lesion which is well encapsulated noted in the intramuscular plane on right side. The lesion shows no vascularity or calcifications. Underlying bone appears normal (Figure 3). Based on the above findings the tumor was provisionally diagnosed as intramuscular lipoma of the masseter muscle.

Surgical excision is the current treatment for oral lipomas. The surgical approach is dependent on the site of the tumor and the desired cosmetic result. After explaining the entire procedure to the parents,

written informed consent was obtained. Intraorally, a wide excision of the tumor was done and the specimen was sent for histopathological evaluation. The postoperative period was uneventful.

Histopathological examination disclosed the presence of sheets of mature adipocytes containing clear cytoplasm and eccentric nucleus, with no evidence of cellular atypia or metaplasia. A distinct lobular arrangement of the cells was seen, with intervening fibrovascular connective tissue septa. Based on the histopathological features, a final diagnosis of intraoral lipoma was considered (Figure 4). There has been no recurrence during one year follow up period and we continue to monitor the patient regularly.

Discussion

Lipomas are benign mesenchymal tumors peculiarly in trunk and proximal portions of the extremities but they are rare tumors of oral cavity [5]. Literature shows that the peak incidence occurs in the fifth or sixth decade of life whereas, rare cases of congenital lipomas had been reported in 20-day and 47-day old babies [6,7]. Clear gender prediction has not been currently accomplished however there is a female predominance in majority of studies where intramuscular lipomas were separately evaluated [8,9], while literature showing equal sex distribution with a male-female ratio of 1:1.2 has also been reported [7] but in the present case report the patient was a five year old male child patient. Intraoral counterparts are rare; most common site of oral lipomas is the oral mucosa, a region rich in fatty tissue, followed by the tongue, lips, floor of the mouth, palate, and gingiva which corresponds to the quantity of fat deposits in the oral cavity [4]. The etiology remains unclear, probably the suggested pathogenic mechanisms include the “hypertrophy theory” which states that obesity and inadvertent growth of adipose tissue may contribute to

***Corresponding author:** Harika R, Department of Pedodontics and Preventive Dentistry, Dr. NTR University of Health Sciences, Mamata Dental College, Khammam, Telangana, India, Tel: 09948213219; E-mail: harika_rapala@yahoo.com

Received June 08, 2016; **Accepted** June 22, 2016; **Published** June 30, 2016

Citation: Harika R, Daneshwari V, Arun P, Teja PR (2016) Chromosomal Aberrations of a Pediatric Intra Oral Lipoma: A Rare Case Report and Cytogenetic Forecasting. *Pediatr Dent Care* 1: 112. doi: [10.4172/2573-444X.1000112](https://doi.org/10.4172/2573-444X.1000112)

Copyright: © 2016 Harika R, et al. This is an open-access article distributed under the terms of the Creative Commons Attribution License, which permits unrestricted use, distribution, and reproduction in any medium, provided the original author and source are credited.

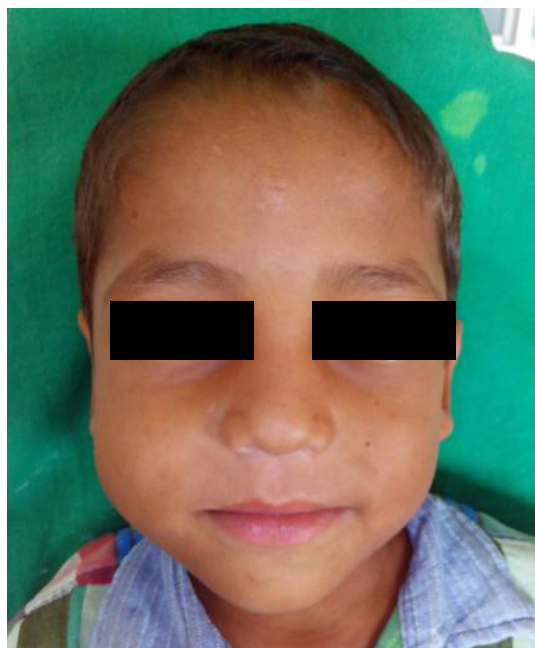

Figure 1: A diffuse extra-oral swelling in the middle and lower one third of face.

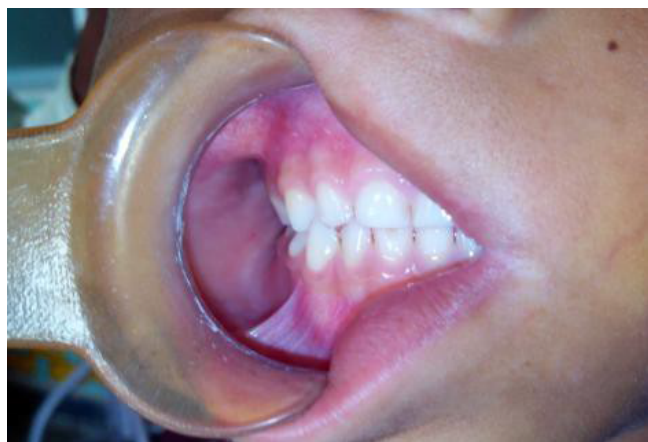

Figure 2: Introral examination reveals a prominent mass on clenching.

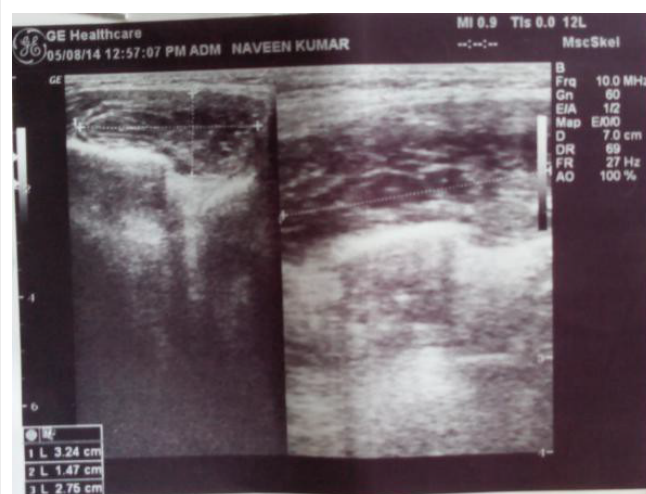


Figure 3: Ultrasound imaging showing hyperechoic mass compared to adjacent muscle.

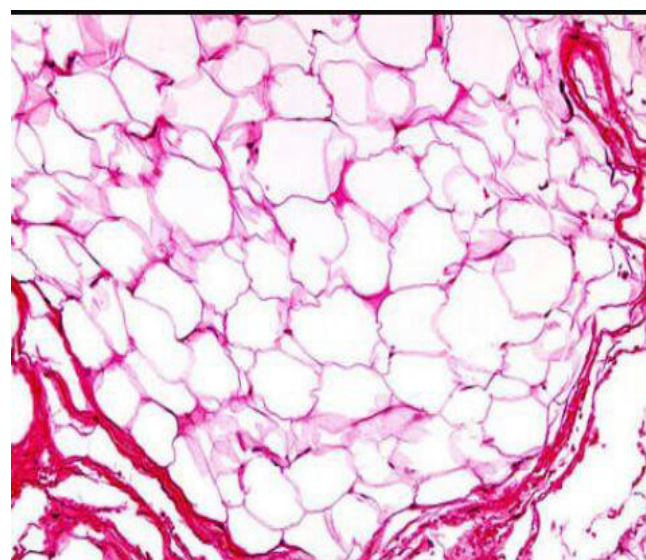


Figure 4: Histopathological examination revealed lobules of mature fat cells surrounded by thin fibrous connective tissue septa.

formation of these oral lipomas however this theory is less convincing in explaining those lesions occurring in areas destitute of preexisting adipose tissue. Another theory known as “metaplasia theory” suggests that lipomatous development occurs due to aberrant differentiation of in situ mesenchymal cells into lipoblast, since fatty tissue can be derived from mutable connective tissue cells almost anywhere in the body [10]. Trauma, chronic irritation, obesity, developmental disorders, endocrine, dysmetabolic and genetic factors provoking the uncontrolled growth of lipomas have all been suggested to play a possible role in the development of intramuscular lipomas [11]. Aberrant high mobility group proteins have been reported to play a role during the development of lipomatous tumors [12]. Morphologically intraoral lipomas can be classified as diffuse form affecting the deeper tissues, superficial form and encapsulated form [1]. The tumour is usually non-tender, soft, and almost typically superficial in depth; but may infiltrate the muscle, become fixed to the surrounding tissue, and, therefore, unmovable as seen in the present case. Deeply occurring

lesions may produce only a slight surface elevation and may be well encapsulated, more diffuse, and less delineated than the superficial variety. This more diffuse form generates the clinical impression of a fluctuant tumor. The consistency of the lesion varies from soft to firm depending on the quality and distribution of fatty tissue and the depth of the tumor. Because of these clinical features, other lesions, such as oral dermoid and epidermoid cysts and oral lymphoepithelial cysts, must be considered in the differential diagnosis of oral lipomas [13]. The deeper lipomas need to be assessed by means of imaging modalities to establish a diagnosis, define the size, location and relationship with adjacent muscle as well as to determine operative plan as seen in our case. There are no large studies evaluating the ultrasound characteristics of intramuscular lipomas independently. Acoustic transmission compared to adjacent muscle was increased in the majority of cases but was found to be equal and decreased in some cases. Most of the lipomas presented with fine internal echoes oriented parallel to the long axis of

the tumor. The majority of lipomas had no internal vascularity as seen in the present cases on ultrasound although some of them expressed mild and minimal vascularity. Tumors with entrapped muscle fibers may appear heterogeneous and will have internal striations on ultrasound imaging [11]. Although histological diagnosis is the gold standard for diagnosis of lipomatous tumors, specific chromosomal abnormalities had been described in intramuscular lipomas to predict the disease course. Bassett et al. found that the cytogenetic studies of intramuscular lipomas unveiled simple translocations or loss of chromosomal material involving the q14-15 region on chromosome 12, paracentric or pericentric inversions of chromosome 12q14-15, aberrations involving 6p21-22, or loss of material from the q12-14 or q22 region of chromosome 13. The rearrangements involving 12q14-15 and 6p21-22 lead to over expression of HMGIC and HMGIY, respectively. The proteins encoded by these genes are high mobility group proteins that are involved in determining chromosomal structure and are known to affect gene expression globally [14]. Lipomas are frequently characterized by aberrations of the 12q13-q15 chromosomal region and often by rearrangements of the HMGA2 gene. These rearrangements include the organization of chimeric genes that fuse the 5' region of HMGA2 with a variety of partners, such as LPP (3q28) or NFIB (9p22), a HMGA2-NFIB fusion and a translocation t(9;12) (p22;q14) in a deep seated intramuscular lipoma [15]. Bao et al. reported a case of a three-way translocation t(1;4;12) (q25;q27;q15) as the sole chromosomal abnormality in an 8-year-old girl with an intramuscular lipoma [16]. Other studies showed abnormalities involving chromosome region 12q13-15 specifically translocations with 3q27-28, 1p32-34, 21q21-22, 2p21-23, and other non-recurrent rearrangements. Abnormalities not involving 12q13-15 include lipomas with deletion 13q, ring chromosomes, and rearrangements of 6p21-23, 11q13, 1p36, and 13q12-q22 [17].

Conclusion

Although further knowledge is needed to better interpret the spectrum of cytogenetic characteristics of lipomatous tumors broadly and intramuscular lipomas in final, it is decipherable that cytogenetic analysis can be of diagnostic value in histologically borderline or difficult cases.

Why this Paper is Important to Pediatric Dentist

As cytogenetic analysis is quickly becoming an inbuilt part of the diagnostic work up it helps in predicting the disease course before its occurrence. To our knowledge this is the first paper to provide knowledge regarding the genetic aspects of intraoral lipomas.

Authors' Contribution

Study concept and design: Dr. Rapala Harika. Acquisition of data: Dr. V. Daneshwari. Analysis and interpretation of data: Dr. Arun Parsa. Drafting of manuscript: Dr. Raveen Teja P.

References

1. Rajendran R, Sivapathasundharam B (2009) Shafer's textbook of oral pathology, (6th edn) Elsevier, India.
2. Hatziotis JC (1971) Lipoma of the oral cavity. *Oral Surg Oral Med Oral Pathol* 31: 511-524.
3. Billing V, Mertens F, Domanski HA, Rydholm A (2008) Deep-seated ordinary and atypical lipomas: histopathology, cytogenetics, clinical features, and outcome in 215 tumours of the extremity and trunk wall. *J Bone Joint Surg Br* 90: 929-933.
4. Kumaraswamy SV, Madan N, Keerthi R, Shakti S (2009) Lipomas of oral cavity: case reports with review of literature. *J Maxillofac Oral Surg* 8: 394-397.
5. Nayak S, Nayak P (2011) Lipoma of the oral mucosa: a case report. *Arch Orol Sci* 6: 37-39.
6. Fornage BD, Tassin GB (1991) Sonographic appearances of superficial soft tissue lipomas. *J Clin Ultrasound* 19: 215-220.
7. Dimitrakopoulos I, Zouloumis L, Trigonidis G (1990) Congenital lipoma of the tongue. Report of a case. *Int J Oral Maxillofac Surg* 19: 208.
8. Austin RM, Mack GR, Townsend CM, Lack EE (1980) Infiltrating (intramuscular) lipomas and angiolipomas: a clinicopathologic study of six cases. *Arch Surg* 115: 281-284.
9. Fletcher CD, Martin-Bates E (1988) Intramuscular and intermuscular lipoma: neglected diagnoses. *Histopathology* 12: 275-287.
10. Kumar LKS, Kurien NM, Raghavan VB, Menon PV, Khalam S, et al. (2003) Can intramuscular lipoma have a post-traumatic origin? *Br J Dermatol* 149: 1084-1085.
11. McTigue S, Chernev I (2014) Intramuscular lipoma: a review of the literature *Orthop Rev* 6: 5618.
12. Mori K, Chano T, Matsumoto K, Ishizawa M, Matsusue Y, et al. (2004) Type selective muscular degeneration promotes infiltrative growth of intramuscular lipoma. *BMC Musculoskelet Disord* 5: 20.
13. Agarwal P, Patil S, Chaudhary M (2014) A Rare Case of Introral Lipoma in a 33 Months Old Child and a review. *Dentistry* 4: 215.
14. Bassett MD, Schuetze SM, Distech C, Norwood TH, Swisshelm K, et al. (2005) Deep-seated, well differentiated lipomatous tumors of the chest wall and extremities: the role of cytogenetics in classification and prognostication. *Cancer* 103: 409-416.
15. Pierron A, Fernandez C, Saada E, Keslair F, Hery G, et al. (2009) HMGA2-NFIB fusion in a pediatric intramuscular lipoma: a novel case of NFIB alteration in a large deep-seated adipocytic tumor. *Cancer Genet Cytogenet* 195: 66-70.
16. Bao L, Miles L (2005) Translocation (1;4;12)(q25;q27;q15) in a childhood intramuscular lipoma. *Cancer Genet Cytogenet* 158: 95-97.
17. David-Padilla C, Wang EHM, Cutiongco-De la Paz EM, Cadag NS (2009) Cytogenetic analysis of primary bone and soft tissue tumors in Filipino Patients. *Acta Medica Philippina* 43: 7-11.