

Congénitale Malformations of the Nose

Nouri H* and Raji A

Department of ENT, University Hospital of Marrakech, Morocco

*Corresponding author: Nouri H, Professor, Department of ENT, University Hospital of Marrakech, Morocco, Tel: 6365481; E-mail: nouri_orl@yahoo.fr

Received date: June 04, 2017; Accepted date: June 06, 2017; Published date: June 13, 2017

Copyright: © 2017 Nouri H, et al. This is an open-access article distributed under the terms of the Creative Commons Attribution License, which permits unrestricted use, distribution and reproduction in any medium, provided the original author and source are credited.

Citation: Nouri H, Raji A (2017) Congénitale Malformations of the Nose. Otolaryngol (Sunnyvale) 7: i004. doi:10.4172/2161-119X.1000i004

Introduction

Nasal development is the result of a complex embryologic patterning and fusion of multiple primordial structures. Loss of signaling proteins or failure of migration or proliferation can result in structural anomalies with significant cosmetic and functional consequences. The nasal malformation on these clinical images is exceptional. In our knowledge it has never been described in the literature. It is secondary to the non-fusion of the upper edge of the greater alar cartilage to the lower edge of the lateral cartilage (Figures 1-4).

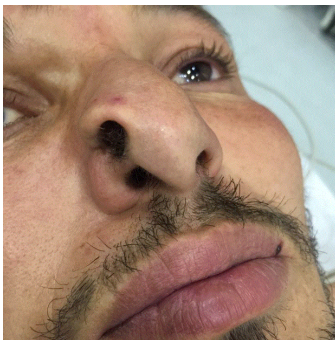

Figure 1: Photo showing the malformation: Dual orifice of the right naris.

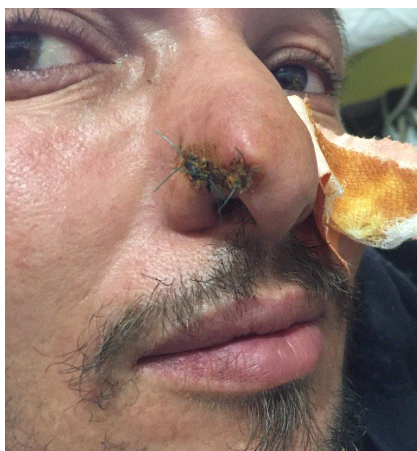

Figure 2: Two days after surgery.

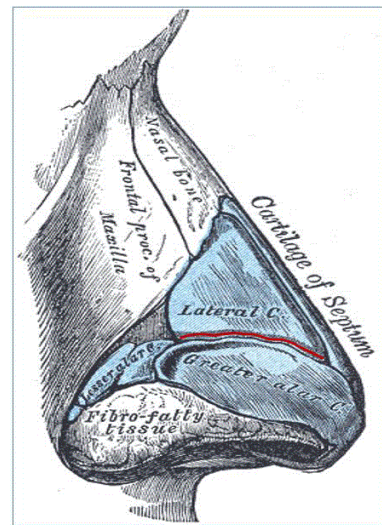


Figure 3: The anatomical area affected by malformation.

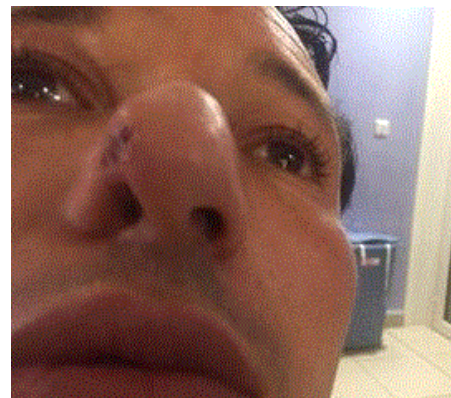

Figure 4: Result two week after surgery.

The surgery consists of dissection of the lower edge of the lateral cartilage and the upper edge of the greater alar and ensure the recapture of both cartilage: suture of the nasal mucosa, a noued between the two cartilages, finally suture of the skin.