

## Effectiveness of the Multiple Use of Self-expanding Prostheses in Patients with Oesophageal Tumor Overgrowth: Case Report

Yanet Ortega Dugrot<sup>1</sup>, Raúl A Brizuela Quintanilla<sup>2\*</sup>, Norberto Alfonso Contino<sup>2</sup>, Mayté López Ruiz<sup>1</sup>, Ana Doris Quesada Roque<sup>1</sup> and Marlene Felipe Miranda<sup>1</sup>

<sup>1</sup>Ministry of Public Health, National Center for Minimal Access Surgery, Havana, Cuba

<sup>2</sup>Second Degree Specialist in Gastroenterology, Ministry of Public Health, National Center for Minimal Access Surgery, Havana, Cuba

\*Corresponding author: Dr. Raúl A Brizuela Quintanilla, MD, PhD, Professor, Second Degree Specialist in Gastroenterology, Ministry of Public Health, National Center for Minimal Access Surgery, Havana, Cuba, Tel: 5376495328, +53 52424595; Fax: 5376490150; E-mail: [raulab@infomed.sld.cu](mailto:raulab@infomed.sld.cu)

Received date: November 02, 2018; Accepted date: January 01, 2019; Published date: January 10, 2019

Copyright: © 2019 Dugrot YO, et al. This is an open-access article distributed under the terms of the Creative Commons Attribution License, which permits unrestricted use, distribution, and reproduction in any medium, provided the original author and source are credited.

### Abstract

Oesophageal cancer is one of the most aggressive neoplasms of the digestive tract, with high morbidity and mortality. According to histology, squamous cell carcinoma and adenocarcinoma are among the most common, constituting 90% of esophageal neoplasms patients with unresectable tumors with metastasis presence or with medical contraindications for surgical treatment with a less than three month survival; there are several palliative therapies available for this kind of patients in order to improve swallowing as much as possible, as well as the placement of multiple self-expanding metal esophageal stents to improve digestive transit in cases of stenosis and recurrence of dysphagia due to tumor overgrowth. A case report is presented with the aim of assessing the effectiveness of multiple self-expanding prostheses placement in a patient with esophageal tumor overgrowth.

The patient was continuously assessed over a period of three years. According to the international literature, it has been shown that the insertion of new coated prostheses prevents or delays obstruction. The patient was assessed by a follow-up study: a week, a month and six months later. Then, she was regularly assisted in the out-patient department with this aim, the European Organization for Research and Treatment of Cancer Quality of Life Questionnaire-Core 30 (EORTC QLQ-C30) and its EORTC QLQ-OES18 (European Organization for Research and Treatment of Cancer Quality of Life Questionnaire Oesophagus-specific-18) EORTC complement were applied, in order to improve the life quality according to the patient's perception.

**Keywords:** Life quality; Cancer patient; Multiple self-expandable endoprotheses; Esophageal cancer

### Introduction

Oesophageal cancer is one of the most aggressive neoplasms of the digestive tract, with high morbidity and mortality. According to histology, squamous cell carcinoma and adenocarcinoma are among the most common, constituting 90% of esophageal neoplasms [1]. On the tumor location, this predominates in the distal esophagus, esophagogastric junction and it is closely related to Barrett's esophagus, generally related to gastroesophageal reflux disease and obesity.

Squamous cell carcinoma has as risk factors the smoking habit, alcoholic beverage intake, food ingestion at extreme temperatures, hereditary tylosis, the presence of esophageal diverticula, long-term achalasia, esophageal stenoses caused by the ingestion of caustics, as well as such as Vinson Plummer Syndrome and human papillomavirus infection [2].

From a clinical point of view, esophageal tumors show minor symptoms. Dysphagia is more frequent in solids and then in liquids, which can lead patient's complications such as impaction of the food bolus. Other manifestations can be anorexia, weight loss, odynophagia, nausea, vomiting, and high digestive bleeding.

Patients with unresectable tumors with metastasis presence or with medical contraindications to undergo surgery with a less than three

month survival; there are several palliative therapies available for this kind of patients in order to improve swallowing as much as possible, as well as the self-expanding metal esophageal stents placement to improve digestive transit in case of stenosis due to tumor growth [3].

The National Center for Minimally Accessive Surgery focuses its study on advanced endoscopic therapy with a lot of experience for more than 170 prostheses placed in patients with unresectable esophageal tumor with good results [4].

At present, this health center has gained experiences on a variety of endoscopic therapies to be performed on these patients after having complications; in case the tumor overgrowth is not considered a defeat, the placement of multiple self-expanding esophageal prostheses should be taken into consideration, without performing other varieties of palliative treatments such as gastrostomies, jejunostomies and gastrojejunostomies.

These palliative treatments require admission, demand for nursing care and training for family caregivers [5]. Hence, the importance of assessing life quality on cancer patient with multiple self-expanding prostheses leads to describe some clinical and demographic variables; to compare aspects related to the state of health, wellbeing before and after the placement of the self-expanding esophageal endoprosthesis on the studied patient and to identify the possible complications and endoscopic therapy that is proposed.

In this case study the author has presented a case of carcinoma oesophagus, managed by multiple self-expanding stents. Oesophageal cancer is one of the most aggressive neoplasms of the digestive tract,

with high morbidity and mortality. This case report is presented with the aim of assessing the effectiveness of multiple self-expanding prostheses placement in a patient with oesophageal tumor overgrowth. The patient was continuously assessed over a period of three years.

## Case Report

A 64 year-old female patient, Cuban nationality, who was assisted on the classification consultation on March, 2016, in the gastroenterology classification clinic of the National Center for Minimally Access Surgery, complaining of dysphagia to solids and liquids, significant weight loss (more than 20 kg) and weak.

A physical examination was performed, confirming positive aspects such as pale mucous membranes, not corresponding with weight and height, to the anamnesis, a heavy smoker for more than 40 years and apparently healthy.

Fluoroscopy with water-soluble contrast (Compound Meglumine Ditrizoate) is indicated and full defect images are visualized, with stenosis in the esophageal body, so, follow-up endoscopic studies are indicated for better diagnosis and treatments.

It is relevant to clarify that the patient was included on the study after the second placement of self-expandable prosthesis, the first one was laid in 2015 and the second in 2017 respectively with an endoscopic view of the lesion at 33 cm that covered the entire light of the organ. The period between the two prostheses placement was a year and five months without complications.

During the course of her illness, four self-expanding prostheses were placed due to esophageal tumor overgrowth; the latter was placed after the decision of the research team, confirming at 25 cm an irregular stenosis with a mamelonating lesion that compromised 25% of the lumen which does not allow the passage of the equipment or let observe the upper edge of the prosthesis.

The fourth self-expanding metal prosthesis (BorBare-Type) of 80x26 mm was placed in a satisfactory manner. Then, we proceed to the dilatation of the stenosis site with pneumatic balloon, observing reflux of retention fluid so the retained fluid was aspirated.

## Ethical Procedures

The consent informed was applied to the patient to participate on the study and the publication of the article was authorized.

## Process

The patient was followed up weekly, monthly, and six months after the prosthesis placement in order to assess her life quality for this aim, the European Organization for Research and Treatment of Cancer Quality of Life Questionnaire-Core 30 instrument was used (EORTC QLQ-C30), prepared by the European organization for the investigation and treatment of cancer in 1993, consisting of a questionnaire of 30 questions divided into 3 areas: functional capacity (physical appearance, social role, cognitive ability, emotional and social factors), symptoms (asthenia, pain and nausea/vomiting) and global assessment.

The subscale of the EORTC QLQ-C30 to evaluate the patient with esophageal cancer in its transcultural adaptation is known as EORTC QLQ-OES18 (European Organization for Research and Treatment of Cancer Quality of Life Questionnaire Oesophagus-specific-18) created

in 1996, adapted for the Colombian population and used in six countries with satisfactory results.

This module contains specific questions about the symptoms that afflict patients with esophageal cancer, consisting of 18 items related to the ability of eating and drinking, mouth tasting, speaking, coughing, pain and symptoms of reflux. They have four Likert-scale response options, in which as higher score, higher complication level or worsening of the life quality [6].

## Results

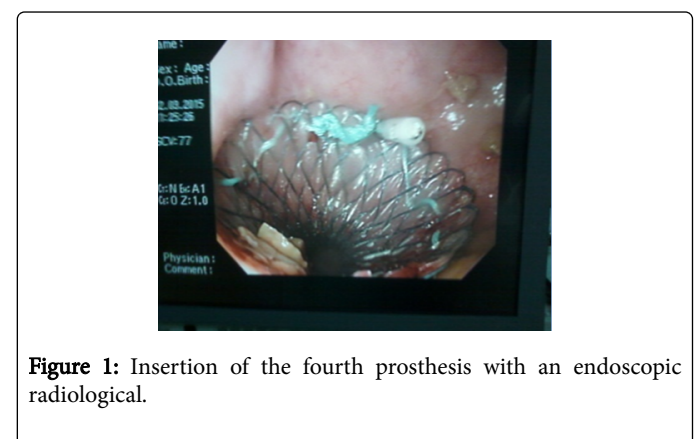
From the histological point of view, the lesion turned out to be Squamous Cell Carcinoma and with a negative evaluation by oncology, clinical and anesthesiology criteria for the proposed surgery. From the initial assessment of dysphagia described by Brown, the patient presented a resolution of the dysphagia and keep on the modified and strict diet in terms of mode and preparation of the food.

Taking into account the EORTC QLQ-C30 health-related life quality measurement instrument, there were improvements in the areas of functional capacity, mainly in emotional factors and symptoms; specifically pain. On the initial application of instrument complement module OES-18 the patient was in poor condition or getting worse in terms of symptoms related to the dysphagia and pain scale.

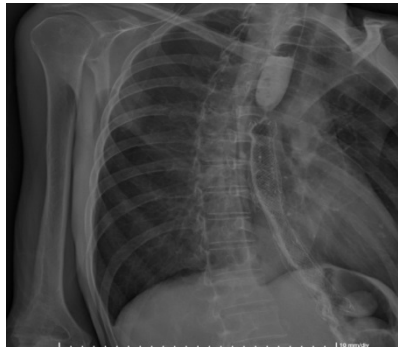At one month and three months after the prosthesis was placed, the patient was getting better. However, at six months there was a relapse according the established parameters. In the follow-up consultations up to three years, the evolution was stable without significant changes; there was no metastasis to neighboring structures or at a distance.

The insertion of multiple esophageal prostheses as palliative treatment has been satisfactory due to the achievement of enteral feeding and rapid adaptation to new diets, modifying modes and lifestyles after presenting this para normative event. The result is shown in the Figures 1 and 2 corresponding to the insertion of the fourth prosthesis with an endoscopic (1) and radiological (2) vision.

There is a relationship between the appearance of complications (tumor overgrowth) and the presence of complications (pain) in the patient follow-up evaluations. The pain disappeared gradually with the psychological sphere support and the administration of oral analgesics, not exceeding seven days of medicine administration. These procedures were performed on an outpatient basis [Table1].



**Figure 1:** Insertion of the fourth prosthesis with an endoscopic radiological.



**Figure 2:** Insertion of the fourth prosthesis with an endoscopic vision.

The results coincide with that of proposed by Kujawski et al. in with there was a minimum of complications, chest pain predominated in patients with lesions in the middle esophagus [7,8].

Before	One month	Three months	Six months
Afagia	Dysphagia for solids	Dysphagia for solids	Aphage

**Table 1:** Evaluation of the dysphagia described by Brawn in the first six months of the patient's incorporation into the study.

After six months she remained with dysphagia for solids up to present [Table 2].

Measuring instrument of life quality	Before	One month	Three months	Six months	One year
EORTC QLQ-C30	52.6	48.2	45.5	95.8	88.5
OES-18	48.6	44.4	43	68	56

**Table 2:** Life quality evaluation of the oncological patient with the application of multiple self-expanding prostheses according to the evaluation time.

## Discussion

In the majority of patients, esophageal cancer is diagnosed in advanced stages of the disease, being 10%-15% survival at five years. Dysphagia is a common complication that conditions a poor life quality of those patients in the terminal phase, in which palliative treatments is the primary objective with different therapeutic options [9,10].

Endoscopic therapies internationally applied with satisfactory results include gastrostomy, jejunostomy or gastrojejunostomy, esophageal endoluminal brachytherapy and esophageal stent implantation self-expandable. The latter being very useful in terms of improving dysphagia and patients' life quality in a short time period, increasing a greater likelihood of clinical success, shorter re-establishment time of the oral route, lower risk of perioperative complications and shorter hospital stay [11].

The palliation of dysphagia facilitates nutrition due to the continuity of oral feeding through self-expanding metal esophageal prosthesis, being reported in the literature 90% of patients with esophageal cancer with a total resolution of dysphagia after the placement of the prosthesis [12-14].

A study developed in Mexico City showed significant results on the improvements from the nutritional and functional point of view in patients who had undergone self-expanding prostheses and on others treated with nasal tubes and percutaneous gastrostomies [15].

Another retrospective study showed a greater tolerance to coadjuvant treatment and a lower percentage of weight loss in patients who underwent self-expanding prostheses over those who were treated with nasal-lateral tubes [16].

Siddiqui et al. reported in their study that patients with locally advanced esophageal cancer did not show significant changes on body weight one month after the prosthesis was placed [17].

According to Leclaire et al. they reported that there were no nutritional or functional improvements in patients with previous basal malnutrition one month after the prosthesis was placed, which shows the importance and concern about nutritional support from the beginning of the intervention [18]. With the patients in order to improve their life quality [14].

According to studies carried out by Ortega et al. in a preliminary section of thirteen patients, there was a resolution of dysphagia in 100% of the cases studied and improvements in life quality after the placement of self-expandable endoprostheses with a minimum of complications [19].

Since ancient times, technological development has favored the development of self-expanding prostheses due to its advantages, characteristics, antireflux mechanism, design, coating system and the variety of materials.

Bioabsorbable and the well-known nitinol metal prostheses; the latter are frequently used in advanced oncological pathologies, since their design allows their complete integration with the tissue, not being a complication in patients with short survival, to whom the removal of the prosthesis is not planned. There are also recent publications that report the use of self-expanding prostheses covered with silicone in neoplastic pathologies.

The obstruction of the prosthesis due to tumor growth can easily be solved endoscopically, with the insertion of new coated prostheses that prevent or delay the obstruction. It is important to highlight that the success of the reported case due to the natural evolution of the tumor towards the high esophagus, not affecting the entire cardiac region, which makes it easier for the patient to reduce late complications and it

leads researchers to take a variety of decisions. The success also depends on the correct selection of the prosthesis to be used from the first insertion with a futuristic vision about complications as it is described in the literature [20-22].

Treating the complications presented endoscopically with satisfactory results, it must be remembered that the organism; despite being the same, does not react in the same way when several complications occur, reducing the time between one event and another, each time it makes it harder to recover from the symptoms and signs that afflict it.

Another aspect is the attention to the psychosocial sphere, taking into account that the disease in the terminal stage affects the patient and his or her immediate environment, since the palliative treatment proposed and the side effects influence the new adaptation.

Some of the most frequent reactions such as fear, denial, anxiety, guilt, isolation, dependence and sadness are feelings that can interfere with the normal diet of the individual and show symptoms, such as anorexia. Depression can also appear, which is different from the feeling of sadness and can also have a great impact on the nutritional status of the individual.

This event leads to an impact in the socioeconomic sphere since the fact of getting sick brings about a decrease in the patient's purchasing power, by the income reduction due to the labor loss and increase in the expenses due to new necessities like getting rid of architectonic barriers, changes of address, diets, transport, and the demand for cares that it brings about. In some occasions the family caregiver has stopped working in order to take care of the patient and to dedicate time to the patient in terms of care, because of the demand generated by the event. The loss of purchasing power joins the socio-economic problems of the financial crisis. This has been related to changes in the food consumed by the population, especially in vulnerable groups. The price of food influences the consumers' choice and can be a barrier to low-income families getting to more expensive and healthier food. So, it is necessary to advise families with low income, knowledge and skills to acquire training on the menu preparation and recipes according to the family budget. This is an interesting solution.

Therefore, the patient environment, the persons who he lives with, who prepares the meals, where he eats and what food he usually purchases should not be very important to know the patient's culture and religion in order to respect food customs. The aspects mentioned before are fundamental for improving the patient's life quality and making the survival period longer [14,23].

## References

1. Rendón J, Oliveros R, Sánchez R (2016) Mortality in patients with esophageal and gastroesophageal tumors treated with self-expandable stents. *Rev Fac Med* 64:493-498.
2. Lever-Rosas CD, Silva-Ortiz J, Limón-Alfárez B, Aguilar-Garibay JE, Pérez-Rodríguez JA, et al. (2014) Application of endoprosthesis in the upper gastrointestinal tract in cancer patients. *Rev Sanid Milit Mex* 68:138-147.
3. Fierro García I, Gómez Cuadros A (2017) quality of life of patients after a total laryngectomy [Tesis]. Madrid, España: Faculty of Medicine, Autonomous University of Madrid.
4. Ruiz Torrez JF, Brizuela Quintanilla RA, Piñol Jiménez FN, García-Menocal Hernández JL (2015) Experience of the use of self-expanding metal endoprostheses in the esophagus. *Cub J Sur* 54: 342-8.
5. Oliva Anaya CA, Mederos Curbelo ON, García Sierra JC, Barrera Ortega JC, Castellanos González JA (2016) Nutritional support and quality of life in patients with esophagus and cardia cancer. *Cub J Sur* 55: 97-105.
6. Sánchez Ricardo OJ, Venegas M, Sánchez O (2009) Transcultural adaptation of two scales used to measure quality of life among cancer patients in Colombia: EORTC QLQ-C30 and QLQ-BR23. *Col J Cancerol* 13: 205-212.
7. Kujawski K, Stasiak M, Rysz J (2012) The evaluation of esophageal stenting complications in palliative treatment of dysphagia related to esophageal cancer. *Med SciMonit* [Internet] 18: CR323-CR9.
8. McGrath EE, Warriner D, Anderson P (2012) Implantation of self-expanding metal prostheses with flexible bronchoscopy under sedation for malignant tracheobronchial stenosis: retrospective analysis of a single RSS center. *Arch Bronconeumol* 48: 43-48.
9. Lettmaier S, Strnad V (2014) Intraluminal brachytherapy in oesophageal cancer: defining its role and introducing the technique. *J Contemp Brachytherapy* 6:236-241.
10. Siersema PD, Vleggaar FP (2010) Esophageal strictures, tumors, and fistulae: alternative techniques for palliating primary esophageal cancer. *Tech GastrointestEndosc* 12: 203-209.
11. Castilla L, Rovirosa Á, Ginès À, Pages M, Camacho C, et al. (2015) Endoluminal brachytherapy in the treatment of oesophageal cancer. Technique description, case report and review of the literature. *Rev Esp Enferm Dig* 107: 449-453.
12. Benjamin R A, Sharma P (2016) Esophageal Cancer. *Gastroentrol Clin* 45: 399-412.
13. Prabhu A, Obi KO, Rubenstein JH (2014) The Synergistic effects of alcohol and tobacco consumption on the risk of esophageal squamous cell carcinoma: A Meta-Analysis. *Am J Gastroenterol* 109: 822-827.
14. Sendros Madrono MJ (2016) Dietetic aspects in special situations of the oncological patient. Prebiotics and probiotics, do they have a place in the nutritional therapy of the oncological patient? *NutrHosp*. 33: 17-30.
15. González AD, CossioSdra S, Figueroa EB, Hernández GA (2014) Superiority of esophageal prostheses over nasoenteric tubes to maintain nutritional status and improve functional status in patients with advanced esophageal cancer.
16. Bower M, Jones W, Vessels B, Scoggins C, Martin R (2009) Nutritional support with endoluminal stenting during neoadjuvant therapy for esophageal malignancy. *Ann Surg Oncol* 16: 3161-3168.
17. Siddiqui AA, Sarkar A, Beltz S, Lewis J, Loren D, et al. (2012) Placement of fully covered self-expandable metal stents in patients with locally advanced esophageal cancer before neoadjuvant therapy. *Gastrointest Endosc* 76: 44-51.
18. Leclaire S, Di Fiore F, Antonietti MA, Sousan EB, Hellot MF, et al. (2006) Undernutrition is predictive of early mortality after palliative self-expanding metal stent insertion in patients with inoperable or recurrent esophageal cancer. *Gastrointest Endosc* 64: 479-484.
19. Ortega DY, Brizuela Quintanilla RA, Alfonso Contino NC, García-Menocal Hernández JL, Ruiz Torres JF, et al. (2018) Evaluation of the patients life quality with esophageal cancer treated with self-expanding stent. *Acta Scientific Gastroenterol* 1:9-12.
20. Eduardo VR (2010) Endoscopic palliation of gastric cancer. *Colombia Rev Col Gastroenterol* 25.
21. Barreto JA, Lizcano JH, Bolívar F, Mejía BA, González HH, et al. (2016) Case report: tracheoesophageal fistula and delayed respiratory insufficiency after self-expanding metal stent in the esophagus. Treatment with Dumon tracheal stent. 2013. *Cuban J Surg* 55: 97-105.
22. Blanco PN, Antequera JR, Rodríguez FL, Ibáñez GE, Herrero Saladody TF, et al. (2014) Emotional and psychopathological alterations in laryngectomized cancer patients. *Spanish Otorhinolaryngological Act*.
23. Social work model on cancer care. (2004) Social work of the Catalan Institute of Ecology, Barcelona: Generalitat de Catalunya.