



## Evaluating Brain Lesions: Adding to the Eyes to Thighs protocol of imaging imaging for 18FDG-PET

Rifaat Hussain\*

Department of Government and Public Policy Pakistan, National University of Sciences and Technology, Islamabad, Pakistan

### Abstract

Practices guidelines for PET-CT (positron emission tomography with computed tomography) imaging for oncology dictates acquiring images from the base of the skull to mid-thigh (eye to thigh protocol), excluding imaging the brain. The accepted reason being given that brain, because of its high metabolism and exclusive glucose use, will "hide" lesions. Other positron emitting radionuclides have been rightly developed for its imaging, mainly Carbon-11 methionine, fluorine-18 fluoroethyltyrosine (18F-FET), fluorine-18 dihydroxyphenylalanine (18F-FDOPA). The authors however argue that including the brain in the imaging protocol adds no extra radiation burden to the patient and adds on only a little on the acquisition time, however the benefit yield can add acknowledged benefits and sometimes change management paradigms.

**Keywords:** 18FDG PET-CT; Brain lesions; Eyes to thighs protocol

### Background and Introduction

Positron Emission Tomography (PET) using 18 F-Fluorodeoxyglucose (FDG) has been used for staging and restaging of several cancers. It has been recommended as the first line imaging modality in staging, restaging and response assessment of different cancers.

Procedural guidelines from best practices guides for an oncological PET scan acquisition, confer on, imaging the body from the base of the skull to the mid thighs (from the "eyes to the thighs"), unless otherwise indicated for tumors that show a high probability of metastases in the head, skull, brain and lower extremities [1-3].

The acquisition protocols at our Centre dictate image acquisitions to include the skull, and we have presented here cases showing the advantage of such a protocol where lesions were identified in the brain in patients who either had no symptoms or vague symptoms for the same and hence there was no indication of any disease thereof.

The authors argue the case for including the skull in the PET-CT imaging which can be done with no significant constraints on total acquisition time, activity injected or radiation burden to patient or staff. The advantage offered towards tumor staging, response to treatment, and management decisions advocate the notion.

Presented below is a series of patients that had been referred to our department for routine staging, restaging, treatment response or follow-up of their disease conditions. All patients were scanned from the vertex to mid thighs with FDG and reported here are the findings for their brain images followed by MRI for further evaluation.

### Case-1

65-year-old male diagnosed with squamous cell carcinoma of distal esophagus, status-post chemotherapy and radiotherapy was sent for evaluation of his treatment response. Images of PET-CT head revealed a focal hyper metabolic area in the posterior fossa, involving cerebellar vermis, predominantly on the left of midline. Rest of the scan only delineated primary tumor. His plain Magnetic Resonance Imaging (MRI) brain showed an ill-defined hyper intense area corresponding to the site of focal abnormal uptake on the metabolic scan. This

appeared hyper intense on both T2-weighted (T2W) and FLAIR (fluid attenuation inversion recovery) images. It was associated with adjacent hyper intense signals extending into the cerebellar folia. These findings were suggestive of a metastatic deposit (Figure 1). The patient gave no sign or symptom of any neurological abnormality.

### Case-2

47-year-old female, with carcinoma of breast, status-post chemotherapy and radiotherapy 6 months back, was sent for evaluation treatment response. Patient gave complains of vague headaches. Her PET-CT showed ipsilateral axillary lymph node, hepatic and splenic metastasis. The imaged brain revealed focal hypo metabolic area along the right front parietal region with adjacent calcification on corresponding CT images. Complimentary MRI demonstrated a Dural based, extra axial lesion which appears hypo intense on T1-weighted (T1W) and hyper intense on T2W and FLAIR images. As there was no perilesional edema, the findings were in favor of a benign meningeal based lesion likely meningioma (Figure 2).

### Case-3

38-year-old female, diagnosed case of ovarian carcinoma, status post total abdominal hysterectomy and bilateral salpingo-oophorectomy given chemotherapy (8 cycles initially followed by another 6 for recurrence) completed 6 months back was referred to us for suspicion of active disease because of rising tumor marker levels (CA-125).

Her PET CT scan revealed metastatic retroperitoneal lymph nodes suggesting recurrence.

\*Corresponding author: Rifaat Hussain\*, Department of Government and Public Policy, Pakistan, National University of science and Technology, Islamabad, Pakistan; E-mail: riffat214@gmail.com

Received February 27, 2021; Accepted March 13, 2021; Published March 27, 2021

Citation: Hussain R. (2021) Evaluating Brain Lesions: Adding to the Eyes to Thighs, Protocol of Imaging for 18FDG-PET. J Oncol Res Treat 6: 159.

Copyright: © 2021 Hussain R. This is an open-access article distributed under the terms of the Creative Commons Attribution License, which permits author and source are credited. And reproduction in any medium provided the original.

The brain images revealed a hypo metabolic area in the right frontal lobe with a hyper dense rim on CT correlate with surrounding vasogenic edema representing a likely metastatic lesion. As cystic metastasis do

not show FDG avidity, an MRI was advised which revealed rounded abnormal signal intensity area appearing hyper intense on T2W images with peripheral rim of hypo intense signals and perilesional edema

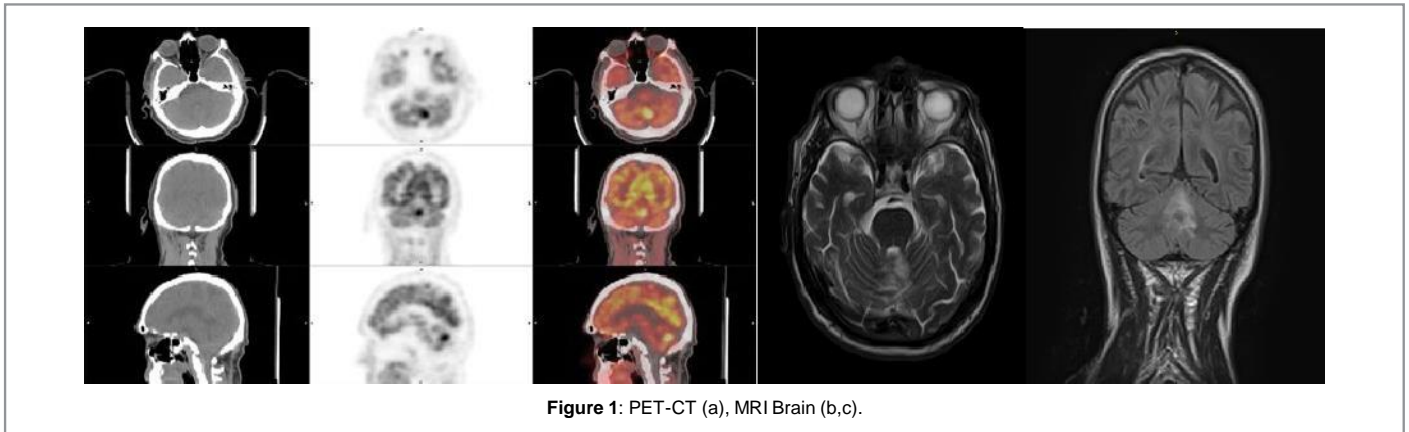


Figure 1: PET-CT (a), MRI Brain (b,c).

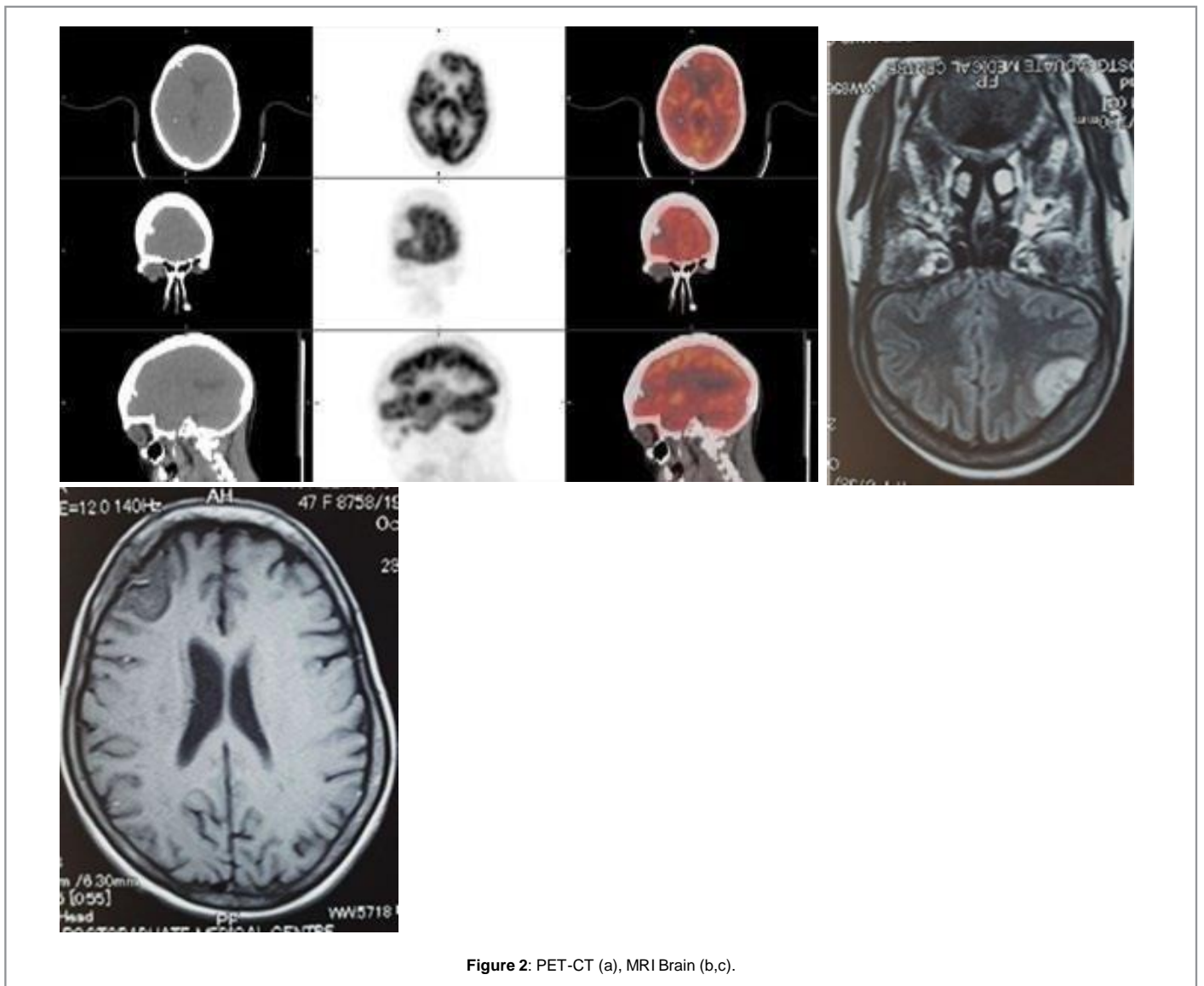


Figure 2: PET-CT (a), MRI Brain (b,c).

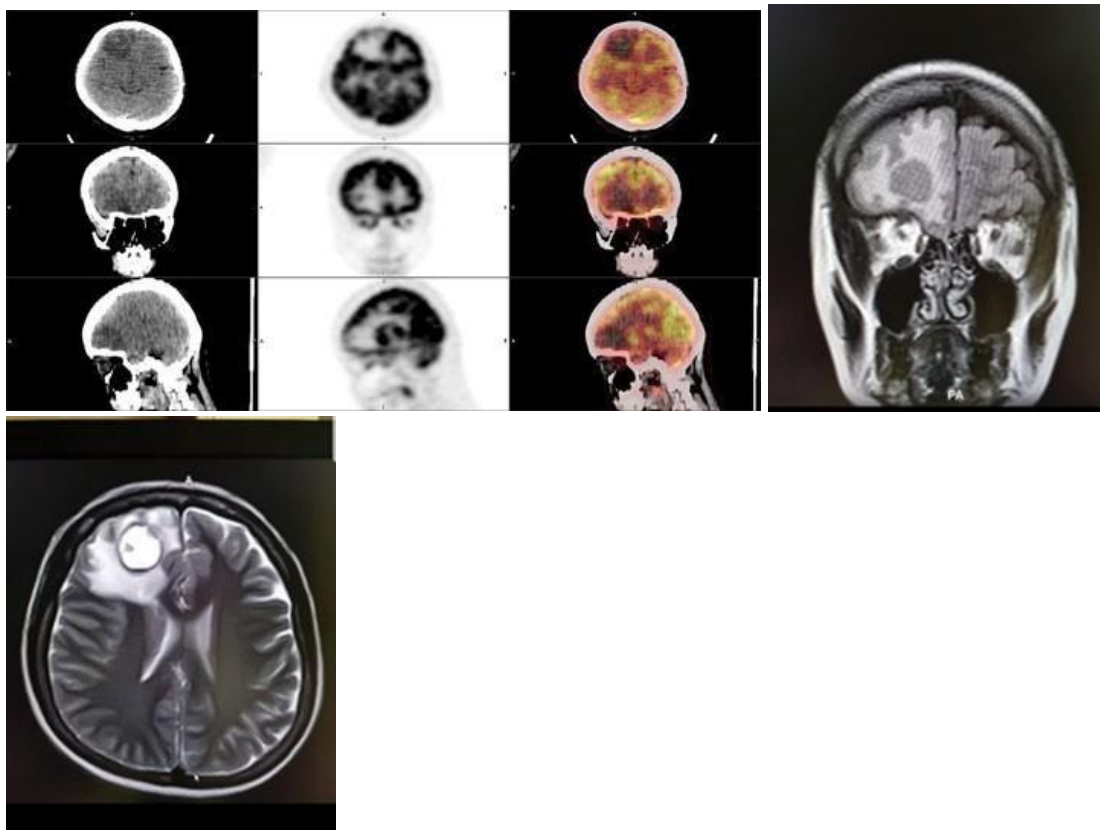


Figure 3: PET-CT (a), MRI Brain (b,c).

suggestive of metastases (Figure 3).

## Results and discussion

Metastases to the brain can affect about 10-20% cancer patients especially those with cancers of the lung, breast. Greater understanding and advances towards treatment associated with better and more sensitive diagnostic imaging technique have led improved survival rates and hence more cases of delayed brain metastasis [3,4]. Early detection of brain involvement is essential so help in curbing the therapeutic strategy and ascertain prognosis. Though contrast enhanced MRI remains the mainstay in the diagnosis, computerized tomography (CT) has also been deployed to assess metastasis. These modalities are however used when there is suspicion, symptoms or risk for the brain metastasis [5-7].

Positron emission tomography using FDG has been used for staging and restaging of several cancers. It has been recommended as the first line imaging modality in staging, restaging, response assessment and follow-up of different cancers.

Both the SNMMI and EANM procedural guidelines for an oncological PET scan acquisition confer on imaging the body from the base of the skull to the mid thighs ("from the eyes to the thighs" or the "lips to the hips"), unless otherwise indicated for tumors that show a high probability of metastases in the head, skull, brain and lower extremities [8]. Brain metastases, if seen on the PET-CT scanning, are identified as discrete hyper metabolic or hypo metabolic foci relative to the FDG uptake in the grey matter [7].

The role of FDG PET in the detection of brain metastasis has been often questioned in literature and found to be limited. The reasons cited in literature for exclusion is that a total of 7% of the injected activity is taken up by the brain as the it exclusively uses glucose for all its metabolic functions, hence any lesion within this high background will ultimately be masked or lost altogether [5,6,8]. Also, there is a relatively lower sensitivity of FDG for brain metastases, due to limited spatial resolution of PET scanners [3]. Still there have been studies that have shown that inclusion of the head in the FDG PET-CT has benefits to offer in terms of identifying lesions in the region and aid in the further management of the studies [7].

The acquisition protocols at our center dictate image acquisitions to include the skull, and we have presented here cases showing the advantage of such a protocol where lesions were identified in the brain in patients who either had no symptoms or vague symptoms for the same. The lesions identified led to further investigation for the patients with the gold standard modality MRI [5,6] for confirmation of the lesions. MRI in all three cases confirmed the initial diagnosis of brain lesion and led to modification of treatment regimen which directly benefited the patients in all three cases.

The authors argue the case for including the skull in the imaging protocols of FDG PET-CT, as what little benefit that may be added varies heavily against the very little effort of inclusion and the final decisions of patient management.

## Conclusion

The aim of this cases series was to show the potential of PET CT to identify Brain metastasis in patients having no or vague symptoms and to argue the case of including the acquisition of the skull in the acquisition protocols of PET CT. The added imaging adds no significant constraints on total acquisition time nor does it involve additional activity injection resulting in radiation burden to patient or staff, however, it may serve to help identify tumor burden early and help in instituting adequate and timely management of the disease.

## References

1. Iagaru A, Mitra ES, Gambhir SS (2011) FDG-PET/CT in cancers of the head and neck: What is the definition of whole body scanning? *Mol Imaging Biol* 13: 362-367.
2. Huston SF, Abdelmalik AG, Nguyen NC, Farghaly HR, Osman MM (2010) Whole-body 18F-FDG PET/CT: The need for a standardized field of view-a referring-physician aid. *J Nucl Sci Technol* 38: 123-127.
3. Purandare NC (2011) Inclusion of brain in FDG PET/CT scanning techniques in cancer patients: Does it obviate the need for dedicated brain imaging. *Indian J Nucl Med* 26: 64-66.
4. Willmarth N, Elder S, Fine A, Ahluwalia MS, Barnholtz-Sloan J, et al. (2019) Insight into the brain metastasis journey: Initial survey results from patients and caregivers. *J Clin Oncol* 37: 2069.
5. Nia ES, Garland LL, Eshghi N, Nia BB, Avery RJ, et al. (2017) Incidence of brain metastases on follow-up 18 F-FDG PET/CT scans of non-small cell lung cancer patients: Should we include the brain? *J Nucl Med Technol* 45: 193-197.
6. Bochev P, Klisarova A, Kaprelyan A, Chaushev B, Dancheva Z (2012) Brain metastases detectability of routine whole body 18F-FDG PET and low dose CT scanning in 2502 asymptomatic patients with solid extracranial tumors. *Hell J Nucl Med* 15.
7. Kitajima K, Nakamoto Y, Okizuka H, Onishi Y, Senda M, et al. (2008) Accuracy of whole-body FDG-PET/CT for detecting brain metastases from non-central nervous system tumors. *Ann Nucl Med* 22: 595-602.
8. Boellaard R, Bolton RD, Oyen WJG, Giammarile F, Tatsch K, et al. (2015) FDG PET/CT: EANM procedure guidelines for tumour imaging. *Eur J Nucl Med Mol I* 328-354.