

Extra-Intestinal Complications and Manifestations (Ocular and Pulmonary) among Patients with Crohn's Disease

Abeer S Ali¹, Ashjan Bamahfouz², Talal M Karima³, Enas A Alkhoutani², Anas A Alkhoutani⁴, Rehaam M Wayani², Alaa N Turkistani⁵ and Raneem M Wayani²

¹Department of Pathology, Faculty of Medicine, Umm Al-Qurra University, Saudi Arabia

²Ummul Qura University, Makkah, Kingdom of Saudi Arabia

³Herra General Hospital, Makkah, Kingdom of Saudi Arabia

⁴King Abdulaziz hospital, Makkah, Kingdom of Saudi Arabia

⁵Imam Abdulrahman bin Faisal University, Saudi Arabia

*Corresponding author: Dr. Abeer S Ali, Lecturer of Pathology, Department of Pathology, Faculty of Medicine, Umm Al-Qurra University, Saudi Arabia, Tel: 00966563322591; E-mail: Abeershaker72@gmail.com

Received date: February 14, 2017; Accepted date: March 20, 2017; Published date: March 27, 2017

Copyright: © 2017 Ali AS, et al. This is an open-access article distributed under the terms of the Creative Commons Attribution License, which permits unrestricted use, distribution, and reproduction in any medium, provided the original author and source are credited.

Abstract

Crohn's disease (CD) is an immune-mediated disorder of unknown etiology primarily affect the gastrointestinal tract with series of extra intestinal manifestations (EIM) and Extra intestinal complications (EIC) that affects different organs and systems. EIMs are capable of involving nearly every system in the body; some believe that IBD is a systemic disorder with predominantly bowel manifestations. EI complications are mainly caused by the disease itself that induce mal-absorption with consequent micronutrient deficiencies, osteoporosis, peripheral neuropathies, kidney stones, gallstones and IBD drug-related side effects. In Saudi Arabia, CD is reported frequently. In this review, we try to make stress on different previously reported frequencies of EIMs and EIC in patients with CD; from our point of view we make an overview on the ocular and pulmonary complications and manifestations that are related either to disease activity or an indication of the presence of CD. Scleritis, uveitis and dry eye syndrome in previous healthy subjects with intestinal manifestation help in early diagnosis of CD especially in unexpected ages of the diseases. Further work on pulmonary manifestations to make full explanation on whether pulmonary disease is secondary to the drugs or to the underlying disease process.

Keywords: Crohn's disease; Extraintestinal complications; Extraintestinal manifestations; Ocular and pulmonary

these factors cannot be attributed to be an inciting element for enhancing inflammatory process.

Introduction

Crohn's disease (CD) is one of the inflammatory disorders affecting the gastrointestinal tract by the means of Inflammatory Bowel Diseases (IBD). CD is not a fatal disorder, but is considered as a debilitating condition with a wide a range of symptoms and is characterized by chronic, segmental, granulomatous inflammation with periods of flaring up and remission [1]. Symptoms of CD are not specific; including general symptoms as fever, anaemia and weight loss in addition to the gastrointestinal symptoms including abdominal pain, vomiting, diarrhea and rectal bleeding. There are a wide range of extra intestinal manifestations (EIMs) and extra intestinal complications (EICs) that contribute to greater disorders than the underlying intestinal inflammatory disease process and can be considered as first presenting symptoms of the CD.

Many systems in the body are greatly affected as series of extra intestinal manifestations (EIMs) and extra intestinal complications (EICs); Table 1 shows the most important systems affected by CD. Perianal Crohn's disease patients are at higher risk for developing EIMs than other IBD patients [1]. There is no clear pathogenesis of EIMs in patients with CD that makes a great need for multidisciplinary approach to treat patients of CD with EIMs to decrease the morbidity. Recent studies on CD making the pathogenesis as a result of the combined effects of four main groups of factors: environmental, immunological, genetic, and infectious. At the same time, none of

Hepatobiliary	} — Most common
Musculoskeletal	
Dermatologic	
Ocular triad	
Genitourinary	
Vascular and hematologic	
Cardiac	
Pulmonary	
Endocrine and metabolic	

Table 1: Most important systems affected by CD.

Aim

The aim of this review is to discuss and make a spotlight on the most important prevalent extra intestinal manifestation and complication of CD that can give from our point of view in the form of ocular and pulmonary manifestations as an indication of the presence of CD and/or correlation with the disease activity and flaring through reviewing the reported articles concerning the contradictions, gaps and inconsistency in the texts.

Discussion

Crohn's disease is one of the inflammatory bowel diseases with a granulomatous inflammatory disorder affecting the gastrointestinal tract, with a relapsing, immunologically mediated disorder [2]. It causes long lasting irritation that damage the gastrointestinal (GI) tract. It can influence any part of the GI tract, starting from the mouth to the anal tract. Mostly and regularly influences the small bowel (the ileum). Crohn's disease affects the GI as "patches," influencing a few areas of the GI tract while leaving other parts completely free. The entire wall thickness of the bowel wall is affected by the inflammatory process. The predominant age range of patients with CD is reported between 20 and 30; but it can affect any age [3,4]. Classically patients with CD present with fatigue, prolonged diarrhea with or without gross bleeding or/and mucus, abdominal pain, weight loss, and fever [5]. The ileocolonic lesions start with mucosal ulcers and change into fistulas by the time. CD is a common disease in industrialized countries with an expanding occurrence worldwide in Western European and North American nations have been customarily viewed as high-frequency regions. Amid the most recent decade, an expanding rate has been seen in Eastern Europe and Asia [6-8]. In Middle East two decades back, CD was viewed as extremely uncommon; yet numerous current reports from various focuses in Saudi Arabia and other Arab nations propose a high rate increase in CD incidence and commonness in this area [8-10]. 25 years ago, it was believed that CD does not exist in the KSA [11]. In Saudi Arabia CD is reported frequently. As reported by Aljebreen et al., in the Middle East a complete epidemiological investigation of CD through a large cohort study in 497 patients with CD; through studying CRP levels, age at which CD is first diagnosed, disease duration, specific location of the inflammatory process based on the Montreal classification [12]; which conclude that dominantly in the study group of CD patients they were men and mostly at young age [13]. The definite etiology of CD remains unclear. An interactions among several factors, including genetic factors, host immune system and environmental Factors (including diets and microbiological agents), play pivotal roles in disturbing the intestinal homeostasis, resulting on dysregulated inflammatory responses of the alimentary tract [14,15]. CD has a complex etiology, an immune-mediated condition in genetically susceptible individuals is the most widely accepted hypothesis for the etiology of CD, the onset of the disease is provoked by environmental factors that upset the mucosal barrier, alter the healthy balance of the gut flora, and abnormally stimulate gut immune responses [16]. Sartor accentuated that based on studying the genetics of CD; four genes have been related to the pathogenesis of CD while others will be related with extra intestinal manifestations as HLA-B27 and HLA-DR0103 human leukocyte antigen haplotypes. Predominantly in Crohn's disease these genes control innate immune responses, hinders the mucosal barrier and bacterial slaughtering [2]. TH1-and TH17-are the key players in the immune process. There is no immediate proof of defective T-cell function in the disease process, however confirmation is that it that innate immune responses is deficient in Crohn's disease [2]. Extra intestinal manifestations (EIMs) are related to IBD in a wide range t that possibly unfavorable effect on the personal satisfaction, and may even be the initial presenting symptoms of the IBD.

EIMs are capable of involving nearly every system in the body, some believe that IBD is a systemic disorder with predominantly bowel manifestations [17]. 2 groups of extra intestinal symptoms: extra intestinal manifestations (EIM) and extra intestinal complications. EIM most frequently affect joints (peripheral and axial arthropathies), the skin (erythema nodosum, pyoderma gangrenosum, Sweet's

syndrome, aphthous stomatitis), the hepatobiliary tract (primary sclerosing cholangitis [PSC]), and the eye (episcleritis, uveitis) [18]. EI complications are mainly caused by the disease itself that induce malabsorption with consequent micronutrient deficiencies, osteoporosis, peripheral neuropathies, kidney stones, gallstones, and IBD drug-related side effects [18]. The incidence of EIMs reported in both Crohn's disease and Ulcerative colitis is highly variable, ranging from 25% to 40% [19,20]. EIMs may occur more common in CD than in UC. 6% to 40% of patients with IBD have one or more extra intestinal manifestation [19]. Up to 15 percent of patients have a cutaneous manifestation of IBD [18]. The incidence of ocular manifestations secondary to IBD is 4% to 10% and it tends to occur more with CD than UC [21,22]. Extra intestinal manifestations of CD are commonly prevalent including cholelithiasis, anemia, inflammatory arthropathies, erythema nodosum, osteoporosis, nephrolithiasis, venous thromboembolism, scleritis, and uveitis [20]. Ocular manifestation is one of the important extra-intestinal manifestation of CD with a reported incidence of 4% to 10% including episcleritis, scleritis, conjunctivitis, anterior uveitis, orbital pseudotumor, optic neuritis, marginal keratitis, retinal vascular occlusive disease, and retinitis, as reported by Mady [23], however Siqueira's reported up to 12% with the majority of iritis, uveitis, episcleritis, and conjunctivitis [24].

Barabino found that the most common complications are episcleritis, scleritis, and uveitis occurring in up to 29%, 18% and 17% of patients, respectively [25], while Katsanos found that Posterior scleritis and orbital inflammatory disease (orbital pseudotumor) are the most commonly existing [24], and Mady found that the commonest among them is episcleritis [23]. On the other hand, the incidence of the involvement of the posterior segment is less than 1% as it is very rare [24], while the reported incidence by Barabino, ranges between less than 1% to 30% [25]. These complications are visual threatening and must be discovered early to prevent significant visual morbidity [23], the importance of consultation between gastroenterologist and ophthalmologist are warrant [26].

The risk of ocular manifestations of CD possibly increased with several factors, as in patients with ileocolitis and colitis are more prone to have a greater risk in compare with patients having ileitis only, in addition to that the risk of ocular manifestations might be increased up to 33% with involvement of other organ as in patient with Crohn's disease and joint involvement (arthralgia), moreover genetic factors also increases the risk of ocular manifestations with CD. Crohn's disease patients with extra-intestinal manifestation are showing more increased prevalence of HLA-B27 in compare to the normal population [23,24]. Concerning the underlying pathology of extra-intestinal manifestation of inflammatory bowel disease is unclear; it is thought to be due to the disease inflammatory process, considering the antigen-antibody complex in the blood circulation and the production of autoantibody to the antigen of the cells which is common between the colon and the extra-intestinal organs. Inflammation that causes mucosal damage of the intestinal epithelium gives a chance to some microorganisms and proteins to find a way of passing through the barriers of the intestine which leads to reactive lymphoid tissue response; this causes the production of antibodies and formation of antigen-antibody complex in the blood circulation resulting in systemic inflammation. The immunological responding to the antigen of the colon might explain the reason of the ocular manifestation that happens more with ileocolitis and colitis than in the involvement of small bowl only [23,24]. The pathogenesis is still on investigation,

because of the molecular mimicry is also thought to be participating in the pathology [23].

Episcleritis

It is one of the commonest manifestation in relation to the eye secondary to inflammatory bowel disease with the incidence of 29% [25], there is a relation between episcleritis and Crohn's disease in which episcleritis indicates the CD activity [23].

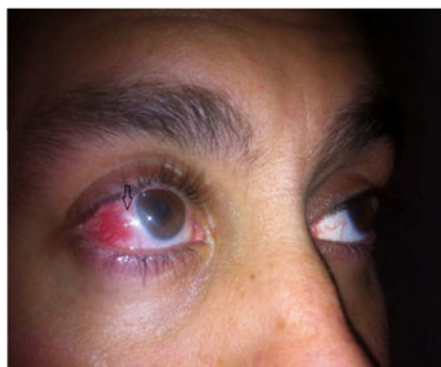

Figure 1: Figure showing dilated, inflamed scleral vasculature and a prominent nodule (black arrow) [24].

Scleritis

Scleritis is less prevalent complication of IBD compared to episcleritis, with a reported incidence of 18% by Barabino [25], while the more recent reported incidence by Galanopoulos was 2-5% (Figure 1) [27], scleritis is unlike episcleritis it does not indicate active CD as it can occur in quiescent IBD. 50% of scleritis patients are having a systemic disease underlying, work up should be initiated to discover the underlying systemic disease as inflammatory bowel disease.

The management of scleritis must be with conjunction of gastroenterologist and must be with aggressive-systemic treatment with systemic steroids and non-steroidal anti-inflammatory drugs or immunosuppression therapy [23].

Anterior uveitis

It is described as an intraocular structures inflammation and it is divided into posterior uveitis, anterior uveitis, and panuveitis. Inflammatory bowel disease might present with panuveitis and posterior uveitis, but it typically presents with non-granulomatous acute anterior uveitis, it has no relation to the disease activity as it occurs in both active and quiescent periods, but it can lead to the diagnosis of inflammatory bowel disease [23]. A well-established relation of Crohn's disease, acute iritis, and sacroiliitis, has been found as they tend to be positive to HLA-B27.

Ophthalmic manifestations like uveitis is warrant due to the rare possibility of preceding the CD symptoms, many long-term complication of Crohn's disease can be delayed or avoided if the diagnosis established before the GI involvement gets sever, that's why it is essential while dealing with patients of acute anterior uveitis to ask about the symptoms of CD such as, abdominal pain, fever, weight loss, bloody diarrhea, and anemia [23]. Uveitis is not as episcleritis, it does

not indicate CD flare, but it suggests the presence of the disease especially in the presence of GI symptoms and helps in delay and avoids CD consequences.

Optic neuritis (ON)

In the current literature, the incidence of ON is 0.08%, there is a relationship between CD and optic neuritis, but still cannot be argued. There is a case reported by Barabino on a child with a history of CD manifested with sudden loss of visual acuity and bilateral ON not due to any known cause, which was responsive to a high dose of steroids.

In this case, there is a possible correlation between ON and CD, so that it is important to consider optic neuritis as a complication of IBD specially CD by ophthalmologists and pediatric gastroenterologists [25].

Orbital myositis

Muscle involvement in extra intestinal manifestations of Crohn's disease is rare, but it can be related either to therapy or to a co-existing autoimmune disease affecting the muscle or to disease related myositis [28]. It was first detected by Birch-Hirschfeld in 1905 [29]. Orbital myositis (inflammatory orbital pseudotumor) is an idiopathic non-specific, non-neoplastic inflammatory process of the orbit [28,29], one or more of the extraocular muscles being affected.

TNF- α mediated inflammation may be involved in the pathogenesis [28]. After Grave's disease and lympho-proliferative disorders, orbital pseudotumor is the third most common ophthalmologic disease of the orbit and account for approximately 8%-11% of all the orbital tumors, ocular and systemic disorders are incorporated with it, including scleritis, rheumatoid arthritis, Crohn's disease and systemic lupus erythematosus [29].

There is a case reported by Bourikas, of orbital myositis secondary to Crohn's disease, a 35-year-old women was referred to a hospital due to diarrhea, low grade fever, weight loss of 9 kg and low back pain of 1 month duration, the patient presented with past medical history of unilateral orbital myositis since one year with good response to steroid therapy [28].

Dry eye syndrome

The incidence of dry-eye syndrome in children is very low it's about 1%-2%. there is a case report of dry-eye in a pediatric patient with CD which was reported in Makkah city of Saudi Arabia by Bamahfouz, of a 7-year-old female, complaining of pain, redness, photophobia, intermittent itching, and decreased vision, of 1 year duration with an associated symptoms of weight loss and loss of appetite, fever, bone pain, and chronic diarrhea. Other histories were unremarkable.

Ophthalmic examination

Investigations and work-up were needed to rule out underlying systemic disease as IBD, collagen vascular disease, celiac disease, xeroderma pigmentosa, immunodeficiency, so that the patient was admitted to the pediatric ward. The patient's work-up revealed hypoalbuminemia, iron deficiency anemia, elevated ESR od 113, low vitamin A level, negative rheumatoid factor, anti-neutrophil cytoplasmic antibodies, and anti-nuclear antibodies (Table 2).

The patient under-went Colonoscopy as it showed inflammation of the sigmoid colon and the rectum, and many ulcers with inflammatory

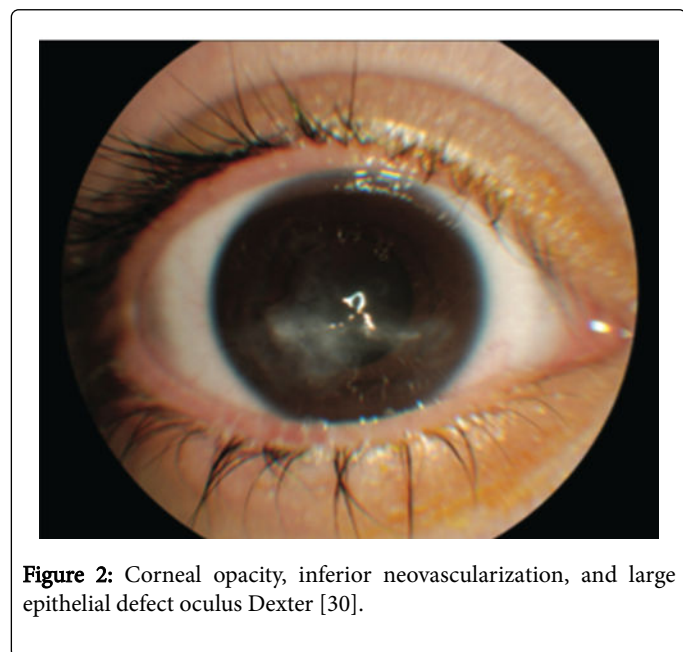
exudates, the ileocecal valve was normal, many skin tags and anal fissures were observed, biopsy was taken and it confirmed the diagnosis of Crohn's disease.

Very few available data of pediatric dry-eye syndrome prevalence, as it's less frequently appears in pediatric age, so that it's obviously challenging to diagnose and manage dry-eye syndrome in children, in

fact it is important to be cautious in pediatric age group in order not to neglect this uncommon presentation and be carious to look up and search for associated possible systemic disease with an effort to identify the local and systemic symptoms and signs to provide a curative treatment of the disease it-self and prevent its subsequent complications [30].

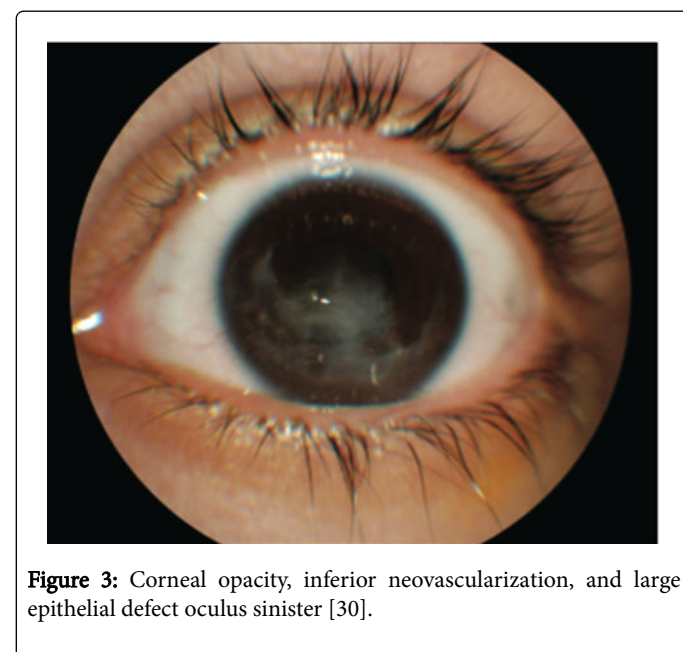
Best corrected visual acuity	20/400 OU
Cycloplegic refraction: Oculus Dexter (OD) Oculus Sinister (OS)	-9.0 -4.50'50 -9.75, -3.75'140
Intraocular pressure	20 and 16 mm of Hg OD and OS, respectively.
Slit lamp	Low tear meniscus, tear break-up time more than 10 s
Cornea	Opacity, inferior neovascularization, large epithelial defect OU.
Iris	Normal OU
Anterior chamber	Deep, with occasional cells OU
Lens	Early posterior sub-capsular cataract OU5
Vitreous	Clear OU
Fundus	Normal OU

Table 2: Ophthalmic examination.



Another case report was published by Mrugacz in Poland of an 11-year-old girl with 7-years history of Crohn's disease, presented to the clinic of pediatric ophthalmology, complaining of bilateral blurred vision, pain, redness, and mild photophobia with tearing for 4 days (Figure 2). A complete ophthalmologic examination and dry eye syndrome tests were performed and the patient was diagnosed with bilateral dry eye syndrome, conjunctivitis and posterior subcapsular

cataract. Ocular complications occurs as secondary disorders in response to the inflammatory process of the disease or to corticosteroid therapy (Figure 3).



So that evaluation of the eye should be routinely done as part of care of patients with Crohn's disease even if there is no eye symptoms to detect early ocular complications of the disease or the corticosteroid use (Table 3) [31].

Ocular complication of CD	Incidence	Year
Orbital myositis [29]	8-11%	2008
Episcleritis [25]	29%	2011
Scleritis [25]	18%	2011
Uveitis [25]	17%	2011
Posterior segment Manifestation [25]	1-30%	2011
Optic neuritis [25]	0.08%	2011
Dry eye syndrome in children [30]	1-2%	2015
Scleritis [27]	2-5%	2016

Table 3: Incidence of ocular complications correlating with years.

Incidence of the pulmonary complication reported as relatively rare extra intestinal manifestation of Crohn's disease; 21% to 41% of patients with IBD patients had pulmonary complications and are more common in Crohn's disease (CD) than in ulcerative colitis (UC), 400 cases with CD has been recognized and reported in the literature with pulmonary involvement [32-37], it's occasionally possibly causing serious illness that needs pulmonary evaluation, a wide spectrum of lung manifestations, extending from subclinical changes without any symptoms, upper and lower airway diseases, parenchymal diseases of lung up to pleural involvement in addition to medication side effects. The most obvious complication is bronchial inflammation and suppuration with or without bronchiectasis. Pulmonary complications are unusual and its pathophysiology remains unclear [34,37], but there are many mechanisms thought to be the reason of lungs involvement in CD, these include the same embryological origin of the lung and gastrointestinal tract, similar immune systems in the pulmonary and intestinal mucosa, the presence of circulating immune complexes and auto-antibodies, and the adverse effects of some drugs used to treat Crohn's disease [34,36], there is no explanation whether pulmonary involvement occurs secondary to the drugs or to the underlying disease process [37]. Intestinal disease activity is considered as the main indicator for the development of pulmonary disease, it's important to the physician possibility for the development of pulmonary disease in patients with Crohn's disease; this is to start the ideal treatment early in order to decrease other further complications [34,37], by undergoing pulmonary evaluation of physical examination, chest X-ray and pulmonary function tests are mandatory in addition to calculate diffuse lung capacity of carbon monoxide to reach a final diagnosis, bronchoscopy and thoracoscopy may be helpful [34]. IBD patients showed impairment of pulmonary function test in some previous studies, whereas other studies do not, and some of them reported that the impairment in pulmonary function test associated with the disease activity, so that there is a recent prospective study carried out by Xiao-Qing Ji in 2016 with an aim of investigating the alterations of pulmonary function tests (PFTs) and their relation with the disease activity in inflammatory bowel diseases, they concluded that PFTs in IBD patients showed subclinical abnormalities some of which could be detected even in the remission periods and become pronounced in the relapse phase of diseases. PFTs might be used as a noninvasive means of diagnosis to determine the activity of disease and might contribute to the early detection of latent pulmonary involvement [36]. On the other hand, there is a new growing evidence of an inter-relation between IBD and airway diseases that not only

airway diseases occur as extra intestinal manifestations of IBD, but also there's relative risk increase of IBD occurrence among patients with pulmonary airway diseases as asthma, chronic obstructive pulmonary disease (COPD) and bronchiectasis, Future research should be carried out for further exploration of this two-way association [33]. There is a retrospective cohort study conducted by Paul Brassard in 2014 to assess whether the incidences of Crohn's disease and ulcerative colitis are increased in patients with asthma and chronic obstructive pulmonary disease (COPD) compared to the general population during 2001-2006, they found that the incidences of both Crohn's disease and ulcerative colitis were markedly increased in asthma and COPD patients during 2001-2006 compared to the general population of Québec. Women with asthma were more prone to develop Crohn's disease than men, and men with COPD were more prone to develop ulcerative colitis than women. Confirmation of such results in further future studies may help in early detection of IBD to start the management and treatment plan before developing serious complications [35].

Conclusion

We found that we can detect CD early to manage it properly and prevent further complications, there is some complications directly related to the disease activity as in pulmonary involvement and some ocular manifestation as episcleritis, and there are some other complications that can also help in the early diagnosis of CD but does not indicate the disease activity as in scleritis, uveitis, dry eye syndrome. According to pulmonary complications and pulmonary manifestations it was difficult to determine whether pulmonary disease is secondary to the drugs or to the underlying disease process and this needs further work on it to explore this two way association.

Recommendation

Our recommendations are based on the previous mentioned findings correlating the extra intestinal complications and extra intestinal manifestation of Crohn's disease either active disease or early diagnosis; the physician must pay attention in cases of scleritis, uveitis and dry eye syndrome in previous healthy subjects with intestinal manifestation to go through full investigations that will help in early diagnosis of CD especially in unexpected ages of the diseases to decrease the overall extra intestinal complications that may lead to increasing the mortality rate from extra intestinal complications than

the disease activity. Further work on pulmonary manifestations to make full explanation on whether pulmonary disease is secondary to the drugs or to the underlying disease process.

Conflict of Interest

The authors declared that there was no conflict of interest.

References

1. Wójcik B, Loga K, Włodarczyk M, Sobolewska-Włodarczyk A, Padysz M, et al. (2016) Extraintestinal manifestations of Crohn's disease. *Gastroenterology Rev* 11: 218-221.
2. Sartor RB (2006) Mechanisms of disease: pathogenesis of Crohn's disease and ulcerative colitis. *Nature Clinical Practice Gastroenterology & Hepatology* 3: 390-407.
3. Laass MW, Roggenbuck D, Conrad K (2014) Diagnosis and classification of Crohn's disease. *Autoimmun Rev* 13: 467-471.
4. Pinzon MCM, Hayden DM (2015) Crohn's disease. *Common surgical diseases*: Springer pp: 161-163.
5. Wallace KL, Zheng LB, Kanazawa Y, Shih DQ (2014) Immunopathology of inflammatory bowel disease. *World J Gastroenterol* 20: 6-21.
6. Jussila A, Virta LJ, Kautiainen H, Rekiaro M, Nieminen U, et al. (2012) Increasing incidence of inflammatory bowel diseases between 2000 and 2007: A Nationwide register study in Finland. *Inflamm Bowel Dis* 18: 555-561.
7. Thia KT, Loftus EV, Sandborn WJ, Yang SK (2008) An update on the epidemiology of inflammatory bowel disease in Asia. *Am J Gastroenterol* 103: 3167-3182.
8. Sincic BM, Vucelic B, Persic M, Brncic N, Erzen DJ, et al. (2006) Incidence of inflammatory bowel disease in Primorsko-Goranska county, Croatia, 2000-2004: A prospective population-based study. *Scand J Gastroenterol* 41: 437-444.
9. Siddique I, Alazmi W, Al-Ali J, Al-Fadli A, Alateeqi N, et al. (2012) Clinical epidemiology of Crohn's Disease in Arabs based on the Montreal classification. *Inflamm Bowel Dis* 18: 1689-1697.
10. Fadda MA, Peedikayil MC, Kagevi I, Kahtani KA, Ben AA, et al. (2012) Inflammatory bowel disease in Saudi Arabia: A hospital-based clinical study of 312 patients. *Ann Saudi Med* 32: 276-282.
11. Al-Mofarreh MA, Al-Mofleh IA, Al-Teimi IN, Al-Jebreen AM (2009) Crohn's Disease in a Saudi outpatient population: Is it still rare? *Saudi J Gastroenterol* 15: 111-116.
12. Van AG, Dignass A, Panes J, Beaugerie L, Karagiannis J, et al. (2010) The second European evidence-based consensus on the diagnosis and management of Crohn's Disease: Definitions and diagnosis. *J Crohns Colitis* 4: 7-27.
13. Aljebreen AM, Alharbi OR, Azzam NA, Almalki AS, Alswat KA, et al. (2014) Clinical epidemiology and phenotypic characteristics of Crohn's disease in the central region of Saudi Arabia. *Saudi J Gastroenterol* 20: 162-169.
14. Yamada T, Grisham MB (1991) Role of neutrophil-derived oxidants in the pathogenesis of intestinal inflammation. *Klin Wochenschr* 69: 988-994.
15. Kraft M, Riedel S, Maaser C, Kucharzik T, Steinbuechel A, et al. (2001) IFN-gamma synergizes with TNF-alpha but not with viable *H. pylori* in up-regulating CXC chemokine secretion in gastric epithelial cells. *Clin Exp Immunol* 126: 474-481.
16. Boyapati R, Satsangi J, Ho GT (2015) Pathogenesis of Crohn's disease. *F1000 Prime Reports* 7: 44.
17. Ardizzzonea S, Puttini PS, Cassinotta A, Porroa GB (2008) Extraintestinal manifestations of inflammatory bowel disease. *Dig Liver Dis* 40: 253-259.
18. Vavricka SR, Schoepfer A, Scharl M, Lakatos PL, Navarini A, et al. (2015) Extraintestinal manifestations of inflammatory bowel disease. *Inflamm Bowel Dis* 21: 1982-1992.
19. Bernstein CN, Blanchard JF, Rawsthorne P, Yu N (2001) The prevalence of extraintestinal diseases in inflammatory bowel disease: a population-based study. *Am J Gastroenterol* 96: 1116-1122.
20. Larsen S, Bendtzen K, Nielsen OH (2010) Extraintestinal manifestations of inflammatory bowel disease: epidemiology, diagnosis, and management. *Ann Med* 42: 97-114.
21. Mintz R, Feller ER, Bahr RL, Shah SA (2004) Ocular manifestations of inflammatory bowel disease. *Inflamm Bowel Dis* 10:135-139.
22. Salmon JF, Wright JP, Murray AD (1991) Ocular inflammation in Crohn's disease. *Ophthalmology* 98: 480-484.
23. Mady R, Grover W, Butrus S (2015) Review article ocular complications of inflammatory bowel disease. *The Scientific World Journal*.
24. Siqueira RC, Kaiser RL, Ruiz LP, Ruiz MA (2016) Ischemic retinopathy associated with Crohn's disease. *Int Med Case Rep J* 9: 197-200.
25. Barabino AV, Gandullia P, Calvi A, Vignola S, Arrigo S, et al. (2011) Sudden blindness in a child with Crohn's disease. *World J Gastroenterol* 17: 4344-4346.
26. Katsanos A, Asproudis I, Katsanos KH, Dastiridou AI, Aspiotis M, et al. (2013) Orbital and optic nerve complications of inflammatory bowel disease. *J Crohns Colitis* 7: 683-693.
27. Galanopoulos M, Nikolaidou E, Sarafis A, Liatsos C, Kalafatis E (2016) A successful treatment of anterior nodular scleritis with topical corticosteroids in a patient with Crohn's Colitis. *J Inflamm Bowel Dis & Discord* 1:1.
28. Bourikas LA, Roussomoustakaki M, Papadaki E, Valatas V, Koutroubakis IE, et al. (2010) A case of orbital myositis preceding the intestinal symptoms of Crohn's disease. *Journal of Crohn's and Colitis* 4: 349-350.
29. Chaudhry IA, Shamsi FA, Arat YO, Riley FC (2008) Orbital Pseudotumor: Distinct diagnostic features and management. *middle east Afr J Ophthalmol* 15: 17-27.
30. Bamahfouz AY (2015) Dry eye in a pediatric patient with Crohn's disease: A rare case report. *IJSS Case Reports & Reviews* 2: 4.
31. Mrugacz M, Sredzińska-Kita D, Cyrta-Jarocka E, Bakunowicz-Lazarczyk A (2005) Dry eye syndrome and cataract as ocular manifestations of Crohn's disease. *Kiln Oczna* 107: 509-510.
32. Verma S, Kroeker KI, Fedorak RN (2013) Adalimumab for orbital myositis in a patient with Crohn's disease who discontinued infliximab: a case report and review of the literature. *BMC Gastroenterol* 13:59.
33. Vutcovici M, Brassard P, Bitton A (2016) Inflammatory bowel disease and airway diseases. *World J Gastroenterol* 22: 7735-7741.
34. Lu D, Ji X, Liu X, Li H, Zhang C (2014) Pulmonary manifestations of Crohn's disease. *World J Gastroenterol* 20: 133-141.
35. Brassard P, Vutcovici M, Ernst P, Patenaude V, Sewitch M, et al. (2015) Increased incidence of inflammatory bowel disease in Québec residents with airway diseases. *Eur Respir J* 45: 962-968.
36. Ji X, Ji Y, Wang S, Zhang C, Lu D (2016) Alterations of pulmonary function in patients with inflammatory bowel diseases. *Ann Thorac Med* 11: 249-253.
37. Basseri B, Enayati P, Marchevsky A, Papadakis KA (2010) Pulmonary manifestations of inflammatory bowel disease: Case presentations and review. *J Crohns* 4: 390-397.