

Fitz-Hugh-Curtis Syndrome as Finding during Open Cholecystectomy and Unknown Pregnancy: Clinical Case

Guillermo Padrón Arredondo*

Department of Surgery, General Hospital of Playa del Carmen, Solidaridad, Quintana Roo, Mexico

*Corresponding author: Dr. Guillermo Padron Arredondo, Cda. Corales 138, Residential Playa del Sol Playa del Carmen, Solidaridad, Q. Roo. CP, 77710, México, Tel: 984-876-2267; E-mail: gpadronarredondo@hotmail.com

Received date: August 2, 2016; Accepted date: September 6, 2016; Publication date: September 12, 2016

Copyright: © 2016 Arredondo GP. This is an open-access article distributed under the terms of the Creative Commons Attribution License; which permits unrestricted use; distribution; and reproduction in any medium; provided the original author and source are credited.

Abstract

Introduction: The Fitz-Hugh-Curtis syndrome is a perihepatitis produced by secondary peritonitis the rise of bacteria, as a result of pelvic inflammatory disease. In the chronic stage can be observed adhesions between abdominal wall and the liver surface characterized by the similarity to "violin strings". This image is considered diagnostic criterion.

Clinical case: Female 37 years-old, Gesta 7, Births 5, Abortion 1, Cesarean Section 0, who intervenes surgically open to present intermittent pain for gallstone cholecystitis two years of evolution. Normal vital signs; Laboratory test preoperative: erythrocytes 3.40×10^6 , hemoglobin 9.9 g/dl, hematocrit 33.8%, lymphocytes 19%, leukocytes $11.86 \times 10^3/\text{mm}^3$, total neutrophil 86%. Glucose 139 mg/dl, BUN 4.35 mg/dl, urea 9.3 mg/dl, SGOT (AST) 80 U/l, SGPT (ALT) 66 U/l, Proteins 6.0 g/dl, serum albumin 3.4 mg/dl. VDRL Neg. Urinalysis: Urobilinogen 2 mg/dl; Leukocyte 15-20 x field and postoperative pregnancy test (+). It proceeds to open cholecystectomy and during exposure of the gallbladder is located in hepatic parenchyma multiple adhesions and congestive liver.

Discussion: The combination of a painful liver without biochemical evidence of hepatitis or biliary obstruction, and menorrhagia raised the suspicion of perihepatitis Fitz-Hugh-Curtis, an inflammatory process of the liver capsule due to pelvic inflammatory disease mostly caused by *Chlamydia trachomatis* or *Neisseria gonorrhoeae*. The pathophysiology of perihepatitis FHC is unclear, but direct infection of the liver capsule, hematologic or lymphatic spread as well as an exaggerated immune response has been suggested.

Keywords: Right upper quadrant pain; Cholecistectomy; Fitz-Hugh-Curtis syndrome; Sexually transmitted disease; Violin string adhesions; Pregnancy

Introduction

In 1920 Carlo Stajano first described adhesions violin strings that characterize the chronic stage of this síndrome [1]. These adhesions are formed between liver surface and the abdominal wall. Curtis in 1930 associates this training to the presence of *Neisseria gonorrhoeae* [2]. Fitz-Hugh in 1934 described them as a result of gonococcal peritonitis [3].

The Fitz-Hugh-Curtis syndrome (FHCS) is a perihepatitis produced by secondary peritonitis the rise of bacteria, as a result of pelvic inflammatory disease. In the chronic stage can be observed adhesions between abdominal wall and the liver surface, characterized by the similarity to "violin strings". This image is considered diagnostic criterion.

García-Compean et al. [4] in its study establishes that the SFHC should be considered in the differential diagnosis in women with abdominal pain, fever and leukocytosis. Also it observed in 5 to 10% of women with salpingitis or tubal infertility in developed countries but is estimated at 34% similar to that observed in the developing country like México.

The Fitz-Hugh-Curtis syndrome, also known as acute perihepatitis, was discovered in 1930 and is a rare disorder characterised by inflammation of the peritoneum and the tissues surrounding the liver. This syndrome can arise as a potential complication from a pelvic inflammatory disease caused by *Neisseria gonorrhoeae* or *Chlamydia trachomatis*. This syndrome is not well known in the medical community and is often underdiagnosed. In this case report, we revisit FHC syndrome, particularly its noninvasive diagnosis and complications [5].

Clinical Case

Female 37 years-old, gesta 7, births 5, abortion 1 Cesarean Section 0, who intervenes surgically open to present intermittent pain for gallstone cholecystitis two years of evolution. With occupation of housewife and semi-illiterate. Vital signs BP 110/70, BF 72, FR 20, Temp 96.8°F. Laboratory test: erythrocytes 3.40×10^6 , hemoglobin 9.9 g/dl, hematocrit 33.8%, 19% lymphocytes, leukocytes $11.86 \times 10^3/\text{mm}^3$, neutrophil total 86%. Glucose 139 mg/dl, BUN 4.35 mg/dl, urea 9.3 mg/dl, SGOT (AST) 80 U/l, SGPT (ALT) 66 U/l, proteins 6.0 g/dl, serum albumin 3.4 mg/dl. VDRL Neg. Urinalysis: Urobilinogen 2 mg/dl, leukocyte 15-20X field. Pregnancy test postoperative (+). Gallbladder ultrasound reported thin walls and litho inside without inflammatory data. Pathology report: acute cholecystitis with reparative changes, chronic cholecystitis usual and gallstones. It proceeds to open cholecystectomy and during exposure of the gallbladder is located in hepatic parenchyma multiple adhesions and

congestive liver (Figure 1). cholecystectomy without incident or accident takes place in the immediate postoperative period the patient has intermittent pain in lower abdomen, interconsultation requested in gynecology and obstetrics for 20.1 weeks of unknow gestation for the patient and the surgeon and proceed to appropriate medical management with resolution of uterine contractions, it is discharged within 48 hours of admission and control outpatient surgery and gynecology and obstetrics.

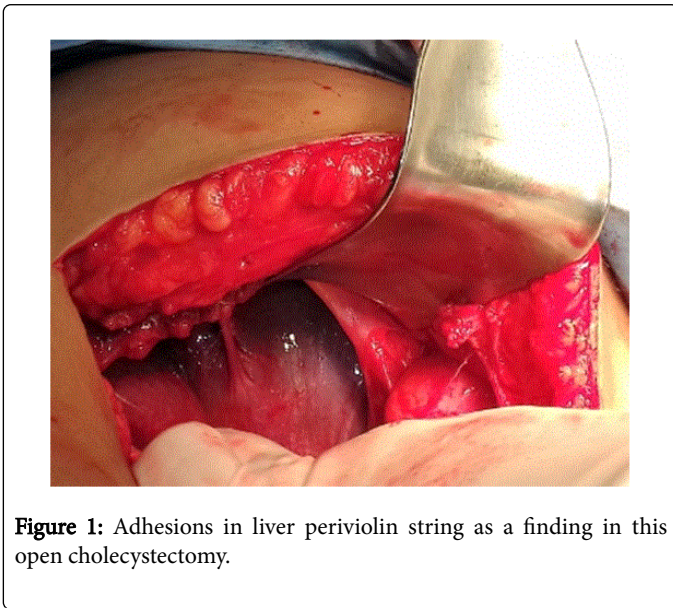


Figure 1: Adhesions in liver periviolin string as a finding in this open cholecystectomy.

Discussion

The combination of a painful liver without biochemical evidence of hepatitis or biliary obstruction, and menorrhagia raised the suspicion of perihepatitis FHCS, an inflammatory process of the liver capsule due to pelvic inflammatory disease mostly caused by *Chlamydia trachomatis* or *Neisseria gonorrhoeae* [6]. The FHCS typically presents without or only faint involvement of the liver parenchyma. While *Neisseria gonorrhoeae* was the first established pathogen, *Chlamydia trachomatis* is incriminated in most cases nowadays [7]. However, other agents that can cause disease syndrome as FHCS ureaplasmaurealyticum [8].

Jang et al. [9] report a case of this syndrome caused by non-tuberculous mycobacterial infection diagnosed and treated successfully in a young patient. FHCS is characterized by inflammation of perihepatic capsules and adhesions between the liver capsule and anterior abdominal wall with concomitant pelvic inflammatory disease (PID).

Similarly, it can also present as pain in the right chest young as the case [10,11] of intestinal malrotation associated with neuroendocrine tumor of the appendix and an association for other very rare syndrome. Ramirez et al. [12] consider the FHCS has a frequency of 3 to 37%, is very important differential diagnosis of abdominal pain in the right upper quadrant and keep this condition because the association between cholelithiasis and SFHC is purely clinical and pathological there is no established association, in addition to acute cholecystitis requires surgical management of first instance and not the FHCS.

As for the differential diagnosis, this diagnosis included pyelonephritis, pulmonary embolism, and pneumonia causing pleural pain, a gastrointestinal cause, or a subphrenic abscess. A vaginal culture was taken as part of a second opinion by a gynaecologist. However, after a few days PCR on the vaginal sample was positive for *Chlamydia trachomatis*, indicating a case of FHCS [13].

Moreover, although most of these cases have been reported in women, this syndrome can also occur in men as cases due to gonococcal infection [14-17]; reports a case of FHCS in a 26-year-old man who first presented to the emergency department with acute abdominal pain, vomiting, and fever. Diagnosis was possible on the basis of clinical signs of orchiepididymitis, abnormal ultrasound findings, and specialist consultation with the Sexually Transmitted Infection Clinic. An acute gonococcal infection was revealed, which was complicated by a collection of free perihepatic fluid and a subcapsular hypoechoic focal lesion. With regard to this diagnosis should be suspected clinically, but imaging studies can help clarify the diagnosis [18].

In conclusion, in a woman of reproductive age who presents with acute right upper quadrant pain with or without lower abdominal pain, the possibility of FHCS should be kept in mind. Mitaka et al. [19], report a case of a 23 year-old Japanese woman, previously a commercial sex worker, presented with a 2-day history of right upper quadrant (RUQ) abdominal pain, worse on deep inspiration. She had noticed increased vaginal discharge 2 months earlier and had developed dull, lower abdominal pain 3 weeks prior to presentation. Although pelvic examination and transvaginal ultrasonography revealed neither a tubal nor ovarian pathology, abdominal CT scan with contrast demonstrated early enhancement of the hepatic capsule, a finding pathognomonic for Fitz-Hugh-Curtis syndrome (FHCS). Cervical discharge PCR assay confirmed *Chlamydia trachomatis* infection.

Another study Kim et al. [20] a totals of 177 women with PID who underwent biphasic abdominal computed tomography (CT) scans were enrolled. Two reviewers retrospectively reviewed the CT scans with consensus and subjectively categorized the severity of PID into 4 grades (normal, mild, moderate, and severe). Jeong et al. [21] refers to the FHCS is inflammation of the liver capsule usually associated with pelvic inflammatory disease. FHCS has been rarely reported in male patients, and hematogenous and lymphatic spread to the liver is thought to be the underlying mechanism. Although a confirmatory diagnosis was made by laparoscopy, contrast-enhanced computed tomography scan is considered the first-line imaging tool in clinical diagnosis of FHCS.

This condition is not uncommon due to promiscuity in sexual relations in the general population as has already been reported by the author in another similar work [22].

In our patient we could not determine whether the origin of right upper quadrant pain was due to perihepatitis or the exacerbation of chronic cholecystitis, although liver function tests suggested a liver and not cholecystitis process.

References

1. Stajano C (1920) La reacción frénica en ginecología. La Semana Médica 27: 243-248.
2. Curtis AH (1930) A cause of adhesion in the right upper quadrant. JAMA 94: 1221-1222.

3. Fitz-Hugh T (1934) Acute gonococcal peritonitis of the right upper quadrant in women. *JAMA* 102: 2094-2096.
4. Ricci AP, Solà DV, Pardo SJ (2009) Síndrome de Fitz-Hugh-Curtis como hallazgo durante cirugía ginecológica. *Rev Chil Obstet Ginecol* 74: 189-193.
5. García-Compean D, García-Cantú DA, Bosques-Padilla FJ, Maldonado-Garza H, Michel H (1995) El Síndrome de Fitz-Hugh-Curtis. Causa frecuente de error diagnóstico en hepatología y gastroenterología. *Rev Gastroenterol Méx* 60: 223-228.
6. Muschart X (2015) A case report with Fitz-Hugh-Curtis syndrome, what does it mean? *Acta Clin Belg* 70: 357-358.
7. Renz N, Baur M, Stickle F (2015) Right upper quadrant pain in a young female. *J Gastrointest Liver Dis* 24: 10.
8. Ikonomidis A, Strakas M, Stavrou AG, Papageorgiou E, Lainis A, et al. (2015) Fitz-Hugh-Curtis syndrome in a 16-year-old female due to *Ureaplasma urealyticum*. *Eur J Obstet Gynecol Reprod Biol* 194: 261-262.
9. Jang HY, Burbelo PD, Chae YS, Kim T, Cho Y, et al. (2014) Nontuberculous mycobacterial infection in a clinical presentation of Fitz-Hugh-Curtis syndrome: a case report with multigene diagnostic approach. *BMC Women's Health* 14: 95.
10. Harada K, Iwamuro M, Hanayama Y, Otsuka F (2016) An Uncommon Manifestation of Fitz-Hugh-Curtis Syndrome with Right-side Chest Pain. *Acta Med Okayama* 70: 145-149.
11. Cusimano A, Abdelghany AMAB, Donadini A (2016) Chronic intermittent abdominal pain in young woman with intestinal malrotation, Fitz-Hugh-Curtis syndrome and appendiceal neuroendocrine tumor: a rare case report and literature review. *BMC Women's Health* 16: 3.
12. Colín GR, Méndez SDP, Aboites CFR, Necochea AL (2009) Síndrome de Fitz-Hugh-Curtis. Reporte de un caso y revisión de la literatura. *Cir Endosc* 10: 126-129.
13. Hesius EA, Kok B, Mattijssen EJ (2015) A gynaecological cause of upper abdominal pain: Fitz-Hugh-Curtis syndrome. *Ned Tijdschr Geneesk* 160: A9349.
14. Nardini P, Compri M, Marangoni A, D'Antuono A, Bellavista S, et al. (2015) Acute Fitz-Hugh-Curtis syndrome in a man due to gonococcal infection. *J Emerg Med* 48: e59-62.
15. Rouhard S, Maldague P, Ramboux A (2014) Fitz-Hugh-Curtis syndrome in a man. *Endoscopy* 46 Suppl 1 UCTN: E1.
16. Saurabh S, Unger E, Pavlides C (2012) Fitz-hugh-curtis syndrome in a male patient: a case report and literature review.
17. Yi H, Shim CS, Kim GW, Kim JS, Choi IZ (2015) Case of Fitz-Hugh-Curtis syndrome in male without presentation of sexually transmitted disease. *World J Clin Cases* 3: 965-969.
18. Wang PY, Zhang L, Wang X, Liu XJ, Chen L, et al. (2015) Fitz-Hugh-Curtis syndrome: clinical diagnostic value of dynamic enhanced MSCT. *J Phys Ther Sci* 27: 1641-1644.
19. Mitaka H, Kitazono H, Deshpande GA, Hiraoka E (2016) Fitz-Hugh-Curtis syndrome lacking typical characteristics of pelvic inflammatory disease. *BMJ Case Rep pii: bcr2016215711*.
20. Kim JS, Kim HC, Kim SW, Yang DM, Rhee SJ, et al. (2015) Does the degree of perihepatitis have any relevance to the severity of the manifestations of pelvic inflammatory disease on multidetector computed tomography? *J Comput Assist Tomogr* 39: 901-906.
21. Jeong TO, Song JS, Oh TH, Lee JB, Jin YH, et al. (2015) Fitz-Hugh-Curtis syndrome in a male patient due to urinary tract infection. *Clin Imaging* 39: 917-919.
22. Padrón-Arredondo G, Martínez-Góngora DA. Síndrome de Fitz-Hugh-Curtis. Presentación de un caso en una mujer mayor. *Cir Gen* 30: 110-112.