

Intradiploic Epidermoid Cysts of a Child's Skull

Amsiguine Najwa*, Iraqi Houssaini zaynab, Halfi Mohamed Ismail, Lrhorfi Najlae, Chat Latifa and Allali Nazik

Department of Pediatric Radiology, Hospital Ibn Sina, Faculty of medicine, Rabat, Morocco

Abstract

The incidence of cranial epidermoid cysts is less than 1% among all cranial tumor's was first described by Muller in 1838 such cysts that develop in record to the spongy cancellous bone separating the inner and outer layers of the cortical bone of the skull. They are derived from ectodermal vestiges that stay within the cranial bones during embryonic development. Having a male performance, they can be located in anywhere of the skull.

Keywords: Diploic; Epidermoid cysts; Child; Magnetic resonance imaging

Image Article

Intradiploic epidermoid cysts are rare, non-malignant lesions which arise between the two tables of cranial bones . [1] They are encountered more often in the frontal and parietal regions. They may often reach an enormous size without producing neurological symptoms. The pathogenesis has been rendered as mixed mechanisms congenital and acquired [2].

In our rare case in which a child of 3 years old was addressed to our department to further characterize a 3 months ongoing growth on frontal region of his scalp without associated symptoms. Physical exam showed a 2 cm large, soft and painless mass. X-ray showed a round shaped with sclerotic margins over the frontal area of the skull. Further examination using MR imaging of the brain revealed a 35x26mm mass originating from the dipole at the projection of the longitudinal fissure on the frontal area. The dura was thinned however no extension to the intradural space was noted. The tumour was resected from the cranial vault and dura mater and the histopathological examination later provided confirmation for the diagnosis. Postoperatively, the patient was discharge 48 hours following the surgery and has completely recovered.

Magnetic resonance imaging (Figure 1(A-E)) is the imaging tool

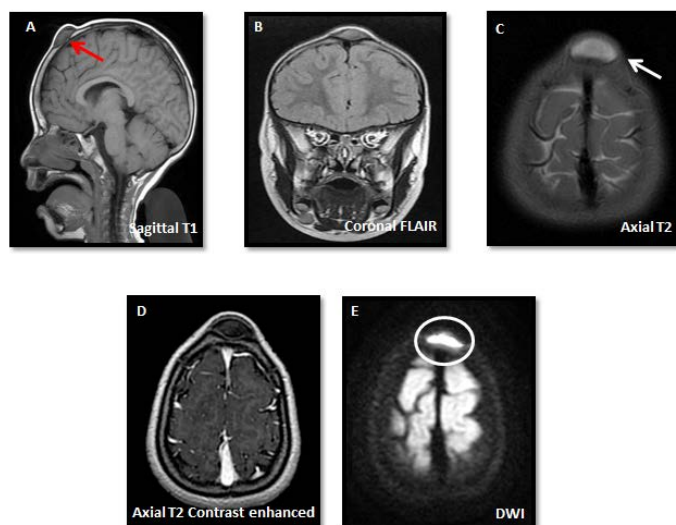


Figure 1: MRI images showing features of a confirmed intradiploic epidermoid cysts such as hypo-intense signal on sagittal T1-weighted with thinned dura (red arrow) as well as coronal flair (B), Hyper-intense homogenous signal on axial T2 as demonstrated by the white arrow as well as a clear intense signal on DWI which sets it apart from other similar lesions (white circle).

of choice, which demonstrates well-demarcated osteolysis usually low signal intensity on T1-weighted (Figure A) and may has a varied signal on T1 depending on the content of the cyst, but always a constant high-intensity on T2-weighted MRI [1] (Figure C). Moreover, MRI also allows a better study of the intracranial extension of the epidermoid tumour because of signal differences between the tumour and the brain. The best way to differentiate epidermoids from others is by using diffusion-weighted imaging, which shows an intense signal [2] (Figure E).

The main mimickers are dermoid cysts, Osteolytic metastasis, Intradiploic arachnoid cyst and occasionally Hydatid cyst. Dermoid cysts cannot be differentiated from epidermoid cysts by using plain film alone. However, the dermoid cysts occur frequently in the periorbital area. Osteolytic metastases have irregular lytic areas destroying both tables of the cranium. Hydatid cysts lack bone erosion and calcifications that are seen in epidermoids. Diffusion weighted MR imaging can be used to differentiate arachnoid cysts from epidermoid cysts whereas arachnoid cysts have low signal intensity [1-3].

References

1. Turkoglu OF, Ozdol C, Gurcan O, Gurcay AG, Tun K, et al. (2010) Huge intradiploic epidermoid cyst. *Neurol Neurochir Pol* 44: 204-207.
2. Chou YW, Tien CH, Lee JS, Chuang MT (2015) Intradiploic Epidermoid Cyst in the Skull. *J Craniofac Surg* 26: e662-e663.
3. Bikmaz K, Cosar M, Bek S, Gokduman CA, Arslan M, et al. (2005) Intradiploic epidermoid cysts of the skull: a report of four cases. *Clin Neurol Neurosurg* 107: 262-267.

*Corresponding author: Amsiguine Najwa, Department of Pediatric Radiology, Hospital Ibn Sina, Faculty of medicine, Rabat, Morocco, E-mail: thealmanac101@gmail.com; ismail.m.halfi@gmail.com

Received: 16-Mar-2022, Manuscript No. roa-22-57383; **Editor assigned:** 18-Mar-2022, PreQC No. roa-22-57383 (PQ); **Reviewed:** 25-Mar-2022, QC No. roa-22-57383; **Revised:** 30-Mar-2022, Manuscript No. roa-22-57383 (R); **Published:** 06-April-2022, DOI: 10.4172/2167-7964.1000372

Citation: Najwa A, Zaynab IH, Ismail HM, Najlae L, Latifa C, et al. (2022) Intradiploic Epidermoid Cysts of a Child's Skull. *OMICS J Radiol* 11: 372.

Copyright: © 2022 Najwa A, et al. This is an open-access article distributed under the terms of the Creative Commons Attribution License, which permits unrestricted use, distribution, and reproduction in any medium, provided the original author and source are credited.