

Intratisssue Percutaneous Electrolysis (EPI®) in the Treatment of Achilles Tendinopathy

Jose Manuel Sánchez-Ibáñez*

Sports Rehabilitation Center (CEREDE), Barcelona, Spain

*Corresponding author: Jose Manuel Sánchez-Ibáñez, Sports Rehabilitation Center (CEREDE), Barcelona Clinic, Spain, Tel: +34 934 523 510; E-mail: drsanchez@cerede.es

Received date: December 12, 2016; Accepted date: December 16, 2016; Published date: December 19, 2016

Copyright: © 2016 Sánchez-Ibáñez JM. This is an open-access article distributed under the terms of the Creative Commons Attribution License, which permits unrestricted use, distribution, and reproduction in any medium, provided the original author and source are credited.

Intratisssue Percutaneous Electrolysis

Intratisssue percutaneous electrolysis (EPI®) ultrasound-guided treatment [1-5] is the application of a direct current (DC) whose catodic flow is transferred to the area of the degenerative tendon [6-8] using an acupuncture needle. This accumulated electrical charge (AEC) in the degenerative tissue will produce the activation of the molecular, cellular and biological processes necessary to restore the regeneration mechanisms of the tendon (Figures 1 and 2). In recent studies it has been demonstrated that EPI® technique is effective in tendinopathy and sport muscular injuries (Figures 3 and 4).

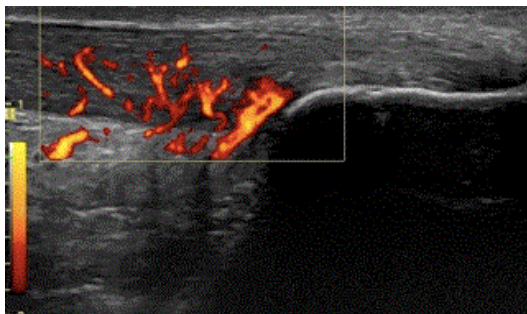


Figure 1: Ultrasound image with power Doppler. Longitudinal view of an Achilles neovascular tendinopathy with thickening of the tendon and hipoecoic image.

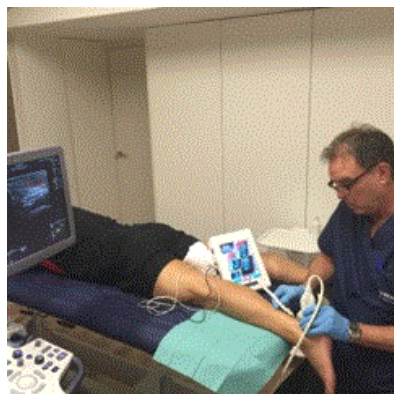

Figure 2: Achilles tendinopathy treatment using Intratisssue Percutaneous Electrolysis (EPI®) technique.

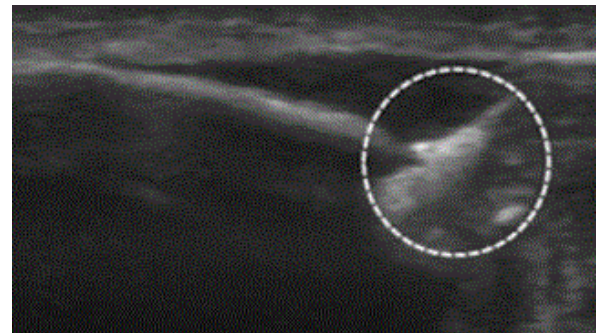


Figure 3: Hiperecoic image produced by the EPI® needle of 0.30 mm in the degenerative area of the tendon. This hiperecoic image correspondence to a gas density produced by the electrochemical response of the catodic flow (CF) in the degenerative extracellular matrix.

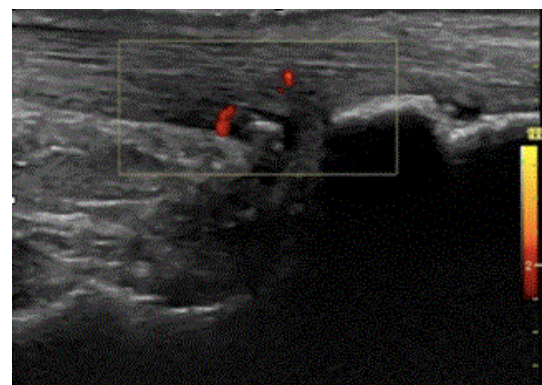


Figure 4: Ultrasound image in longitudinal view and color Doppler two months after the EPI® technique treatment ultrasound-guided. It is observed the degenerated area of the tendon that is substituted by a new connective tissue and decrease the neovascular effect.

References

1. Sánchez-Ibáñez JM (2015) Ultrasound-Guided EPI® Technique: New Treatment for Degenerative Tendinopathy. *J Nurs Care* 4: 310.
2. Sánchez-Ibáñez JM, Fernández ME, Monllau JC, Alonso-Díez A, Jesús Sánchez-García J, et al. (2015) New Treatments for Degenerative

-
- Tendinopathy, focused on the Region-Specific of the Tendon. *Rheumatology (Sunnyvale)* 5: 173.
3. Sánchez-Ibáñez JM, Fernández ME, Moreno C, Martí D, Belón P (2015) Ultrasound-Guided EPI® technique and eccentric exercise, new treatment for Achilles and Patellar tendinopathy focused on the region-specific of the tendon. *Orthop Muscular Syst* 4: 200.
 4. Abat F, Valles SL, Gelber PE, Polidori F, Sanchez-Ibáñez JM, et al. (2015) An experimental study of muscular injury repair in a mouse model of notexin-induced lesion with EPI® technique. *BMC Sports Sci Med Rehabil* 7: 7.
 5. Sanchez-Ibáñez JM, Colmena C, Benabent J, Garcia-Herreros S, Valles SL (2013) New Technique in Tendon Sport Recovery. *Percutaneous Electrolysis Intratissue (EPI®)*. *Int J Phys Med Rehabil* 1: 113.
 6. Abat F, Gelber P, Polidori F, Monllau JC, Sánchez-Ibáñez JM (2014) Clinical results after ultrasound-guided intratissue percutaneous electrolysis (EPI®) and eccentric exercise in the treatment of patellar tendinopathy over a 10-year follow-up. *Knee Surg Sports Traumatol Arthrosc* 23: 1046-1052.
 7. Sánchez-Ibáñez JM, Alves R, Polidori F, Valera F, Minaya F, et al. (2013) Effectiveness of ultrasound-guided EPI® technique in the treatment of insertional patellar tendinopathy in soccer players. *Br J Sports Med* 47: e2.
 8. Sánchez-Ibáñez JM (2008) Ultrasound guided percutaneous electrolysis (EPI) in patients with chronic insertional patellar tendinopathy: a pilot study. *Knee Surg Sports Traumatol Arthrosc* 16: 220-221.