

## Management of Skeletal Class II Malocclusion with Functional Regulator II

Shraddha Shetti<sup>1</sup>, Someshwar Golgire<sup>2</sup>, Anil Patil<sup>3\*</sup>, JiwanaAsha Manish Agrawal<sup>1</sup>, Sangamesh Guranath Fulari<sup>1</sup> and Vishwal Ajit Kagi<sup>4</sup>

<sup>1</sup>Orthodontics and Dentofacial Orthopaedics, Professor, Department of Orthodontics and Dentofacial Orthopaedics, Bharati Vidyapeeth Deemed University Dental College and Hospital, Sangli, Maharashtra, India

<sup>2</sup>Oral Pathology and Microbiology, Assistant Professor, Department of Oral Pathology and Microbiology, Bharati Vidyapeeth Deemed University, Dental College and Hospital, Sangli, Maharashtra, India

<sup>3</sup>Pedodontics and Preventive Dentistry, Associate Professor, Department of Pedodontics and Preventive Dentistry, Bharati Vidyapeeth Deemed University Dental College and Hospital, Sangli, Maharashtra, India

<sup>4</sup>Department of Orthodontics and Dentofacial Orthopaedics, Associate Professor, Bharati Vidyapeeth Deemed University Dental College and Hospital, Sangli, Maharashtra, India

### Abstract

A case report of an adolescent girl with a skeletal Class II malocclusion is presented. Early intervention of Class II malocclusion was frequently undertaken with objective of correcting skeletal disproportion by altering growth pattern and in case of remaining dental discrepancy a fixed mechanotherapy is obligatory. The need for early identification and intervention of the skeletal Class II malocclusion is universally accepted by dentofacial orthopaedicians. Thus, treatment in the mixed or early permanent dentition can produce favourable results. An 11 years old female patient with convex profile, lower lip trap, Class II skeletal as well as dental relation. The treatment started with Functional Regulator II to promote growth of mandible and improve her profile thus followed by fixed mechanotherapy to align and level dentition, close spaces and retract incisors. The intent of this article is to discuss early intervention of a skeletal class II malocclusion along with a rationale of orthodontic management of such patients.

**Keywords:** Frankel appliance; Functional regulator; Skeletal class II malocclusion

### Introduction

Skeletal Class II malocclusion is commonly observed clinical entity. A relatively common condition as it is easily recognized by dental health professionals and patients. The dentofacial characteristics with which patient reports to dentist often become an aesthetic and functional handicap for patient [1]. During Angle's era Class II cases are those with mandibular distocclusion [2]. According to Schudy there is the role of vertical growth increments in Class II development, similarly foot and shoe principle of Reichen Bach and Taatz transverse dimensions are also important in class II development [3].

The most interesting functional appliance that is Frankel functional regulator (FR) is used. The larger part of Frankel appliance is confined to oral vestibule, buccal shields and lip pads hold the buccal and labial musculature away from teeth and investing tissues eliminating possible restrictive influence from functional matrix [4]. Here in this case the successful use of Frankel appliance is because it is an exercise device stimulating normal function while eliminating lip trap, hyperactive mentalis and orbicularis oris action. Fulltime wear gave daily functional exercise during speaking, swallowing and facial expression become a form of muscle training [5]. Once the normal pattern of muscular behavior is achieved then the trained muscles should be capable of retaining and continuing the mandibular translation after FR II is removed.

### Case Presentation: Diagnosis and Etiology

A 11 year-old female patient presented with a chief complaint of unpleasant facial appearance while smiling also complained of forwardly placed upper front teeth. On intraoral examination the patient had Class II div 1 type of malocclusion with convex profile, slightly retruded mandible and lower lip trap habit accentuating the proclination of upper incisors and an increased display of teeth and gingiva.

Examination of the case was carried out following the standardized protocol and summarized herein:

### Extraoral examination (Figure 1)

#### A. Frontal View

- Facial symmetry: Apparently symmetrical
- Facial thirds: proportional
- Incisor exposure: 4 mm at rest

#### B. Profile view

- Facial profile: convex
- Lip protrusion: protruded with lower lip trap
- Chin: receding

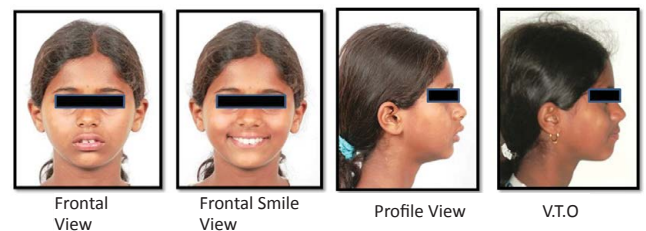


Figure 1: Extra oral Pretreatment photographs.

**\*Corresponding author:** Patil TA, MDS, Pedodontics and Preventive Dentistry, Associate Professor, Department of Pedodontics and Preventive Dentistry, Bharati Vidyapeeth Deemed University Dental College and Hospital, Sangli, Maharashtra, India-416414, Tel: +91 9850983500; E-mail: [dranilp0888@gmail.com](mailto:dranilp0888@gmail.com)

**Received** August 20, 2016; **Accepted** September 07, 2016; **Published** September 15, 2016

**Citation:** Shetti S, Golgire S, Patil A, Agrawal JAM, Fulari SG, et al. (2016) Management of Skeletal Class II Malocclusion with Functional Regulator II. *Pediatr Dent Care* 1: 118. doi: [10.4172/2573-444X.1000118](https://doi.org/10.4172/2573-444X.1000118)

**Copyright:** © 2016 Shetti S, et al. This is an open-access article distributed under the terms of the Creative Commons Attribution License, which permits unrestricted use, distribution, and reproduction in any medium, provided the original author and source are credited.

### Intraoral examination (Figure 2)

- Teeth present: Except third molars all compliment of teeth are present
- Molar relationship: end on bilaterally
- Canine relationship: end on bilaterally
- Overjet: 7 mm
- Overbite: 5 mm
- Midline: non-coincident

C. Habits: Sucking of lower lip

D. VTO: Positive

### Diagnosis

Angles Class II division 1 malocclusion on Skeletal Class II base with mild crowding in lower arch and spacing in upper arch (Figures 1-3).

The cephalometric findings supported the clinical findings of an orthognathic maxilla and retrognathic mandible with ANB of 8 degrees. The cervical vertebrae showed that she had 70-80% growth left.

### Treatment Plan

Considering the skeletal and dental discrepancy two treatment approaches were thought appropriate:

1. Functional appliance to correct underlying skeletal discrepancy (Figure 4).

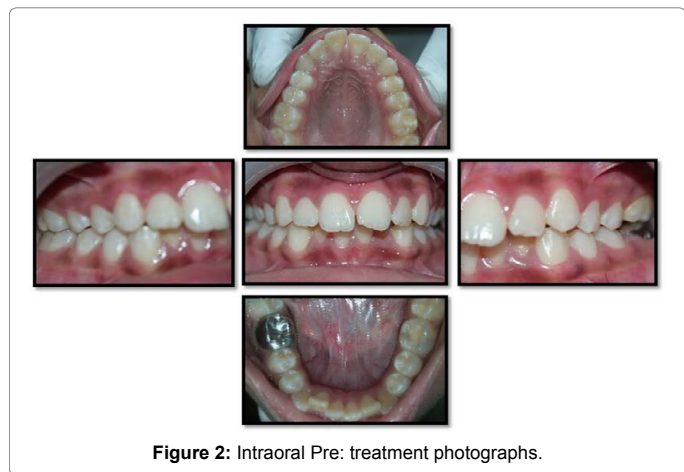


Figure 2: Intraoral Pre-treatment photographs.

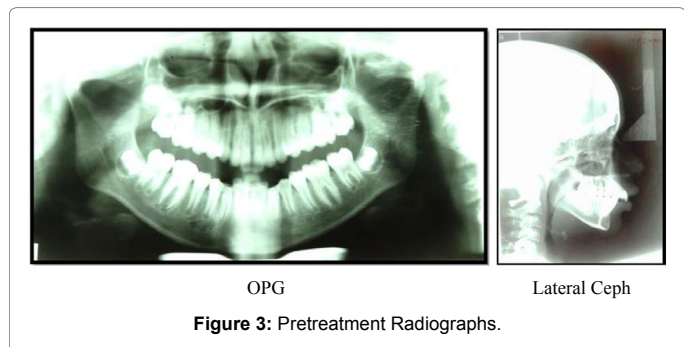


Figure 3: Pretreatment Radiographs.

2. Followed by fixed mechanotherapy for final detailing (Figure 5).

### Treatment objectives

Because of the skeletal nature of the malocclusion and anticipated good co-operation from the patient, a non-surgical orthodontic treatment plan was recommended. Following were the treatment objectives:

1. Improvement of soft tissue profile.
2. Achievement of well-aligned dental arches with class I canine and molar relationship.

### Treatment plan

Functional appliance therapy using Frankel Functional regulator II (FR II) was planned for mandibular protrusion followed by finishing & detailing using fixed appliances.

### Treatment progress

The impressions and construction bite for FR II were taken. The bite registration was taken so that mandible was advanced 6 mm in centric occlusion. Within one month patient had accommodated to appliance and was able to wear it on a full time basis (Approx 20 hours per day).The FR II was continued for two years on full time basis and part time basis(usually night only) for an additional one year. After one year of appliance wear was discontinued .Progress records obtained 15 months later, at age 13, showed full eruption of the permanent dentition and a stable occlusion. Cephalometric analysis indicated that mandibular protrusion and reduced overjet to about 3 mm was achieved. In the second phase of treatment, upper and lower arch strap-up was done using 0.022” MBT pre-adjusted edgewise appliance for the detailing of occlusion. The patient was reviewed every month during the fixed orthodontic treatment. Hawley’s retainer was given to patient for full time use for one year and thereafter night time use for six months (Figures 6-12).

### Discussion

Functional Regulator is intended to change or regulate the

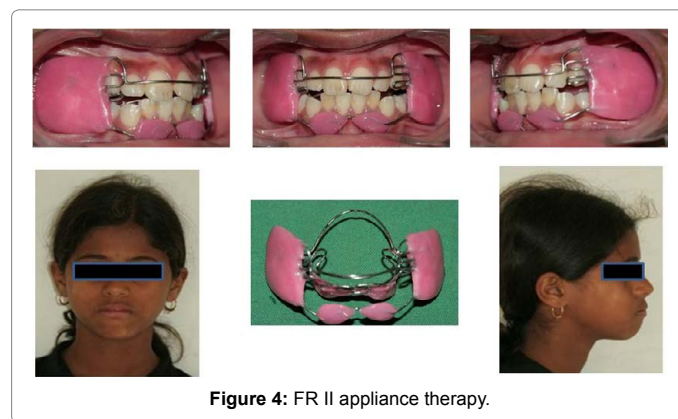


Figure 4: FR II appliance therapy.

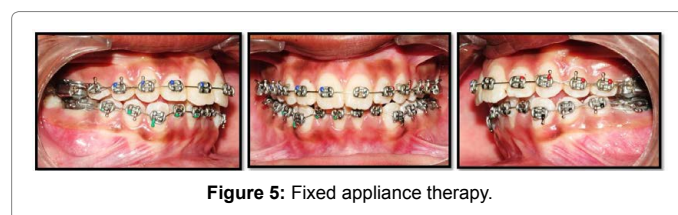


Figure 5: Fixed appliance therapy.

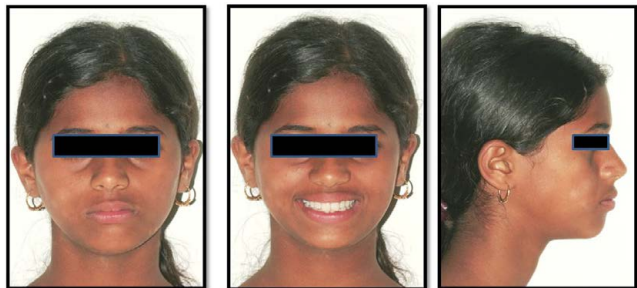

Figure 6: Post Functional Extra oral photographs.

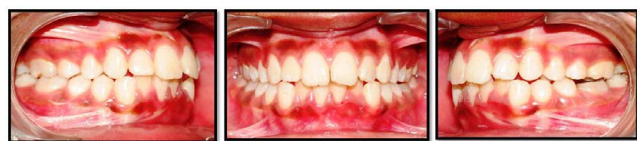

Figure 7: Post functional Intraoral Photograph.

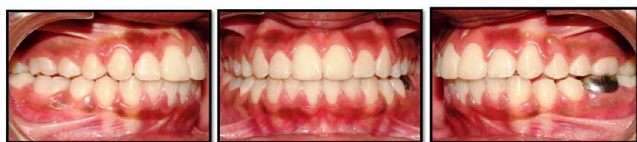

Figure 8: Post treatment: Intraoral photographs.

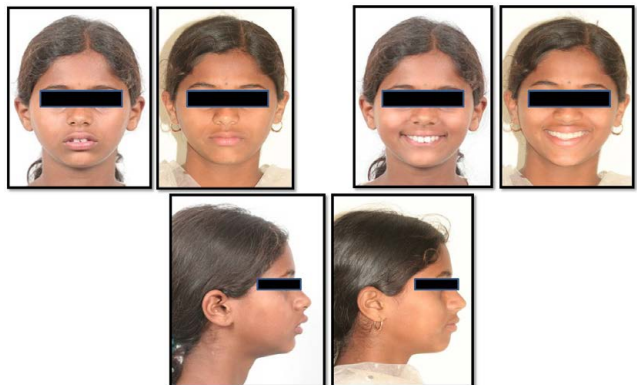

Figure 9: Comparison of Pre and Post treatment extra oral photographs.

muscular environment of face and teeth, to stretch facial musculature to normal dimensions, impede abnormal activity of lips, tongue, and cheeks and thus allows development of the jaws and teeth in all three planes thus it works the same irrespective of male and female patient with returned mandible [5]. Maturational status can have considerable influence on outcome of functional appliance therapy. Females attain peak growth earlier than males thus the Functional appliance therapy can take advantage of this peak so that female patients can be treated little earlier than males [6,7]. However growth continues in various forms until the age of 30 years and bone remodeling never ceases, being responsible for lifelong alterations of facial and jaw bones due to functional influence suggesting that Functional Regulator can do minimal skeletal and dental adaptations but they are insufficient to completely resolve patient's malocclusion at adult age [4]. Functional appliances have been used since 1930 despite their relatively long

history there continues to be much controversy relating to their use, mode of action and effectiveness. Although there are many functional appliances used by clinicians but Functional regulator has added advantage of muscle re-education preventing aberrant muscle force from acting on dentition and arches. Functional regulator thus can be used in all Skeletal Class II growing patients with fairly well aligned arches, positive VTO (Visual Treatment Objective) and good patient's cooperation for appliance wear. This is not the sole method of treating Class II patients but we indicate that it is one of the best appliances that should be considered while treating such cases [7].

This article describes dental and skeletal adaptations occurring in young growing patient treated with FR II. There is some improvement in overbite and overjet relationship. There was an improvement in the occlusion towards normal for the most part at the end of functional appliance therapy [6]. At the end of functional appliance therapy

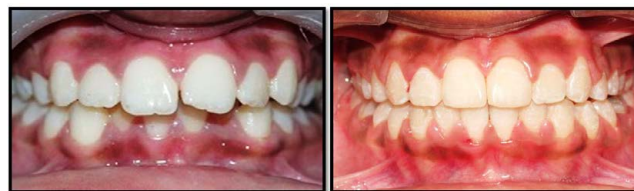

Figure 10: Comparison of Pre and Post treatment intraoral photographs.

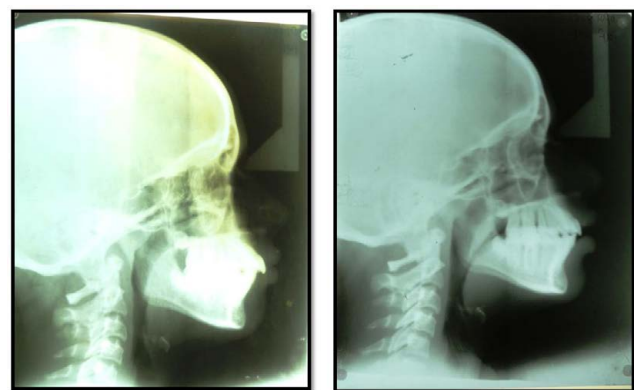


Figure 11: Comparison of Pre and Post treatment lateral cephalograms.

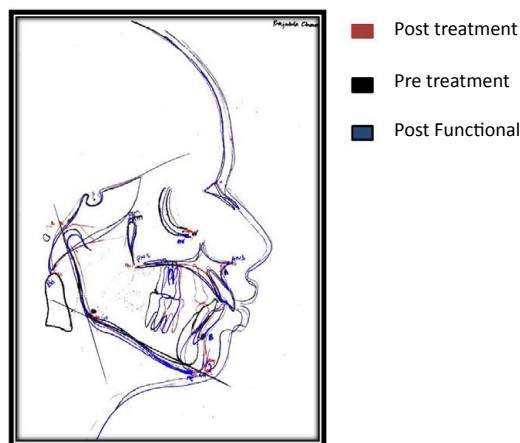


Figure 12: Superimposition.

skeletal bases got corrected with improvement in SNB from 74° to 79° and ANB from 8° to 3°. The effective length of mandible is increased by 4 mm. Once young patient undergoes functional jaw orthopaedic treatment for an extended period of time and does not achieve complete resolution of original orthodontic problem; the fixed appliance therapy was given for complete resolution of orthodontic problem [8]. Growth modulation in a growing patient is useful in improving the maxilla-mandibular relationship. The treatment was started as early as possible to take the advantage of the patient's pubertal growth spurt. The correction of Class II malocclusion with the FR II appliance maintains favourable results over the long term with both skeletal and dentoalveolar changes [9].

## Conclusion

The case report demonstrates that skeletal class II malocclusion on account of a retruded mandible can be successfully managed with the help of growth modulation by means of Frankel appliance therapy. It also improves skeletal bases along with soft tissue profile and gives better lip competence. An interception of malocclusion using growth modulation matches skeletal bases as well as eliminates potential deforming neuromuscular forces. As each patient differs from one another because of growth variability we just cannot generalized the appliance therapy. Careful case selection, application of knowledge and skills and good patient cooperation ensures long term stable results.

## References

1. Ricketts RM (1960) The influence of Orthodontic Treatment on facial growth and development. *Angle Orthod* 30: 103-133.
2. Frankel R (1969) The treatment of Class II div 1 malocclusion with Functional corrector. *Am J Orthod* 55: 265-275.
3. Schudy FF (1964) Vertical growth versus anteroposterior growth as related to function and treatment. *Angle Orthod* 34: 75-93.
4. McNamara JA (1984) Dentofacial adaptation in adult patients following Functional Regulator therapy. *Am J Orthod* 85: 57-71.
5. Samir EB, Robert RZ (1989) Functional Appliances. A review. *Am. J. Orthod* 95: 250-258.
6. Modi BN, Prakash AT, Shetty SK, Roy ET (2015) Skeletal Class II correction with Frankel appliance and driftodontics. *Indo-European Journal of Dental Therapy and Research* 4: 304-307.
7. Premkumar S (2013) Functional Appliances. *Textbook of Orthodontics*, Elsevier Publication; 533-542.
8. Graber LW, Robert L Vanarsdal Jr, Katherine WLV (2012) Optimizing Orthodontic and dentofacial orthopaedic treatment timing. *Orthodontics Current Principles and Techniques*. (5th edn) Elsevier Publication 497-501.
9. Freeman DC, McNamara JA Jr, Baccetti T, Franchi L, Fränkel C (2009) Long-term treatment effects of the FR II appliance of Frankel. *Am J Orthod dentofacial Orthop* 135: 570 e1-570 e6.