

## Ocular Manifestations of Rickettsial Disease

Nesrine Abroug, Sana Khochtali, Rim Kahloun, Anis Mahmoud, Sonia Attia and Moncef Khairallah\*

Department of Ophthalmology, Fattouma Bourguiba University Hospital, Faculty of Medicine, University of Monastir, Monastir, Tunisia

### Abstract

Rickettsioses are emergent and resurgent arthropod vector borne diseases due to obligate intracellular small gram-negative bacteria. Most of them are transmitted to humans by the bite of contaminated arthropods, such as ticks. Systemic disease typically consists of high fever, headache and skin rash, with or without «tache noire» (dark spot). Ocular involvement is common including conjunctivitis, keratitis, anterior uveitis, panuveitis, retinitis, retinal vascular changes, and optic nerve involvement. Proper clinical diagnosis of this infectious disease is based on epidemiological data, history, systemic symptoms and signs, and the pattern of ocular involvement. The diagnosis is usually confirmed by detection of specific antibodies in serum. Ocular involvement associated with rickettsial infection usually has a self-limited course, but it can result in persistent visual impairment. Doxycycline is the treatment of choice for rickettsial diseases but prevention is the mainstay of rickettsial infection control.

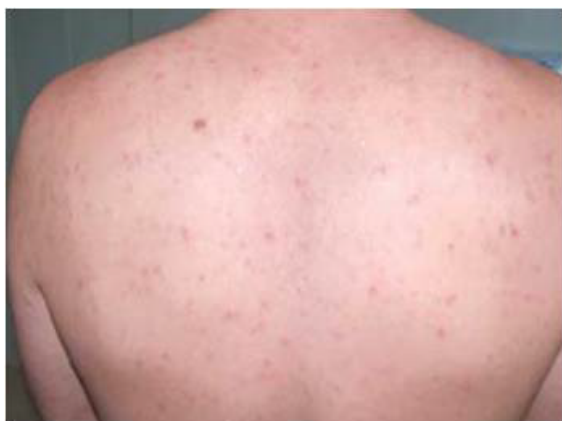**Keywords:** Rickettsioses; Retinitis; Uveitis; Optic neuropathy; Vasculitis

### Introduction

Rickettsioses are worldwide distributed zoonoses due to obligate intracellular small gram-negative bacteria. Most of them are transmitted to humans by the bite of contaminated arthropods, such as ticks. The majority of rickettsial organisms are known to invade small blood vessels causing endothelial injury and tissue necrosis, with subsequent development of a host mononuclear-cell tissue response and stimulation of coagulation process, resulting in a systemic edematous and occlusive vasculitis [1]. Systemic involvement is typically characterized by a triad of high fever, headache and general malaise, and skin rash in a patient living in or traveling back from a region endemic for rickettsioses. Ocular involvement is common, but frequently asymptomatic and overlooked. Diagnosis of rickettsial disease is usually based on clinical features confirmed by positive serologic testing. Doxycycline is the drug of choice for the treatment of rickettsiosis but prevention is the mainstay of rickettsial infection control. This article will review ocular manifestations of rickettsial diseases that are relevant to ophthalmologist, as well as infectious disease specialist.

### Epidemiology

Rickettsial agents are classified into three major categories: the spotted fever group, the typhus group, and the scrub typhus [1,2]. The



**Figure 1a:** Generalized maculo-papular skin rash in a patient with Mediterranean spotted fever

spotted fever group includes Mediterranean spotted fever (MSF), Rocky Mountain spotted fever (RMSF), and numerous other rickettsioses. MSF, also called “boutonneuse” fever or tick-borne rickettsiosis is caused by *Rickettsia (R.) conorii* and is prevalent in Mediterranean countries and Central Asia, including India. Rocky Mountain spotted fever, which is caused by *R. rickettsii*, is endemic in parts of North, Central, and South America, especially in the south-eastern and south-central United States. The other multiple rickettsial species belonging to the spotted fever group vary in their geographic distribution. The typhus group includes Epidemic typhus and Murine typhus. Epidemic typhus, which is caused by the organism *R. prowazekii*, is usually encountered in areas of crowded population with poor hygiene conditions, as occurs during wars and natural disasters. Murine typhus, which is caused by *R. typhi*, is found worldwide in warm-climate countries. Scrub typhus, which is caused by *Orientia tsutsugamushi*, is a zoonosis found in the Far East [1,2].

### Systemic disease

Rickettsial disease usually occurs in late spring or summer, when the tick vectors are most active. A history of outdoor activities, occupational exposure, or tick attachment is frequent [1,2]. After an asymptomatic incubation of 5 to 7 days, the onset of the disease is abrupt and typical cases present with high fever, headache, general malaise and skin rash (Figure 1a). The skin rash is usually generalized, maculopapular in type, often involving the palms and soles but sparing the face. A local skin lesion, termed “tache noire” (black spot), may develop at the site of arthropod bite in 50% to 75% of the patients with MSF, and in several other rickettsioses (Figure 1b).

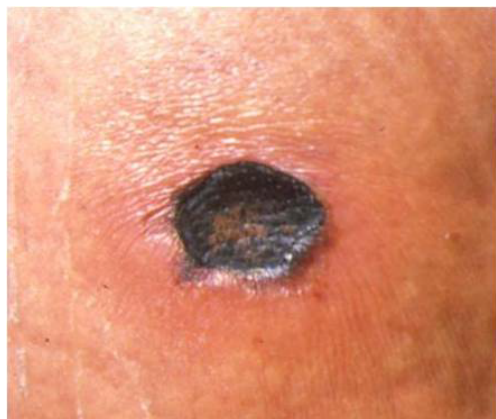Prognosis of systemic infection is good in most cases, and patients will recover within 10 days without any sequelae. However, severe complications including major neurological manifestations and multiorgan involvement occur in 5% to 6% of the cases, and the mortality rate is 2% to 3% [3-5].

**\*Corresponding author:** Moncef Khairallah, Department of Ophthalmology, Fattouma Bourguiba University Hospital, 5019 Monastir, Tunisia, Tel: 21673461144; Fax: 21673460678; E-mail: [moncef.khairallah@rms.tn](mailto:moncef.khairallah@rms.tn)

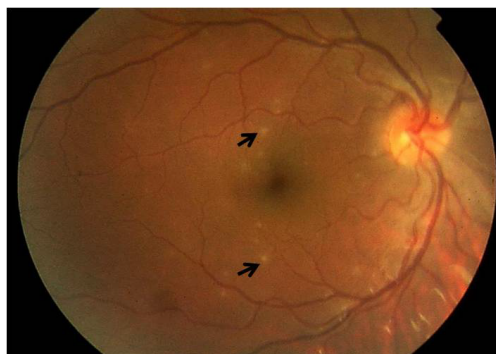
Received February 28, 2014; Accepted April 24, 2014; Published April 27, 2014

**Citation:** Abroug N, Khochtali S, Kahloun R, Mahmoud A, Attia S, et al. (2014) Ocular Manifestations of Rickettsial Disease. J Infect Dis Ther 2: 140. doi:10.4172/2332-0877.1000140

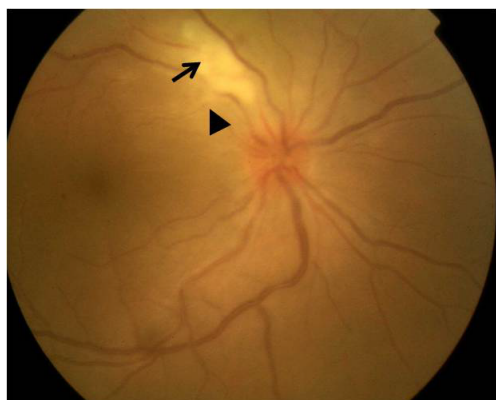
**Copyright:** © 2014 Abroug N, et al. This is an open-access article distributed under the terms of the Creative Commons Attribution License, which permits unrestricted use, distribution, and reproduction in any medium, provided the original author and source are credited.



**Figure 1b:** Dark spot "Tache noire" in a patient with Mediterranean spotted fever.



**Figure 2a:** Fundus photograph of the right eye shows multiple small retinal white lesions consistent with inner retinitis (arrows) in a 19-year old patient with Mediterranean spotted fever, and no ocular complaints.



**Figure 2b:** Fundus photograph of the right eye shows a supra-papillary white retinal lesion (arrow) with associated vascular sheathing (arrowhead) in a 43-year-old woman with Mediterranean spotted fever and blurred vision in the right eye.

## Ocular disease

Ocular involvement is common in patients with rickettsioses, but since it is frequently asymptomatic and self-limited, it may be easily overlooked [6,7]. However, rickettsial ocular disease may be associated

with ocular complaints, such as decreased vision, scotomas, floaters, or redness. Retinitis, retinal vascular involvement, and optic disc changes are the most common ocular findings, but numerous other manifestations may occur.

**Adnexal and anterior segment manifestations:** Contamination of the conjunctiva by a spurt of tick blood, resulting in unilateral conjunctivitis, is a potential portal of entry for *R. rickettsii*, as well as *R. conorii* infection [8,9]. Bilateral conjunctivitis has been reported in association with MSF as well as RMSF [10]. Conjunctival petechiae, subconjunctival hemorrhages, keratitis, nongranulomatous anterior uveitis, and iris nodule have also been described in association with rickettsial infection [8,11,12].

**Retinochoroidal involvement:** Retinochoroidal involvement is common in patients with rickettsiosis. In a prospective study by Khairallah et al., 80% of patients with acute MSF examined by ophthalmoscopy and fluorescein angiography were found to have chorioretinal involvement, which was frequently asymptomatic [7]. Because the diagnosis of chorioretinal involvement in rickettsioses may be easily overlooked, a careful dilated fundoscopic examination, complemented with fluorescein angiography in selected cases, is recommended. Retinitis and retinal vascular changes are the most common and typical manifestations of rickettsial infection.

**Retinitis:** Inner retinitis with or without associated mild or moderate vitritis, is the most common clinical finding [7,13-17]. It is observed in at least 30% of patients with acute MSF [7]. Retinitis presents in the form of white retinal lesions, typically adjacent to retinal vessels. These lesions may vary in number, size, and topography (Figure 2a-c). Fluorescein angiography shows early hypofluorescence and late staining of large retinal lesions and isofluorescence or moderate hypofluorescence of small active retinal lesions throughout the whole angiogram [7]. The pathogenesis of rickettsial retinitis remains speculative. White retinal lesions could result from intraretinal rickettsial multiplication. Alternatively, immune response to bacteremia could lead immune complexes and inflammatory cells to form white infiltrates through deposition in retinal vessels [7].

Serous retinal detachment, accurately detected by optical coherence tomography (OCT), frequently accompanies large foci of rickettsial retinitis.

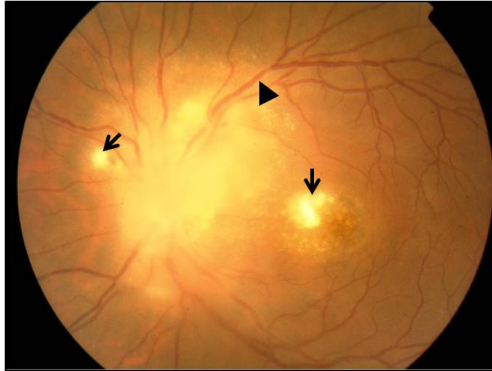
There are reports of multiple small white retinal lesions in other rickettsioses, including RMSF, Queensland tick typhus, and murine typhus [18-23]. Multiple retinal lesions similar to those seen in multiple white dot syndrome (MEWDS) have also been reported [11,24].

Rickettsial retinitis has a self-limited evolution in most patients, with resolution of white retinal lesions, typically without scarring, in several weeks.

### Retinal vascular involvement

Retinal vascular lesions in patients with rickettsial disease may include focal or diffuse vascular sheathing (Figure 2b), vascular leakage, intraretinal, white-centered, or subretinal hemorrhages, and retinal vascular occlusions. The latter are associated with transient or permanent visual loss, and manifest as branch and central artery occlusion, and branch retinal vein occlusion or subocclusion [6,7,25-29].

**Other retinochoroidal changes:** They include, cystoid macular edema, macular star, and hypofluorescent choroidal lesions on fluorescein and indocyanine green angiography [7,30]. A case of



**Figure 2c:** Fundus photograph of the left eye shows optic disc swelling and macular star consistent with neuroretinitis, in association with two lesions of retinitis (arrows) and vascular sheathing (arrowhead) in a 33-year old patient with Mediterranean spotted fever and vision loss in the left eye.

endogenous endophthalmitis caused by *R. conorii* has been reported [31].

**Neuro-ophthalmic manifestations:** Optic disc involvement, with or without associated visual loss, has been described in association with rickettsial infection, including optic disc edema, optic disc staining, optic neuritis, neuroretinitis (Figure 2c), and ischemic optic neuropathy. Third and sixth cranial nerve palsies have also been reported in this setting [6,7,13-15,30,32-35].

## Diagnosis

Diagnosis of rickettsial infection is usually suspected on the basis of clinical features (ocular and systemic) and epidemiologic data. It is confirmed by positive indirect immunofluorescent antibody test results. Positive serologic criteria usually include either initial high antibody titer or a fourfold rise of the titer in the convalescent serum. Case confirmation with serology might take 2 to 3 weeks. Other laboratory tests, such as serologic testing using western blot or detection of rickettsiae in blood or tissue using polymerase chain reaction, may be useful in selected cases [1,7,13-15].

Ocular examination, revealing frequently abnormal, fairly typical findings is helpful in diagnosing a rickettsial disease, particularly in incomplete and atypical systemic presentation, while serologic testing is pending [7].

## Differential Diagnosis

The differential diagnosis of rickettsiosis includes numerous systemic infectious and noninfectious diseases manifesting with febrile illness, such as typhoid fever, measles, rubella, enteroviral infection, meningococemia, disseminated gonococcal infection, secondary syphilis, leptospirosis, cat scratch disease, infectious mononucleosis, arbovirus infection, Kawasaki disease, Behçet's disease and other systemic vasculitic disorders, idiopathic thrombocytopenic purpura, and drug reaction. Other important causes of retinitis and vasculitis such as toxoplasmosis, syphilis, cat scratch disease, viral diseases, and sarcoidosis should also be considered [13-15].

## Treatment

Early treatment is critical to outcome and must be started on the basis of clinical diagnosis. Doxycycline (100 mg every 12 hours

for 7 to 10 days) is the drug of choice for the treatment of rickettsial diseases. Antibiotic treatment may be terminated 48 hours after the patient is afebrile. Other tetracyclines, chloramphenicol (50-75 mg/Kg/day), and fluoroquinolones are also effective. Both tetracyclines and chloramphenicol have potential significant adverse effects, especially in children. Macrolides, including clarithromycin, azithromycin, and particularly josamycin can be used as alternative therapy in children and pregnant women [1].

Additional therapeutic agents may be required for ocular disease: topical antibiotics for conjunctivitis or keratitis, topical steroids and mydriatic drops for anterior uveitis, systemic steroids for severe ophthalmic involvement, such as extensive retinitis threatening the macula or optic disc, serous retinal detachment, macular edema, retinal vascular occlusion, severe vitritis, and optic neuropathy, and anticoagulant agents for retinal vascular occlusions. The role of antibiotic therapy, as well as that of oral steroids, on the course of posterior segment involvement, remains unknown. The effect of anticoagulants on the course of retinal occlusive complications is also unclear [7,13-15].

Prevention is the mainstay of rickettsial diseases control. It consists of personal protection against tick bites in endemic areas (repellents, protective clothing), and avoidance of dogs, detection and removal of an attached tick), improvement of sanitary conditions including the control of rat reservoirs and of flea or lice vectors.

## Prognosis

Although prognosis of systemic infection is good in most cases, rickettsioses may be severe and potentially lethal, and should be treated accordingly [1].

Ophthalmic manifestations of rickettsioses have a self-limited evolution in most patients, disappearing between the 3<sup>rd</sup> and 10<sup>th</sup> week after the first examination. Posterior segment involvement associated with rickettsial disease has a good overall visual outcome. Persistent decreased vision may occur due to retinal changes secondary to macular edema or serous retinal detachment, retinal artery or vein occlusion, foveal chorioretinal scar, optic neuropathy or choroidal neovascularisation [36].

## Conclusion

The best diagnostic tool of rickettsial infection relies on a high index of suspicion in the presence of the triad of high fever, headache and general malaise, and skin rash in a patient living in or traveling back from a region endemic for rickettsioses. Ocular involvement in rickettsioses is common, but is frequently asymptomatic and easily overlooked. Retinitis presenting as small or large white retinal lesions associated with mild or moderate vitritis, retinal vascular lesions, and optic nerve involvement are the most common findings.

Typical ocular manifestations are helpful in diagnosing a rickettsial disease, while serologic testing is pending. Systematic fundus examination should be part of the routine evaluation of any patient who presents with fever and/or skin rash living in or returning from a specific endemic area.

## Financial disclosure

No financial interest for all authors

## Acknowledgment

This work has been supported by the Ministry of Higher Education and Research of Tunisia.

## References

1. Parola P, Raoult D. Rickettsioses éruptives. EMC (Elsevier Paris) Maladies infectieuses, 8-037-I-20, 1998, 24p.
2. Mc Dade JE (1998) Rickettsial diseases. In: Hausler WJ, Sussman M, eds. Topley and Wilson's Microbiology and Microbial Infections, 9th ed. London: Arnold 3:995-1011.
3. Amaro M, Bacellar F, França A (2003) Report of eight cases of fatal and severe Mediterranean spotted fever in Portugal. *Ann N Y Acad Sci* 990: 331-343.
4. Renvoisé A, Raoult D (2009) An update on rickettsiosis. *Med Mal Infect* 39: 71-81.
5. Jemni L, Hmouda H, Chakroun M, Ernez M, May M (1994) Mediterranean Spotted Fever in Central Tunisia. *J Travel Med* 1: 106-108.
6. Alió J, Ruiz-Beltran R, Herrero-Herrero JI, Hernandez E, Guinaldo V, et al. (1987) Retinal manifestations of Mediterranean spotted fever. *Ophthalmologica* 195: 31-37.
7. Khairallah M, Ladjimi A, Chakroun M, Messaoud R, Yahia SB, et al. (2004) Posterior segment manifestations of Rickettsia conorii infection. *Ophthalmology* 111: 529-534.
8. Bazin R. (2002) Rickettsial diseases. In: Foster F, Vitale A, (Eds). Diagnosis and Treatment of Uveitis. Philadelphia: WB Saunders Company 297-304.
9. Pinna A, Sotgiu M, Carta F, Zanetti S, Fadda G (1997) Oculoglandular syndrome in Mediterranean spotted fever acquired through the eye. *Br J Ophthalmol* 81: 172.
10. Helmick CG, Bernard KW, D'Angelo LJ (1984) Rocky Mountain spotted fever: clinical, laboratory, and epidemiological features of 262 cases. *J Infect Dis* 150: 480-488.
11. Alio J, Ruiz-Beltran R, Herrera I, Artola A, Ruiz-Moreno JM (1992) Rickettsial keratitis in a case of Mediterranean spotted fever. *Eur J Ophthalmol* 2: 41-43.
12. Cherubini TD, Spaeth GL (1969) Anterior nongranulomatous uveitis associated with Rocky Mountain spotted fever. First report of a case. *Arch Ophthalmol* 81: 363-365.
13. Khairallah M, Jelliti B, Jenzeri S (2009) Emergent infectious uveitis. *Middle East Afr J Ophthalmol* 16: 225-238.
14. Khairallah M, Chee SP, Rathinam SR, Attia S, Nadella V (2010) Novel infectious agents causing uveitis. *Int Ophthalmol* 30: 465-483.
15. Khairallah M, Yahia SB, Attia S (2010) Arthropod vector-borne uveitis in the developing world. *Int Ophthalmol Clin* 50: 125-144.
16. Khairallah M, Ben Yahia S, Toumi A, Jelliti B, Loussaief C, et al. (2009) Ocular manifestations associated with murine typhus. *Br J Ophthalmol* 93: 938-942.
17. Khairallah M, Yahia SB, Jelliti B, Ben Romdhane F, Loussaief C, et al. (2009) Diagnostic value of ocular examination in Mediterranean spotted fever. *Clin Microbiol Infect* 15 Suppl 2: 273-274.
18. Raab EL, Leopold IH, Hodes HL (1969) Retinopathy in Rocky Mountain spotted fever. *Am J Ophthalmol* 68: 42-46.
19. Presley GD (1969) Fundus changes in Rocky Mountain spotted fever. *Am J Ophthalmol* 67: 263-267.
20. Smith TW, Burton TC (1977) The retinal manifestations of Rocky Mountain spotted fever. *Am J Ophthalmol* 84: 259-262.
21. Duffey RJ, Hammer ME (1987) The ocular manifestations of Rocky Mountain spotted fever. *Ann Ophthalmol* 19: 301-303, 306.
22. Lukas JR, Egger S, Parschalk B, Stur M (1998) Bilateral small retinal infiltrates during rickettsial infection. *Br J Ophthalmol* 82: 1217-1218.
23. Hudson HL, Thach AB, Lopez PF (1997) Retinal manifestations of acute murine typhus. *Int Ophthalmol* 21: 121-126.
24. Esgin H, Akata F (2001) Bilateral multiple retinal hyperfluorescent dots in a presumed Rickettsia conorii infection. *Retina* 21: 535-537.
25. Lu TM, Kuo BI, Chung YM, Liu CY (1997) Murine typhus presenting with multiple white dots in the retina. *Scand J Infect Dis* 29: 632-633.
26. Paufique L, Bonnet M, Lequin, Didierlaurent (1964) Retinal vascular thromboses and rickettsioses. *Bull Soc Ophthalmol Fr* 64: 410-415.
27. Verdout S, Estavoyer JM, Prost F, Montard M (1986) Ocular involvement in acute phase of Mediterranean boutonneuse fever. *Bull Soc Ophthalmol Fr* 86: 429-431.
28. Adan A, Lopez-Soto A, Moser C, Coca A (1988) Use of steroids and heparin to treat retinal arterial occlusion in Mediterranean spotted fever. *J Infect Dis* 158: 1139-1140.
29. Nagaki Y, Hayasaka S, Kadoi C, Matsumoto M, Sakagami T (2001) Branch retinal vein occlusion in the right eye and retinal hemorrhage in the left in a patient with classical Tsutsugamushi disease. *Jpn J Ophthalmol* 45: 108-110.
30. Vaphiades MS (2003) Rocky Mountain Spotted Fever as a cause of macular star figure. *J Neuroophthalmol* 23: 276-278.
31. Mendivil A, Cuartero V (1998) Endogenous endophthalmitis caused by Rickettsia conorii. *Acta Ophthalmol Scand* 76: 121-122.
32. Bronner A, Payeur G (1973) Hemorrhagic papillitis and rickettsiosis. *Bull Soc Ophthalmol Fr* 73: 355-358.
33. Castanet J, Costet C, Dubois D, Lacour JP, Ortonne JP (1988) Optic neuropathy in Mediterranean boutonneuse fever. *Presse Med* 17: 439-440.
34. Granel B, Serratrice J, Rey J, Conrath J, Disdier P, et al. (2001) Impaired visual acuity in Mediterranean boutonneuse fever. *Presse Med* 30: 859.
35. Khairallah M, Zaouali S, Ben Yahia S, Ladjimi A, Messaoud R, et al. (2005) Anterior ischemic optic neuropathy associated with rickettsia conorii infection. *J Neuroophthalmol* 25: 212-214.
36. Kahloun R, Gargouri S, Abroug N, Sellami D, Ben Yahia S, et al. (2013) Visual Loss Associated with Rickettsial Disease. *Ocul Immunol Inflamm*.