

Ocular, Neurological and Hearing Affection as Extra Intestinal Manifestation of Ulcerative Colitis: Case Presentation

Fatma Adel, Islam El Zayadi and Maha M Maher*

Department of Gastroenterology and Hepatology, Specialized Medical Hospital, Mansoura University, Egypt

Abstract

Patients with Inflammatory Bowel Disease (IBD) are presented commonly with intestinal and extra intestinal manifestations.

Here we present a case 24 year old male, presented to our IBD clinic by bloody diarrhea; he was diagnosed as auto immune hemolytic anemia four years ago and continued on small dose steroid. He had abnormal gait, with diminution of vision and hearing.

Here we present this case that gathers some of rarest extra intestinal manifestations associated with ulcerative colitis including hematological, ocular, neurological and hearing. So, as they say calamities do not usually come alone, but fortunately these manifestations were diagnosed early and our patient received steroid and antiTNF and was clinically much better.

Keywords: Inflammatory bowel disease; Intestinal manifestations; Ulcerative colitis; Hematological; Ocular; Neurological and hearing

Abbreviations: IBD: Inflammatory Bowel Disease; CBC: Complete Blood Count; WBCs: White Blood Cell; HB: Hemoglobin; MCV: Mean Corpuscular Volume; fl: Femtoliter; INR: International Normalized Ratio; LDH: Lactate Dehydrogenase; TIBC: Total Iron Binding Capacity; ALT: Alanine Transferase; AST: Aspartate Transferase; ALP: Alkaline Phosphatase; ASMA: Anti-Smooth Muscle Antibody; HBs-Ag: Hepatitis B Surface Antigen; HbC-Ab IgM: Hepatitis B Core Immunoglobulin M; HAV IgM: Hepatitis A Immunoglobulin A; HCV Ab: Hepatitis C Antibody; HIV Ab: Human Immune Deficiency Antibody; ESR: Erythrocyte Sedimentation Rate; CRP: C-Reactive Protein ANA: Antinuclear Antibody; Anti ds DNA: Anti Double Stranded DNA; ANCA P: Perinuclear Anti-Neutrophil Cytoplasmic Antibodies; ANCA C: Cytoplasmic Anti-Neutrophil Cytoplasmic Antibodies; RF: Rheumatoid Factor; C3C4: Complement 3 and 4; Ig: Immunoglobulin; US: Ultrasonography; CT: Computerized Tomography; 5-ASA: 5 Amino Salicylic Acid; MRI: Magnetic Resonance Imaging; EMG: Electromyography; OCT: Optical Coherence Tomography; SNHL: Sensory Neural Hearing Loss; UC: Ulcerative Colitis; CD: Crohn's Disease; VKH: Vogt-Koyanagi-Harada; PNS: Peripheral Nervous System; CNS: Central Nervous System

Introduction

Patients with Inflammatory Bowel Disease (IBD) are presented commonly with intestinal and extra intestinal manifestations. Extra intestinal manifestations are usually associated with active bowel disease, but can also occur prior to bowel disease or during periods of remission. These manifestations may include: ocular, neurological, and hematological or involve skin, liver and lung. The overall prevalence of any extra-intestinal manifestation in IBD patients ranges from 21%-40% [1]. Here we present a case of active ulcerative colitis with many extra intestinal manifestations including ocular, neurological and hearing affection all presented in one patient.

Case Report

A 24 year old male, unemployed, single, with no special habits of medical importance, presented to our IBD clinic, Specialized Medical Hospital, Mansoura university by diarrhea, 6 times per day, occasionally bloody few months ago. This study highlights an adult endoscopist's

experience in bridging the gap of pediatric gastrointestinal endoscopy service in a developing country, Nigeria.

On November 2012, he was diagnosed as auto immune hemolytic anemia and did splenectomy with postoperative pneumonia and was treated in the chest department for 3 months. His treatment continued on small dose steroid 10 mg/day. On examination he was fully conscious but pale, average built, abnormal gait, with diminution of vision and hearing. His lower limbs showed bilateral weakness, hypotonia, hyporeflexia and impaired sensation. Vital signs: blood pressure: 100/60, pulse 110/min, respiratory rate: 24/min, temperature: 37.5°C. Chest examination: there were left sided mid-zonal crepitation, heart: tachycardia. No abnormal skin rash or arthritis, intact peripheral pulsations. He was admitted, his laboratory testing showed:

- **Complete Blood Count:** hemoglobin was 7 gm/dl, MCV: 92 fl, Platelets: 370/cmm³, WBCs: 17/cmm³, Reticulocytic count: 7%, INR: 1.2, LDH: 2400 U/I (100-190), Ferritin: 2720 ng/ml (21-274), TIBC: 200 ug/dl (250-410). Creatinine: 0.8 mg/dl, uric acid: 4.9, Urinalysis: NAD.
- **Serum albumin:** 3.4 g/dl, serum bilirubin: 5.6 mg/dl (direct) 0.7 mg/dl, ALT: 20 mg/dl, AST: 30 mg/dl, ALP: 126(N), ASMA: -ve, HBs-Ag, HbC -Ab IgM, HAV IgM, HCV Ab, HIV Ab: all are -ve.
- **Serum calcium:** 8.4 mg/dl, serum sodium: 142 mmol/l, serum potassium: 4.3 mmol/l, ESR: 70, CRP: 60, Coombs': (direct) +ve, ANA: -ve, Anti ds DNA: -ve, ANCA P: +ve, ANCA C: -ve, RF:

*Corresponding author: Dr. Maha M Maher, Department of Gastroenterology and Hepatology, Specialized Medical Hospital, Mansoura University, Egypt, Tel: +00201225100527; E-mail: mahamaher66@hotmail.com

Received April 18, 2019; Accepted May 16, 2019; Published May 23, 2019

Citation: Adel F, El Zayadi I, Maher MM (2019) Ocular, Neurological and Hearing Affection as Extra Intestinal Manifestation of Ulcerative Colitis: Case Presentation. J Gastrointest Dig Syst 9: 596.

Copyright: © 2019 Adel F, et al. This is an open-access article distributed under the terms of the Creative Commons Attribution License, which permits unrestricted use, distribution, and reproduction in any medium, provided the original author and source are credited.

-ve: C3, C4: NAD, Lupus anticoagulants : Anticardiolipin Ig G : +ve , Anticardiolipin Ig M: -ve.

- **His radiology included:** chest x-ray which showed bilateral mild pleural effusion. Abdominal US: showed mildly enlarged liver, surgically removed spleen, no detected masses or collections, trans thoracic echo: was normal. CT chest: showed Mild left side pleural effusion with related posterior basal consolidation collapse .Patchy areas of ground glass opacity in the posterior segments of the right lower lung lobes. Post contrast CT abdomen showed: moderate hepatomegaly, recto-sigmoid colon show circumferential wall thickening up to 1 cm with blurred fat planes (Figure 1).

Colonoscopy was done till the cecum and it showed severe inflammation and superficial ulcerations involving the rectum, multiple biopsies were taken; that revealed ulcerated mucosa with distortion and destruction of glands, some showing mucin depletion, severe inflammatory infiltrate mainly lymphocytes, plasma cells, neutrophils and eosinophils, lymphoid aggregates are detected, picture suggestive of active ulcerative colitis.

Patient was treated after blood transfusion by intravenous corticosteroid 1 mg/kg/day, budesonide enema once/ day, 5-ASA 3 gm/day, ciprofloxacin 500mg twice daily, metronidazole 500mg every 8 hours. Azathioprine was started by dose 1.5-2 mg/kg/day. His clinical condition was better, hemolysis was controlled and bloody diarrhea was stopped. His last lab: CBC: WBCs: 8 /cmm³, Hb: 11 gm/dl (13-17 gm/dl), MCV: 101 fl (80-96 fl), Platelets: 533 /cmm³ (150-450/cmm³). Serum bilirubin: 2 mg/dl (direct) 0.3 mg/dl (0.1-1.2 mg/dl).

Neurological consultation ordered: MRI brain that was free, Nerve conduction study and EMG of both upper limbs and lower limbs and it showed: demyelinating neuropathy. They gave recommendation to continue on high dose oral steroid.

Ophthalmology consultation advised OCT scan of both eyes that showed: normal thickness in all quadrants except mild thinning of the inferior quadrant of the right eye. Fundus examination revealed: bilateral multifocal choroiditis, with fluorescein angiography: right exudative retinal detachment, probably Harada disease. They recommended systemic steroid and intra-vitreal injection of steroid (Figure 2).

As for diminution of hearing we consulted ENT specialists , who reported that he had bilateral normal tympanic membrane, his audiogram showed bilateral severe Sensory Neural Hearing Loss

(SNHL) with poor discrimination, probably hereditary SNHL, and advised him to wear hearing aid.

At that time decision was made to start biological therapy antiTNF and patient started adalimumab by dose 160mg SC, then after 2 weeks 80 mg SC, then maintained on 40 mg SC every 2 weeks (Figure 3).

Discussion

Extra intestinal manifestations are common in patients with IBD including Crohn's Disease (CD) and Ulcerative Colitis (UC). Although management of such patients usually involves controlling the active disease, some patients can still be symptomatizing. A multispecialty approach to the care of these patients will be very helpful in optimizing management [1].

These manifestations may involve the skin: erythema nodosum and pyoderma gangrenosum, joint: peripheral arthritis especially in large joints without synovial destruction, ankylosing spondylitis, liver: sclerosing cholangitis, lung disease: decrease in lung diffusing capacity or disabling bronchiectasis, venous and arterial: thromboembolism, and hematological: autoimmune hemolytic anemia [2].

Our case showed a lot of extra intestinal manifestations of ulcerative colitis as hematological, ocular, neurological and hearing manifestations, but we will spot mainly three unusual manifestations related to eye, nerves and hearing.

Ocular manifestation: ocular complications occur in approximately 3% of patients with IBD, and are more frequent in ulcerative colitis than Crohn's disease. The major eye complications include episcleritis, scleritis, and uveitis. Episcleritis is inflammation of the vascular layer directly beneath the conjunctiva. Scleritis is inflammation of deep scleral vessels, while uveitis includes inflammation of the iris, vitreous, choroids, or retina. Patients typically present with acute redness, pain, and vision changes. These conditions usually respond well to treatment of the underlying bowel disease. Patients with episcleritis may also respond to topical steroids [3]. Scleritis and uveitis are more likely to respond to systemic treatment and should be managed in conjunction with treatment by a specialist as in our case.

Vogt-Koyanagi-Harada (VKH) syndrome or uveo-meningoencephalitis is an autoimmune disorder of melanocyte proteins in genetically susceptible individuals [4]. It is more common in Asians with peak incidence in patients in their thirties [5]. Antibodies against melanin in eyes, hair, central nervous system, inner ear, and skin have

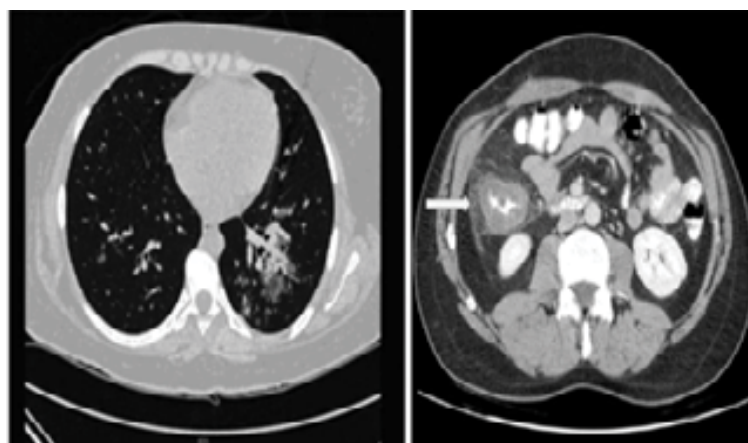


Figure 1: Recto-sigmoid colon show circumferential wall thickening up.

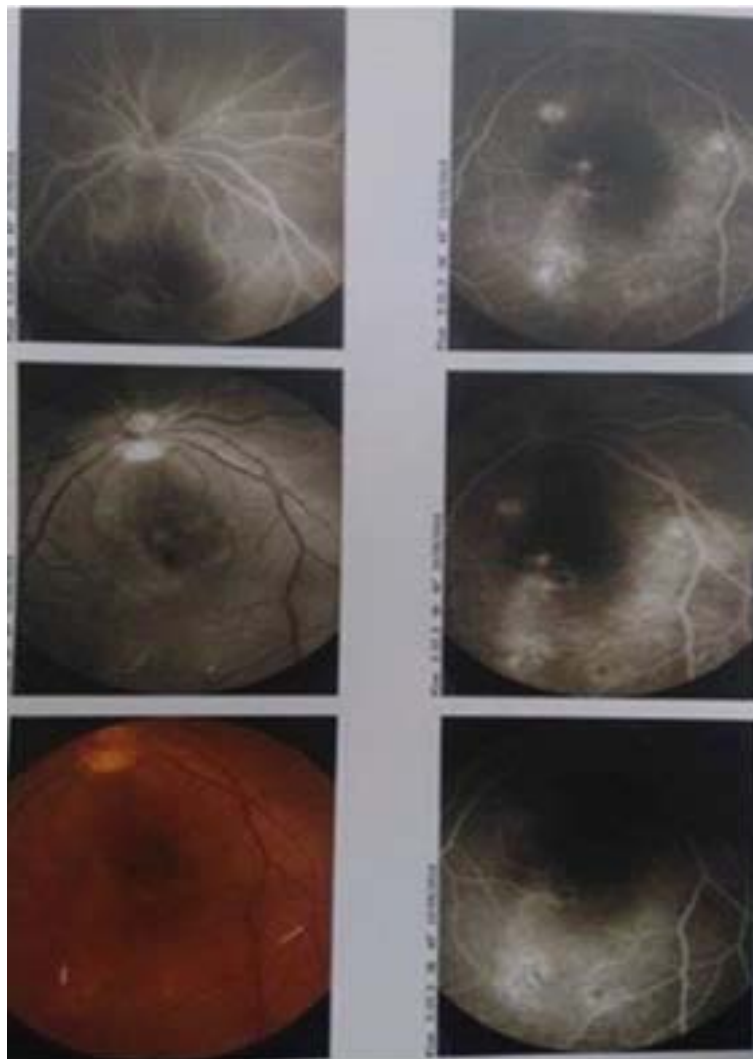


Figure 2: Ophthalmology consultation advised OCT scan of both eyes.

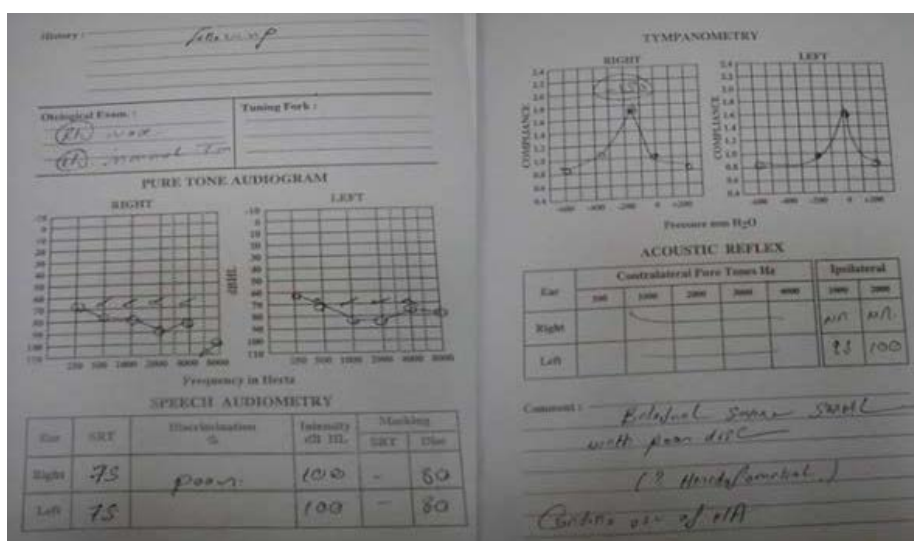


Figure 3: Biological sample of patient.

been described [6], which explains the association of this syndrome with other diseases of immune dysregulation [3,7]. Three cases of concurrent VKH and ulcerative colitis have been reported in the past [8-10]. In one, the ulcerative colitis was quiescent at the time of ocular disease activity. In the other two, patients developed severe flare of their disease, requiring colectomy in one case and treatment with anti-TNF agents in the other as our case. The immunological mechanism may be the cause. Another case was mentioned in literature showing an association of VKH syndrome and Crohn's disease [11].

Neurological manifestations: Ulcerative colitis can affect possibly the Peripheral (PNS), and the Central Nervous System (CNS). Cerebrovascular disease as a consequence of thrombosis and thromboembolism; systemic and cerebral vasculitis; probably immune mediated neuropathy and cerebral demyelination as manifested in our case. Although the mechanisms involved in the pathogenesis of neurologic manifestations of IBD are not clearly discussed in literature, it is probably related to a common altered immune basis, affecting cell-mediated and humoral immunity and inflammatory mechanisms [12]. In addition, infection by microbial agents, namely *Campylobacter jejuni*, is linked to exacerbations of IBD and may contribute to the development of autoimmune inflammatory demyelinating polyneuropathy [13].

Peripheral Neuropathy (PN) is one of the most frequently reported neurological complications in IBD patients [12,14]. It can be presented by paresthesia due to small fiber involvement (autonomic or sensory) and increased threshold for temperature detection (or axonal sensory findings which could be indicative for early PN) are common in patients with IBD who have been treated with metronidazole (21-39%), also in those who have not received this medication (19%) [15]. Axonal neuropathies are more common than demyelinating neuropathies, but still both can respond well to immunomodulatory therapy. The concept that PN manifesting in IBD is probably autoimmune-induced is strongly supported by further reports, describing recovery after initiation of steroid treatment [16]. Our case was presented with demyelinating neuropathy as proved by EMG that affected his gait. Later on it was improved on high dose oral steroid and biological therapy.

Sensory neural hearing loss (SNHL): there is strong association of IBD and especially UC with atypical vestibular system disorders such as dizziness, vertigo, nausea and temporary loss of equilibrium has been described in literature [17,18]. In addition, sensorineural hearing loss, a probable immunologic manifestation of IBD, has been reported [19-22]. The clinical manifestation of the disease is most often bilateral and progressive. The hearing level often fluctuates, with periods of deterioration alternating with partial or even complete remission. The tendency is for the gradual evolution of permanent hearing loss, which usually stabilizes with some remaining auditory function but occasionally proceeds to complete deafness. Vestibular dysfunction, particularly dysequilibrium and postural instability, may accompany the auditory symptoms.

ENT specialists usually recommend steroid or immunosuppressive therapy as in our patient. Evidence for an autoimmune basis for this condition is frequently mentioned and thus the potential benefit of systemic corticosteroids [18]. As there is already activation of the immune system and pro-inflammatory cytokines such as interleukins (IL-1,IL-12) and TNF- α , so immediate treatment with steroids with or without immunosuppressive agents as anti TNF- α is essential, and any delay may lead to irreversible hearing loss [23,24].

Conclusion

To conclude extra intestinal manifestations are very common in both UC and CD patients. Early involvement of specialists in the management of involved organ systems is very crucial. Most of these manifestations are parallel to the disease activity and will respond to treatment of underlying bowel disease.

To the best of our knowledge this is the first case that gathers some of rarest extra intestinal manifestations of UC in one patient including hematological, ocular, neurological and hearing. So, as they say calamities do not usually come alone, but fortunately these manifestations were diagnosed early and our patient received immunosuppressant in the form of steroid and anti-TNF and was clinically much better.

Conflicts of Interest

Conflict of interest disclosed was none.

References

1. Ricart E, Panaccione R, Loftus E, Tremaine WJ, Harmsen WS, et al (2004) Autoimmune disorders and extraintestinal manifestations in first-degree familial and sporadic inflammatory bowel disease: A case-control study. *Inflamm Bowel Dis* 10:207-214.
2. Bernstein C, Blanchard J, Houston D, Wajda A (2001) The incidence of deep venous thrombosis and pulmonary embolism among patients with inflammatory bowel disease: a population-based cohort study. *Thromb Hemost* 85:430-434.
3. Yujuan W, Chi-Chao C (2014) Gender differences in Vogt-Koyanagi-Harada Disease and Sympathetic Ophthalmia. *J Ophthalmol* 157803: 8.
4. Damico F, Bezerra F, Silva G, Gasparin F, Yamamoto JH (2009) New insights into Vogt Koyanagi-Harada disease. *Arq Bras Oftalmol* 72:413-420.
5. Read R, Rao N, Cunningham E (2000) Vogt-Koyanagi-Harada disease. *Curr Opin Ophthalmol* 11:437-442.
6. Sheriff F, Narayanan N, Huttner A, Baehring JM, et al. (2014) Vogt-Koyanagi-Harada syndrome: A novel case and brief review of focal neurologic presentations. *Neurol Neuroimmunol Neuroinflamm* 1: e49.
7. Lavezzo M, Sakata V, Morita C, Rodriguez E, Abdallah SF, et al. (2016) Vogt-Koyanagi-Harada disease: Review of a rare autoimmune disease targeting antigens of melanocytes. *Orphanet J Rare Dis* 11:29.
8. Poza G, Lopez A, Masjuan J, Mata G, Lapena T et al. (2009) Ulcerative colitis associated with Vogt-Koyanagi-Harada disease. *Gastroenterol Hepatol* 32:343-345.
9. Federman D, Kravetz J, Ruser C, Judson PH, Kirsner RS (2004) Vogt-Koyanagi-Harada syndrome and ulcerative colitis. *South Med J* 97:169-171.
10. Iversen T and Sverrisson T (1986) Vogt-Koyanagi-Harada syndrome: A case report. *Acta Ophthalmol (Copenh)* 64:235-238.
11. Souguir A, Hammami A, Dahmeni W, et al (2015). Vogt-Koyanagi-Harada syndrome and Crohn's disease: An exceptional association. *Gastroenterol Rep (Oxf)* 6:65-67.
12. Lossos A, River Y, Eliakim A, Steiner I (1995) Neurologic aspects in inflammatory bowel disease. *Neurology* 45:416-421.
13. Podolsky DK (1991) Inflammatory bowel disease. *N Eng J Med* 325:1008 -1016.
14. Elsehety A, Bertorini T (1997) Neurologic and neuropsychiatric complications of Crohn's disease. *South Med J* 90: 606-610.
15. Stahlberg D, Bárány F, Einarsson K, Ursing B, Elmqvist D, et al. (1991) Neurophysiologic studies of patients with Crohn's disease on long-term treatment with metronidazole. *Scand J Gastroenterol* 26:219-224.
16. Yesilova Z, Naharci I, Uygun A, Ulaş HU, Dağalp K (2006) Motor axonal polyneuropathy in the course of ulcerative colitis: A case report. *Turk J Gastroenterol* 17:58-61.
17. Scheid R, Teich N (2007) Neurologic manifestations of ulcerative colitis. *Eur J Neurol* 14:483-493.
18. Mymoona A, Ayaz R, Showkat K, Sajad H, Qazi N, et al (2015) A clinical study on association between hearing loss and inflammatory bowel disease in a population attending a hospital. *Int J Res Med Sci* 3:630-634.

-
19. Kuczkowski J, Kozlowski J, Narozny W (2006) Acute autoimmune sensorineural hearing loss in pregnant women with Lesniowski-Crohn disease. *Otolaryngol Pol* 60:583-585.
 20. Akbayir N, Calis A, Alkim C, Sökmen HM, Erdem L, et al. (2005) Sensorineural hearing loss in patients with inflammatory bowel disease: A subclinical extraintestinal manifestation. *Dig Dis Sci* 50:1938-1945.
 21. Kumar B, Walsh R, Wilson P, Carlin WV (1997) Sensorineural hearing loss and ulcerative colitis. *J Laryngol Otol* 111:277-278.
 22. Herdman R, Hirari M, Ramsden R (1991) Autoimmune inner ear disease and ulcerative colitis. *J Laryngol Otol* 105:330-331.
 23. Orchard T, Jewel D (2004) Extraintestinal manifestations: skin, joints and mucocutaneous manifestations. *Inflammatory Bowel Disease*. 6th edition. Philadelphia: Saunders; 658-672.
 24. Jonathan SL, Robert Burakoff (2011) Extraintestinal Manifestations of Inflammatory Bowel Disease. *Gastroenterol Hepatol (NY)* 7: 235-241.