

Prostate Volume in Patients Undergoing Primary Surgical or Radiotherapeutic Management of Localized Adenocarcinoma: Implications for Design of Minimally Invasive Imaging and Treatment Devices for the Prostate

Davis BJ^{1*}, Leenstra JL¹, Wilson TM², Mynderse LA², Solhjem MC³, Herman MG¹, Hillman DW¹, Allen-Ziegler KL⁴, Chevillie JC⁵, King BF⁶ and Holmes III DR⁷

¹Department of Radiation Oncology (J.L.L., B.J.D., M.C.S., M.G.H.), Mayo Clinic, Rochester, Minnesota, USA

²Department of Urology (T.M.W., L.A.M.), Mayo Clinic, Rochester, Minnesota, USA

³Department of Radiation Oncology, The Oregon Clinic, Portland, Oregon, USA

⁴Division of Biomedical Informatics and Biostatistics (D.W.H., K.L.A.-Z), Mayo Clinic, Rochester, Minnesota, USA

⁵Department of Laboratory Medicine and Pathology (J.C.C.), Mayo Clinic, Rochester, Minnesota, USA

⁶Department of Radiology (B.F.K.), Mayo Clinic, Rochester, Minnesota, USA

⁷Department of Physiology and Biomedical Engineering (D.R.H.), Mayo Clinic, Rochester, Minnesota, USA

Abstract

Introduction: The objective of this study was to collect and analyze prostate volumetric data from different patient cohorts treated for localized prostate cancer. These data were examined with respect to the design of minimally invasive treatment devices for localized prostate cancer.

Methods: Among 700 patients with prostate cancer (stages T1a-T3c), 342 had radical retropubic prostatectomy (RRP) specimens submitted for whole mounting; 308 received permanent prostate brachytherapy and underwent transrectal ultrasonography (TRUS); and 50 received external beam radiotherapy with computed tomographic (CT)-based 3-dimensional treatment planning. Analysis included cumulative histograms, descriptive statistics, and statistical comparisons of median height, width, length, and volume.

Results: Median prostate dimensions (in millimeters) and volumes (in cubic centimeters) were as follows: Height by RRP was 30; TRUS prostate, 33; TRUS planimetry, 35; and CT, 42. Width by RRP was 47; TRUS prostate, 50; TRUS planimetry, 51; and CT, 51. Length by RRP was 42; TRUS prostate, 49; TRUS planimetry, 45; and CT, 41. Volume by RRP was 32; TRUS prostate, 41; TRUS planimetry, 43; and CT, 45.

Conclusions: Although median TRUS and CT volumes were similar (41-45 cm³), median RRP volume was 9 to 13 cm³ less. Of the cases examined, 75% would be encompassed by an imaging device with an azimuthal field of view of 48 to 55 mm and 95% by a device with a length of 54 to 63 mm.

Keywords: Brachytherapy; Computed Tomography; Prostate Cancer; Ultrasound; Volume

Abbreviations: CI: Confidence Interval; CT: Computed Tomography; EBRT: External Beam Radiotherapy; PPB: Permanent Prostate Brachytherapy; RRP: Radical Retropubic Prostatectomy; SD: Standard Deviation; TRUS: Transrectal Ultrasonography; TURP: Transurethral Resection Of The Prostate

Introduction

Prostate cancer is the most commonly diagnosed noncutaneous malignancy of American men [1]. Accurate assessment of prostatic dimensions and volume is necessary for effective management of prostate cancer. Both transrectal ultrasonography (TRUS) and computed tomography (CT) allow for in vivo measurement of the prostate that is reasonably accurate and reproducible [2-7]. TRUS is used to measure prostate volume at the time of diagnostic biopsy for treatment planning and for intraoperative visualization during minimally invasive therapies, including permanent prostate brachytherapy (PPB) and cryotherapy. Prostate volume is an important determinant of the need for neoadjuvant cytoreductive androgen ablation and is helpful in the selection of a treatment modality, with a gland size of 60 cm³ being a common upper limit for PPB [8,9]. CT is used in the planning and delivery of external beam radiotherapy (EBRT) and is the current standard for postimplant evaluation and dosimetry after PPB [10]. Acquisition of accurate prostate volume and dimensions is important for the success of PPB and EBRT.

Technologic advancements in prostate imaging and treatment have paralleled one another, especially with respect to radiotherapy [11]. As imaging modalities have improved in their representation of the in vivo prostate, the accuracy of treatment planning volumes has improved, resulting in sparing of normal tissue and improved clinical outcomes [12]. Dimensional data are needed to aid the development of new imaging and treatment devices and modalities. In the present study, we sought to retrospectively compile dimensional and volumetric data from surgical specimens, TRUS measurements, and CT measurements in patients with untreated prostate cancer from 3 non-overlapping cohorts. The goal was to collect geometric data for designing imaging and treatment devices related to prostate cancer therapy, such as

***Corresponding author:** Davis BJ, Department of Radiation Oncology (J.L.L., B.J.D., M.C.S., M.G.H.), Mayo Clinic, Rochester, Minnesota, USA, Tel: 507-284-2511; E-mail: davis.brian@mayo.edu

Received May 01, 2014; Accepted May 2, 2014; Published June 06, 2014

Citation: Davis BJ, Leenstra JL, Wilson TM, Mynderse LA, Solhjem MC, et al. (2014) Prostate Volume in Patients Undergoing Primary Surgical or Radiotherapeutic Management of Localized Adenocarcinoma: Implications for Design of Minimally Invasive Imaging and Treatment Devices for the Prostate. OMICS J Radiol S1: 001. doi:10.4172/2167-7964.S1-001

Copyright: © 2014 Davis BJ, et al. This is an open-access article distributed under the terms of the Creative Commons Attribution License, which permits unrestricted use, distribution, and reproduction in any medium, provided the original author and source are credited.

transurethral ultrasound probes [13], cryotherapy probes, or related novel brachytherapy seeds or instruments.

Methods and Materials

Patients

This study included pathologic and imaging data from 700 patients with localized prostate cancer in clinical stages T1a through T3c. Maximal prostate height (anteroposterior diameter), width (transverse diameter), and length (longitudinal or axial diameter or superior-inferior or sagittal diameter) were measured using 3 modalities in 3 separate cohorts of patients: 1) direct measurement of gross specimens from a Mayo Clinic whole-mount prostatectomy series, 2) TRUS before PPB, and 3) CT for EBRT planning. Clinical data included age, pretreatment serum prostate-specific antigen concentrations by Hybritech Tandem-R (Hybritech, Inc, San Diego, California) or Abbott IMx (Abbott Laboratories, Abbott Park, Illinois) assays, diagnostic biopsy Gleason score, and clinical tumor stage. In each cohort, data were excluded from analysis if patients had undergone any previous treatment with transurethral resection of the prostate (TURP), androgen ablation, or radiotherapy.

Radical retropubic prostatectomy

Between September 1991 and June 1993, 416 consecutive radical retropubic prostatectomy (RRP) specimens from 3 urologic surgeons were submitted for total embedding and whole mounting. Seventy-four patients were excluded owing to previous treatment or lack of dimensional recording on the original pathology report, leaving 342 patients for evaluation. The Mayo Clinic routine partial sampling protocol for preparing and reporting serially sectioned whole-mount prostates has been previously described [14]. In brief, each prostate was weighed, measured with calipers in 3 dimensions, inked, and fixed (1-3 days) in 10% neutral buffered formalin. These measurements were used in the following formula for the volume of an ellipsoid:

$$\text{Volume}=(\pi/6)\times(\text{Height}\times\text{Width}\times\text{Length})$$

This formula is also known as the *prolate ellipsoid formula* [3]. No shrinkage factor was necessary for prostate volume determination since these measurements were of fresh specimens.

Transrectal ultrasonography

Between April 1998 and December 2004, 407 consecutive patients underwent TRUS before PPB. After exclusion of 99 patients who had prior treatment with TURP or androgen deprivation, 308 patients remained for evaluation. All TRUS examinations were performed with a model 1846 ultrasound scanner (Bruel and Kjaer, Marlborough, Massachusetts) with a 7-MHz multiplane probe (type 8551). One of 6 experienced ultrasonographers contoured the circumference of the prostate gland as it appeared on each TRUS axial image at 5-mm increments with a TRUS probe holder, stepper, and stabilization device (Barzell-Whitmore, Sarasota, Florida). The maximal height and width were recorded, and the axial length was determined by the number of stepped sections measured. Planimetry volume was then determined with an automated, conventional method in which volume is calculated as the sum of the individual cross-sectional areas multiplied by the interslice distance [2,15,16]. The prolate volume was also calculated separately (with the prolate ellipsoid formula) for comparison after the probe was removed from the step-section device. Maximal width and height were again measured and recorded along with maximal length as it was measured from the bladder neck to the apex of the prostate in the midline sagittal plane.

Computed tomography

A total of 169 consecutive patients with localized prostate adenocarcinoma were treated with EBRT from July 2000 to April 2004. Sixty-five patients were excluded because of previous treatment. Implantation of gold seed markers before radiotherapy began at our institution in December 2002. These markers were used in most (but not all) patients treated with EBRT from that time on. Hence, an additional 54 patients were excluded because of marker implantation, which may cause temporary prostate edema, leaving 50 patients for evaluation. Before treatment, axial CT images of the pelvis and prostate were obtained at 3 mm intervals with the patient in the supine position. No contrast material was used for these simulation scans. The same treating radiation oncologist (B.J.D.) outlined the margins of the prostate gland for each CT image using an AcQSIM work station, version 4.2 (Koninklijke Philips Electronics, Amsterdam, Netherlands). The statistics function of the work station was used to determine the maximal organ dimensions for height, width, and length and to determine prostate volume. The program calculates the area of each contoured slice, multiplies it by 3 mm to calculate the volume of each slice, and then totals all slice volumes to estimate the total volume.

Statistical analysis

Wilcoxon rank sum tests were used for all pairwise comparisons of continuous factors [17]. The Kruskal-Wallis rank sum test was used for 3 group comparisons. All categorical variables were assessed with χ^2 tests. The Wilcoxon signed rank test was used to determine whether the difference in the patient's TRUS prolate and TRUS planimetry measurements was zero. A *P* value of 0.05 or less was considered significant; all *P* values were 2-sided. All analyses were performed with SAS statistical software, version 8.2 (SAS Institute Inc, Cary, North Carolina).

Results

Characteristics of the study cohorts are summarized in Table 1. Prostate dimensions and volumes are summarized in Table 2. Figure 1A shows the cumulative frequency of height measurements across all cohorts with use of planimetry data for the TRUS measurements.

Variable	Prostatectomy (n=342)	TRUS (PPB) (n=308)	CT Scan (EBRT) (n=50)
Age, median (range), y	65 (45-78)	69 (42-84)	72 (58-85)
Clinical stage			
T1a, T1b, or T1c	71 (21)	225 (73)	33 (66)
T2a, T2a/b, T2b, or T2c	211 (62)	83 (27)	14 (28)
T3a, T3a/b, T3b, or T3c	60 (18)	0 (0)	3 (6)
Gleason score			
2-4	11 (3)	0 (0)	0 (0)
5	99 (29)	17 (6)	0 (0)
6	20 (6)	247 (80)	29 (58)
7	192 (56)	43 (14)	14 (28)
8-10	20 (6)	1 (1)	7 (14)
Pretreatment PSA, $\mu\text{g/L}$			
<4	52 (15)	73 (24)	9 (18)
4.1-10	143 (42)	198 (64)	26 (52)
10.1-20	94 (27)	35 (11)	12 (24)
>20	53 (16)	2 (1)	3 (6)

Abbreviations: CT, computed tomography; EBRT, external beam radiotherapy; PPB, permanent prostate brachytherapy; PSA, prostate-specific antigen; TRUS, transrectal ultrasonography.

^aCategorical data are expressed as number of patients and percentage of cohort.

Table 1: Study Group Characteristics^a.

Average prostate height (\pm standard deviation [SD]) across all cohorts was 35 ± 7 mm (95% confidence interval [CI], 34-35 mm). Statistically significant differences ($P < 0.001$) were evident when height was compared across all modalities of measurement. Median height in the CT scan cohort (42 mm) was greater overall; median height by RRP and TRUS ranged from 30 to 35 mm.

Figure 1B shows the cumulative frequency of width measurements across the 3 cohorts. Average prostate width (\pm SD) was 49 ± 7 mm (95% CI, 49-50 mm) in the combined series. Widths were similar between the TRUS and CT cohorts ($P = 0.99$ for planimetry vs. CT; $P = 0.66$ for the prolate method vs. CT); however, the TRUS and the CT

widths were different from the RRP widths ($P < 0.001$). This is evident when the median prostate width by RRP (47 mm) is compared with the median prostate widths by TRUS prolate (50 mm), TRUS planimetry (51 mm), and CT (51 mm).

Figure 1C shows the cumulative frequency of length measurements across the 3 cohorts. Average prostate length (\pm SD) for all groups was 46 ± 9 mm (95% CI, 45-47 mm). Median lengths for the CT cohort (41 mm) and the RRP cohort (42 mm) were similar ($P = 0.10$), but they differed significantly ($P < 0.001$) from the lengths for the TRUS cohorts (prolate, 49 mm; planimetry, 45 mm).

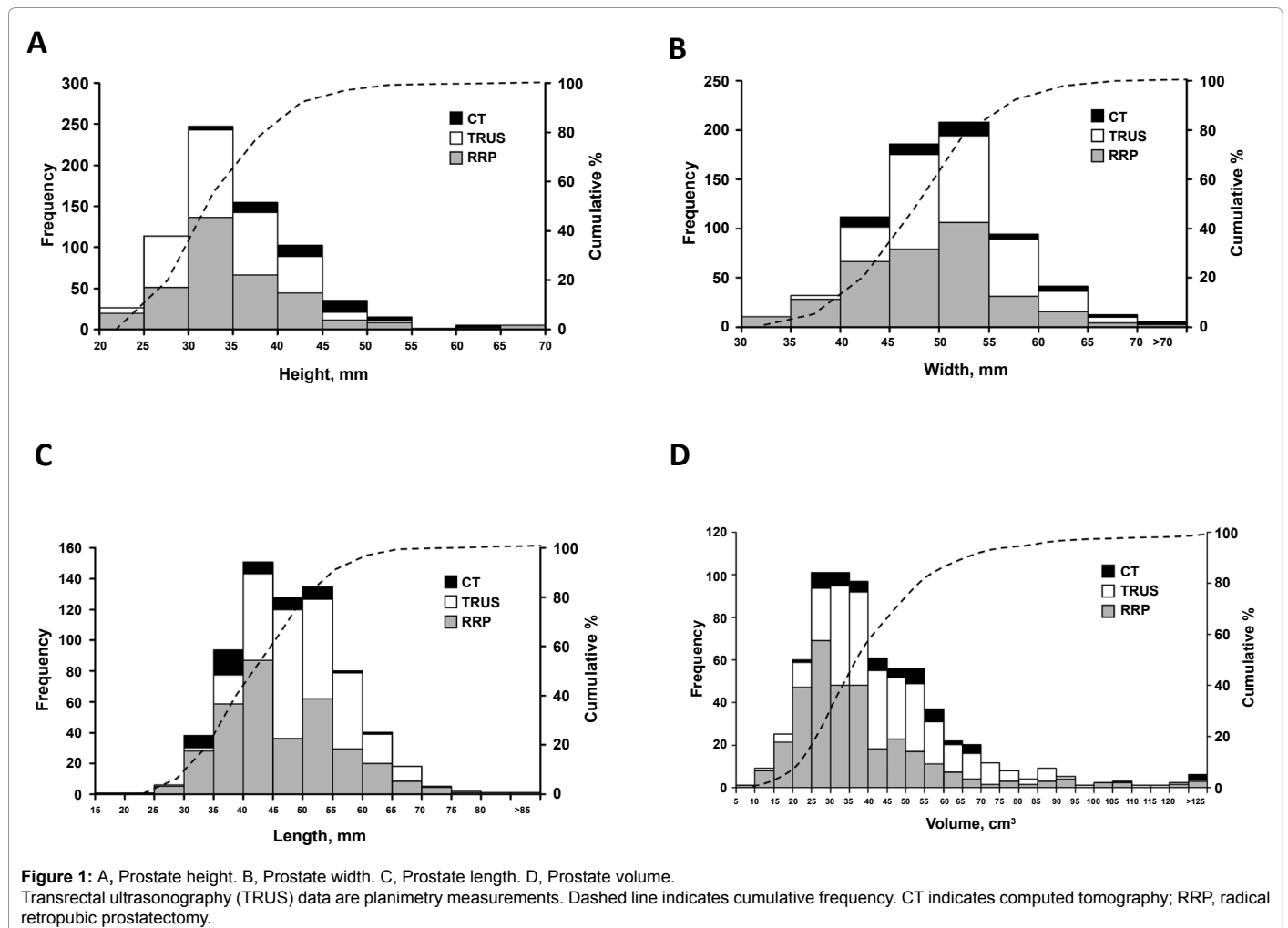
Figure 1D represents the cumulative frequency of prostate volumes for all cohorts. Average volume (\pm SD) across all cohorts was 43 ± 22 cm³ (95% CI, 41-44 cm³). Median volumes were similar between the CT cohort (45 cm³) and the TRUS cohorts (prolate, 41 cm³; planimetry, 43 cm³) ($P = 0.63$ for planimetry vs. CT; $P = 0.34$ for prolate vs. CT), but the TRUS and CT volumes differed ($P < 0.001$) from the RRP volume (32 cm³).

A comparison of TRUS prolate and TRUS planimetry measurements showed that, on average, the prolate method underestimated prostate height by 2 mm (6%), width by 1 mm (1%), and volume by 1 cm³ (2%) ($P < 0.001$ for each comparison). Length was on average 1 mm (3%) more by the prolate method ($P = 0.032$).

Method	Prostate Dimension, Median (5 th , 95 th Percentiles) Mean \pm Standard Deviation			
	Height, mm	Width, mm	Length, mm	Volume, cm ³
Prostatectomy	30 (24, 45)	47 (35, 60)	42 (30, 63)	32 (18, 77)
	32 \pm 6	46 \pm 7	46 \pm 11	37 \pm 17
TRUS prolate	33 (25, 44)	50 (42, 61)	49 (39, 60)	41 (24, 79)
	34 \pm 6	51 \pm 6	48 \pm 7	45 \pm 17
TRUS planimetry	35 (27, 46)	51 (42, 61)	45 (35, 60)	43 (24, 80)
	36 \pm 6	51 \pm 6	48 \pm 8	46 \pm 18
CT	42 (34, 52)	51 (41, 67)	41 (30, 54)	45 (25, 70)
	44 \pm 8	52 \pm 8	43 \pm 9	50 \pm 24

Abbreviations: CT, computed tomography; TRUS, transrectal ultrasonography.

Table 2: Prostate Dimensions as Measured by 4 Methods.



Study	Di-sease		n	Mean			Length, mm		Volume, cm ³		Weight
	Method			Age, y	Height, mm	Width, mm	Sagittal ^a	Axial	Prolate	Planimetry	
Present study ^b	Ca	RRP	342	64 (45-78)	33 ± 7 (20-65)	47 ± 7 (30-85)	45 ± 10 (15-100)	NA	38 ± 24 (9-289)	NA	53 ± 24 (21-250)
	Ca	TRUS ^c	308	68 (42-84)	36 ± 6 (22-57)	51 ± 6 (37-70)	48 ± 6 (33-69)	48 ± 8 (25-75)	45 ± 17 (17-120)	47 ± 18 (15-138)	NA
	Ca	CT	50	71 (58-85)	43 ± 7 (32-65)	52 ± 8 (40-72)	NA	42 ± 7 (30-60)	NA	49 ± 23 (24-143)	NA
Terris and Stamey [3] ^d	Ca	TRUS	150	65 (31-79)	30 (13-66)	47 (18-72)	34 (20-56)	40 (30-72)	NA	NA	45 (14-149)
Yip et al. [4] ^e	None	Cadaver	55	64 (19-89)	25 ± 4 (17-34)	32 ± 5 (22-43)	44 ± 4 (34-50)	NA	NA	NA	NA
Collins et al. [5]	BPH	TRUS	181	NA (40-79)	28 ± 6	48 ± 5	42 ± 5	NA	30 ± 13	NA	NA
Nathan et al. [18]	BPH	TRUS	45	72 (43-89)	30 ± 8	50 ± 7	38 ± 8	44 ± 10	29 ± 17	35 ± 18 (8-75)	NA
Present study	Ca	RRP	342	64 (45-78)	30 (20-65)	47 (30-85)	42 (15-100)	NA	32 (9-289)	NA	45 (21-250)
	Ca	TRUS ^c	308	68 (42-84)	35 (22-57)	51 (37-70)	49 (33-69)	45 (25-75)	41 (17-120)	43 (15-138)	NA
	Ca	CT	50	71 (58-85)	42 (32-65)	51 (40-72)	NA	41 (30-60)	NA	45 (24-143)	NA
Roehrborn et al. [25]	BPH	TRUS	100f	62 (50-75)	32 (19-52)	50 (29-71)	46 (32-69)	NA	39 (14-130)	NA	NA
	BPH	TRUS	1,222g	66 (47-81)	42 (19-77)	34 (15-83)	47 (14-87)	NA	33 (4-228)	NA	NA
	BPH	TRUS	480h	61 (40-79)	28 (18-51)	48 (37-69)	42 (29-65)	NA	29 (14-95)	NA	NA
	BPH	TRUS	397i	54 (40-79)	28 (15-57)	49 (35-78)	38 (25-72)	NA	26 (12-120)	NA	NA

Abbreviations: BPH, benign prostatic hyperplasia; Ca, prostate cancer; CT, computed tomography; NA, data not available; RRP, radical retropubic prostatectomy; SD, standard deviation; TRUS, transrectal ultrasound.

^aThis length is a longitudinal measurement from the bladder neck to the apex in a midline sagittal view with TRUS.

^bMeasurement of fresh specimens.

^cTRUS dimensional data were reported from planimetry measurements.

^dAll patients had TRUS and then RRP; RRP dimensional data were not reported.

^eMeasurement after fixation.

^fCohort data from University of Texas Southwestern.

^gCohort data from Veterans Affairs Cooperative Study #359.

^hCohort data from Stirling, Scotland.

ⁱCohort data from Olmsted County, Minnesota.

Table 3: Comparison of Prostate Dimensions, Volume, and Weight in Select Studies.

Discussion

Our study evaluated 700 patients who had localized prostate cancer. We performed detailed dimensional and volume measurements by direct RRP specimen observation, TRUS imaging, and CT in 3 separate non-overlapping cohorts. Even though the methods of measurement were different in each cohort and the RRP cohort was from a different time period than patients who underwent PPB or EBRT, width and volume measurements were similar in the TRUS and CT scan groups and length measurements were similar in the CT scan and RRP groups. Although certain observations on volumes and dimensions are possible, our study design was not intended to make exact comparisons between imaging modalities because the methods of data collection were different for each cohort. Rather, the goal of our study was to provide extensive data for prostate dimensions from common means of measurement. The data gathered and analyzed in this study represent a large series of patients treated by common techniques at one institution. Thus, the data provide useful information on prostate dimensions from customary measurement modalities and are intended to include a spectrum of prostate dimensions observed in patients presenting with localized prostate cancer.

Several studies have found that prostate length is the most difficult dimension to measure owing to poor visualization of the juncture between the prostatic apex and distal urethra and to poor definition between the base of the prostate, the seminal vesicles, and the bladder neck [3,15]. In a study of inter observer variability by Collins et al. [5], 5 experienced ultrasonographers and 4 urologists marked the dimensions for measurement on static TRUS images from 6 patients. The length measurement was the most inconsistent owing to different interpretations of the locations of the bladder neck and apex [5].

Yip et al. [4] measured 61 explanted prostates with TRUS and calipers and demonstrated that the TRUS prolate method underestimated all dimensions, with the largest errors in length

($r=0.76$) and the next largest in width ($r=0.81$) and height ($r=0.82$). Terris and Stamey [3] compared in vivo TRUS measurements in 150 patients with subsequent caliper measurements after RRP; correlation coefficients were 0.37 for prolate length, 0.47 for axial length, 0.78 for width, and 0.79 for height. Those results were consistent with results from a study by Nathan et al. [18] that compared TRUS planimetry with TRUS prolate measurements in 45 subjects. They found that the prolate method underestimated length by 13%, width by 6% and height by 2%. In contrast, our data comparing TRUS prolate with planimetry showed that the prolate method underestimated height by 6% and width by 1%; the prolate method overestimated length by 3% compared with the axial length. The discrepancy between our data and data from other studies underscores the difficulty in establishing an accurate length by TRUS.

The prolate ellipsoid method of prostate volume determination is widely accepted and may be performed quickly; however, it is imprecise. Matthews et al. [6] compared ellipsoid volumes calculated from TRUS measurements with those from subsequent RRP specimens from 100 men. For the entire cohort, they found that TRUS underestimated volume (mean, 36 ± 17 cm³) compared with RRP (mean, 45 ± 23 cm³). Showing a volume-dependent relationship, TRUS overestimated volume in prostates smaller than 30 cm³ and increasingly underestimated volume in prostates larger than 30 cm³, with the greatest underestimation in prostates larger than 50 cm³. Similar studies comparing TRUS prolate volumes with RRP volumes found that the TRUS prolate method underestimates prostate volume by 23% to 30% [3,19]. Rahmouni et al. [20] noted that the 3 axis linear method of prostate volume determination is intrinsically imprecise because the prostate is not perfectly ellipsoid. Other sources of error include the operator-dependent orientation of the ultrasound transducer in relation to the prostate and pressure-related deformation of the gland by the transducer.

Serial planimetry is considered the most accurate TRUS volume technique because it allows for variations in the external prostate contour from the apex to the base in 5 mm increments or less [2]. In a study comparing preprostatectomy TRUS measurements with RRP specimens in the same cohort of 150 patients, Terris and Stamey [3] found that volume by step section planimetry had a correlation coefficient of 0.93 compared with 0.90 for prolate volume measurements. Measurements by TRUS planimetry are also more reproducible than those obtained by the prolate method. Chenven et al. [21] compared planimetric volumes with prolate ellipsoid volumes in 43 patients at preplanning and again before brachytherapy and found a correlation coefficient of 0.92 for the planimetric method compared with 0.58 for the ellipsoid method ($P < 0.001$). McMahaon et al. [22] compared prostate volumes in 136 patients undergoing brachytherapy and determined that a bullet shape (length · height · width · $[\pi/4.8]$) was determined to best represent the majority of prostate glands using planimetry volumes as the standard. Aarnink et al. [15] compared planimetric volumes taken from 2 sequential TRUS examinations in 30 patients. Mean volume was $47 \pm 28 \text{ cm}^3$ at the first session and $48 \pm 31 \text{ cm}^3$ at the second, with a correlation coefficient of 0.98 and no significant difference between the 2 measurements.

In the present study, width and volume measurements were similar in the CT and TRUS cohorts. Close agreement ($r=0.9$) was also found between volumes with these imaging modalities in a study of 10 patients who had TRUS and CT before PPB by Badiozamani et al. [7]. However, Hoffelt et al. [23] compared CT and TRUS prolate volume in 48 patients, and CT images of the prostate overestimated the prostate volume by 50%. Narayana et al. [24] performed a similar study of 10 patients; CT volumes were 47% larger and 6 mm longer than step-section planimetry TRUS measurements. No studies comparing CT measurements with prostatectomy specimens from the same cohort have been reported. Difficulty in clearly distinguishing prostate limits is common to both TRUS and CT imaging. Care is needed in interpreting CT scans to exclude the puborectalis muscle and anterior venous plexus [7] and to differentiate the base of the prostate from the bladder wall [23] and the prostate apex from the penile bulb [24,25].

Data on prostate dimensions and volume from all measurement modalities are limited. Table 3 provides data from the present study and others [3-5,18,26]. These data are useful in considering the design of devices for imaging the prostate and for devices related to minimally invasive prostate therapies. For example, these data are helpful when considering the design of a new prostate brachytherapy seed having a length greater than that typically used [27]. A 60 mm seed length would include the maximal prostate length recorded in more than 95% of the prostates in our series, a 65 mm length would include 97%, and a 70 mm length would include 99%. Similar considerations are evident in the design of the active ablative region of needles used in cryotherapy or other ablative procedures. Also, these data are applicable to the design of TRUS or transurethral ultrasound probes with respect to depth of penetration and active imaging area.

Acknowledgments

We thank Wayne N. LaJoie, BS, CMD, and Marc A. Hadaway, RDMS, for their assistance in collection of the ultrasonographic data and Nancy K. Berge for her assistance in collection of the computed tomographic data.

References

1. Siegel R, Ma J, Zou Z, Jemal A (2014) Cancer statistics, 2014. *CA Cancer J Clin* 64: 9-29.
2. Littrup PJ, Williams CR, Eggin TK, Kane RA (1991) Determination of prostate volume with transrectal US for cancer screening. Part II. Accuracy of in vitro and in vivo techniques. *Radiology* 179: 49-53.
3. Terris MK, Stamey TA (1991) Determination of prostate volume by transrectal ultrasound. *J Urol* 145: 984-987.
4. Yip YL, Chan CW, Li CK, Chu V, Lau ML (1991) Quantitative analysis of the accuracy of linear array transrectal ultrasound in measurement of the prostate. *Br J Urol* 67: 79-82.
5. Collins GN1, Raab GM, Hehir M, King B, Garraway WM (1995) Reproducibility and observer variability of transrectal ultrasound measurements of prostatic volume. *Ultrasound Med Biol* 21: 1101-1105.
6. Matthews GJ, Motta J, Fracehia JA (1996) The accuracy of transrectal ultrasound prostate volume estimation: clinical correlations. *J Clin Ultrasound* 24: 501-505.
7. Badiozamani KR, Wallner K, Cavanagh W, Blasko J (1999) Comparability of CT-based and TRUS-based prostate volumes. *Int J Radiat Oncol Biol Phys* 43: 375-378.
8. Prestidge BR, Prete JJ, Buchholz TA, Friedland JL, Stock RG, et al. (1998) A survey of current clinical practice of permanent prostate brachytherapy in the United States. *Int J Radiat Oncol Biol Phys* 40: 461-465.
9. Nag S, Beyer D, Friedland J, Grimm P, Nath R (1999) American Brachytherapy Society (ABS) recommendations for transperineal permanent brachytherapy of prostate cancer. *Int J Radiat Oncol Biol Phys* 44: 789-799.
10. Davis BJ, Horwitz EM, Lee WR, Crook JM, Stock RG, Merrick GS, et al; American Brachytherapy Society. American Brachytherapy Society consensus guidelines for transrectal ultrasound-guided permanent prostate brachytherapy. *Brachytherapy*. 2012 Jan-Feb;11(1):6-19.
11. Speight JL, Roach M 3rd (2000) Imaging and radiotherapy of the prostate. *Radiol Clin North Am* 38: 159-177, ix.
12. Zelefsky MJ, Fuks Z, Hunt M, Lee HJ, Lombardi D, et al. (2001) High dose radiation delivered by intensity modulated conformal radiotherapy improves the outcome of localized prostate cancer. *J Urol* 166: 876-881.
13. Holmes DR 3rd1, Davis BJ, Bruce CJ, Robb RA (2003) 3D visualization, analysis, and treatment of the prostate using trans-urethral ultrasound. *Comput Med Imaging Graph* 27: 339-349.
14. Bostwick DG, Myers RP, Oesterling JE (1994) Staging of prostate cancer. *Semin Surg Oncol* 10: 60-72.
15. Aarnink RG1, De La Rosette JJ, Debruyne FM, Wijkstra H (1996) Reproducibility of prostate volume measurements from transrectal ultrasonography by an automated and a manual technique. *Br J Urol* 78: 219-223.
16. Tong S, Downey DB, Cardinal HN, Fenster A (1996) A three-dimensional ultrasound prostate imaging system. *Ultrasound Med Biol* 22: 735-746.
17. Wilcoxon F. Individual comparisons by ranking methods. *Biometrics Bull*. 1945;1(6):80-3.
18. Nathan MS, Seenivasagam K, Mei Q, Wickham JE, Miller RA (1996) Transrectal ultrasonography: why are estimates of prostate volume and dimension so inaccurate? *Br J Urol* 77: 401-407.
19. Myschetzky PS, Suburu RE, Kelly BS Jr, Wilson ML, Chen SC, et al. (1991) Determination of prostate gland volume by transrectal ultrasound: correlation with radical prostatectomy specimens. *Scand J Urol Nephrol Suppl* 137: 107-111.
20. Rahmouni A, Yang A, Tempany CM, Frenkel T, Epstein J, et al. (1992) Accuracy of in-vivo assessment of prostatic volume by MRI and transrectal ultrasonography. *J Comput Assist Tomogr* 16: 935-940.
21. Chenven ES, Glazier DB, Krisk EB, Diamond SM, Marmar JL (2001) Evaluation of prostate volume by transrectal ultrasonography for use in a brachytherapy program. *Urology* 58: 752-755.
22. MacMahon PJ, Kennedy AM, Murphy DT, Maher M, McNicholas MM (2009) Modified prostate volume algorithm improves transrectal US volume estimation in men presenting for prostate brachytherapy. *Radiology* 250: 273-280.
23. Hoffelt SC, Marshall LM, Garzotto M, Hung A, Holland J, et al. (2003) A comparison of CT scan to transrectal ultrasound-measured prostate volume in untreated prostate cancer. *Int J Radiat Oncol Biol Phys* 57: 29-32.
24. Narayana V, Roberson PL, Pu AT, Sandler H, Winfield RH, et al. (1997) Impact of differences in ultrasound and computed tomography volumes on treatment planning of permanent prostate implants. *Int J Radiat Oncol Biol Phys* 37: 1181-1185.

-
25. Berthelet E, Liu MC, Agranovich A, Patterson K, Currie T (2002) Computed tomography determination of prostate volume and maximum dimensions: a study of interobserver variability. *Radiother Oncol* 63: 37-40.
26. Roehrborn CG, Girman CJ, Rhodes T, Hanson KA, Collins GN, et al. (1997) Correlation between prostate size estimated by digital rectal examination and measured by transrectal ultrasound. *Urology* 49: 548-557.
27. Meigooni AS, Zhang H, Clark JR, Rachabattthula V, Koona RA (2004) Dosimetric characteristics of the new RadioCoil 103Pd wire line source for use in permanent brachytherapy implants. *Med Phys* 31: 3095-3105.

This article was originally published in a special issue, **Image-Guided Radiotherapy** handled by Editor. Dr. Charles Kunos, University Hospitals Seidman Cancer Center, Case Western Reserve University, Ohio, USA