

So-Called Idiopathic Scoliosis: Diagnostic Tests: Examples of Children Incorrect Treated: New Therapy by Stretching Exercises and Results

Jacek Karski¹ and Tomasz Karski^{2*}

¹Paediatric Orthopaedic and Rehabilitation Department of Medical University in Lublin, Poland

²Former Head of Paediatric Orthopaedics and Rehabilitation Department of Medical University in Lublin, Poland

Abstract

In first article the author (T. Karski) described the biomechanical causes of development of the so-called idiopathic scoliosis. In this article is given basic information for new screening for scoliosis, and for new proper conservative therapy. We are given also examples of "wrong, incorrect therapy in the past". The article underlined necessity of causal prophylaxis.

Keywords: So-called idiopathic scoliosis; Incorrect extension exercises; New stretching exercises

Introduction

However we are speaking for 18 years about new, very effective stretching exercises in scoliosis, in literature mostly are given articles about surgery [1-7].

New therapy by exercises is based on "biomechanical aetiology" of the so-called idiopathic scoliosis. Our research over years 1985-2012 shows exactly, that the causes of the aetiology of scoliosis is not weakness of muscles but the shortening of soft tissue in the region of right hip influences "gait" and "standing at ease". This "shortening" of tendons, fascias, muscles has a pathological influence in the period of growth of the child. The changes cause that "the physiological growth" of the pelvis and the spine develops into "the pathological roles" resulting-so-called idiopathic scoliosis. The children endangered with scoliosis need not strengthen, or extensions exercises but they should stretching exercises to cure the "shortened tissues" of the right hip and of the whole spine, especially in the concave side of the curves. The origin of the "shortenings" and even of the "contracture"-which need very early therapy-comes from the "Seven Contracture Syndrome" [8-19]. In this "Seven Contracture Syndrome" there are many "deformities", and "disturbed functions of joints" sometimes distant from the spine which is presented below.

Material-The Study of Children With So-Called Idiopathic Scoliosis

The complete material consisted in 2012 of a large group of children and adults with scoliosis (N=1950). There patients were divided in two groups: 1/the patients not treated primarily, it means before the first examination by orthopaedic surgeons (both authors)-ca. 30 %, 2/the patients treated by old, harmful exercises-ca. 70 % of patients.

New Tests for Scoliosis

In the diagnosis of scoliosis we should use widely known old tests (Adams & Meyer test), symmetry or asymmetry of waist, but also new tests like-"side bending test for scoliosis", checking the habit of standing 'at ease'-right versus left leg, Duncan Ely-test (or Thom test or Staheli test), pelvis rotation test [20-28], "adduction of hips test-similar to Ober test" and others, presented below in details (Figures 1-9).

Independent of above mentioned tests, there is full list of the tests

and clinical sings for early discovery of scoliosis:

1 Test of adduction of both hips (in extension position of joints-like Ober test). It is checking of limited adduction of the right hip, plus often additionally flexion contracture of hips/right hip (Duncan Ely-Test, or Staheli test or Thom test), checking often on additionally external rotation contracture of the right hip.

2 Looking at shape of the spine (of the body) in flexion test. Explanation: round shape-good, stiff and straight "line of spine"-the beginning of scoliosis.

3 "Bending test for scoliosis"-Adams/Meyer test.

4 "Side bending test for scoliosis"-Karski/Lublin test, it is modified "Adams/Meyer test". This side bending test for scoliosis is

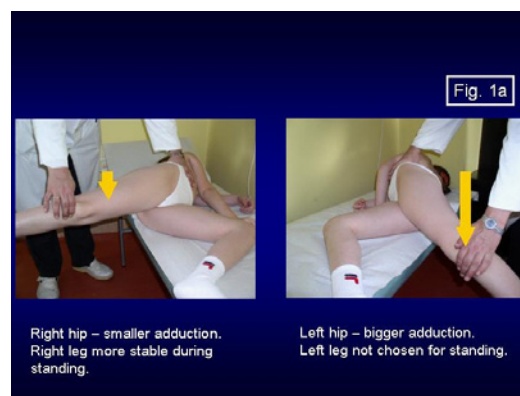


Figure 1a: Adduction test of hips. Knee in extension. Difference in adduction of right and left hip. "Model of hips movement" typical for I-st group. Right leg more stable during standing. Left hip-big adduction. Left leg not chosen for standing.

***Corresponding author:** Tomasz Karski, Former Head of Paediatric Orthopaedics and Rehabilitation Department of Medical University in Lublin, Poland, E-mail: t.karski@neostrada.pl/tmkarski@gmail.com

Received February 04, 2013; **Accepted** April 15, 2013; **Published** April 17, 2013

Citation: Karski J, Karski T (2013) So-Called Idiopathic Scoliosis: Diagnostic Tests: Examples of Children Incorrect Treated: New Therapy by Stretching Exercises and Results. J Nov Physiother 3: 147. doi:[10.4172/2165-7025.1000147](https://doi.org/10.4172/2165-7025.1000147)

Copyright: © 2013 Karski J, et al. This is an open-access article distributed under the terms of the Creative Commons Attribution License, which permits unrestricted use, distribution, and reproduction in any medium, provided the original author and source are credited.

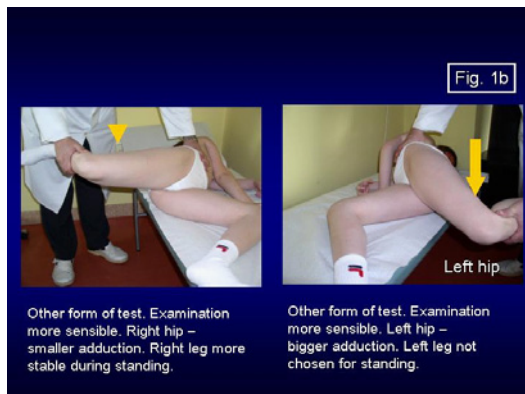

Figure 1b: Other form of test. Knee in flexion. Test more sensible. Contracture of the right hip. Left hip—big adduction. “Model of hips movement” typical for I-st group. Right leg more stable during standing. Left leg not chosen for standing.

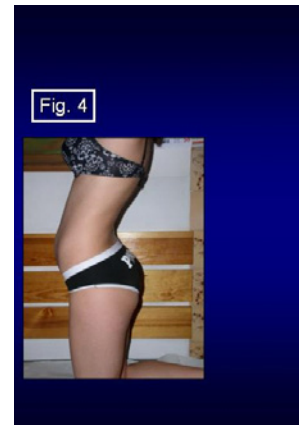


Figure 4: Kneeling test. Test for checking the “position of pelvis”. Pathology. Anterior tilt of pelvis and hiperlordosis lumbalis.

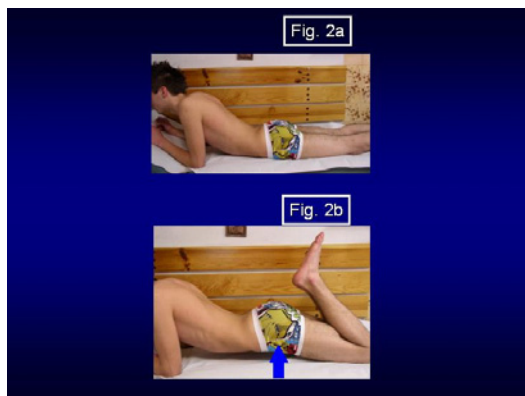


Figure 2: Duncan Ely-Test (or Staheli test or Thom test). Two phases a & b and two stages of examination. Test shown flexion contractures of hips, “anterior tilt” of pelvis and hiperlordosis lumbalis.

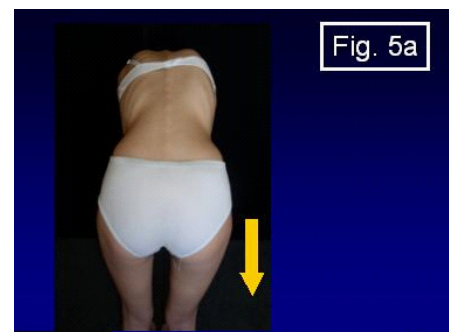


Figure 5a: Adams/Meyer bending test for scoliosis (forward). On the picture child with the “I” scoliosis in III epg.

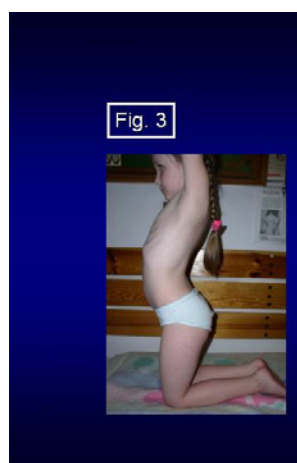


Figure 3: Kneeling test. Test for checking the “position of pelvis”. Pathology. Anterior tilt of pelvis and hiperlordosis lumbalis.

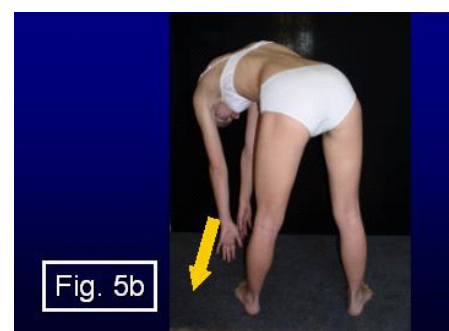


Figure 5b: Lublin/Karski side bending test to the left and to the right leg. On the picture child with the “I” scoliosis in III epg.

more precise—because it increases the sensitivity and specificity of the tests [29-37].

5 Rotation movements of the body test-comparison of the left and right rotation movement of the pelvis and shoulders (whole body) in

“standing straight position” of the child with feet close together [38-49].

6 “Permanent standing at ease” test—on the right /on the left leg. Influenced is “cumulative time” of the standing ‘at ease’ on the right leg. Standing on the left leg is safe for the spine, because is not permanent. Standing on the right leg is permanent.

7 The symmetry or asymmetry of the waist test (old observation, but very important)—the waist is deeper on the left upper part of the thorax, typical for I epg “S” double scoliosis—with stiffness of spine and with gibbous costalis [other name of “S” deformity in I epg: “lordoscoliosis”], deeper waist on the right lower part—typical for II/A “C” scoliosis and for II/B “S” double scoliosis (thoracic secondary). In

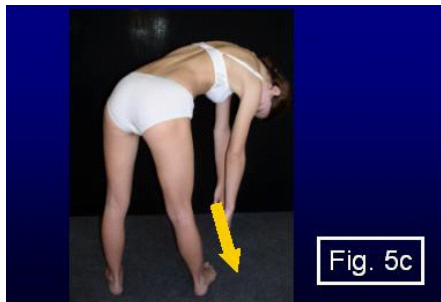


Figure 5c: Lublin/Karski side bending test to the left and to the right leg. On the picture child with the "I" scoliosis in III epg.

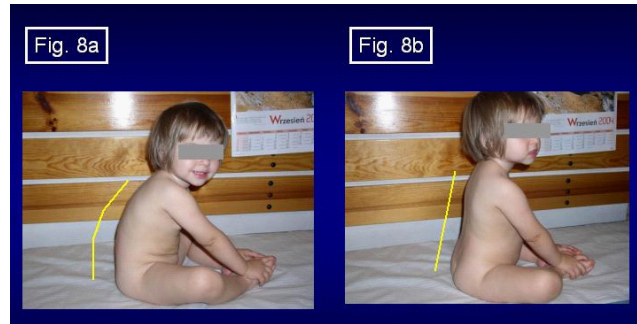


Figure 8: Sitting test. Sitting straight up is not safe for the spine (a). Sitting in relaxed position is safe for the spine (b).

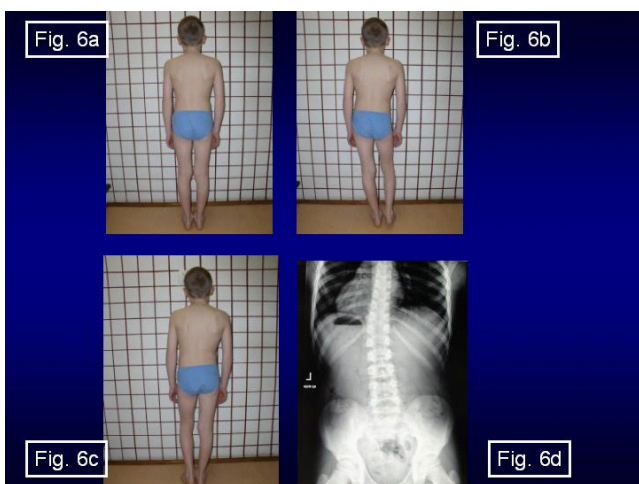


Figure 6: Standing 'at ease' test. (a) standing on both legs without influence on axis of spine. (b) standing 'at ease' on the left leg without influence on axis of spine or, if the scoliosis is present, beneficial influence on axis of spine. (c) standing 'at ease' on the right leg and if "permanent standing" cause of the scoliosis. (d) X-ray picture—the same child- showing "C" scoliosis in II/A epg.

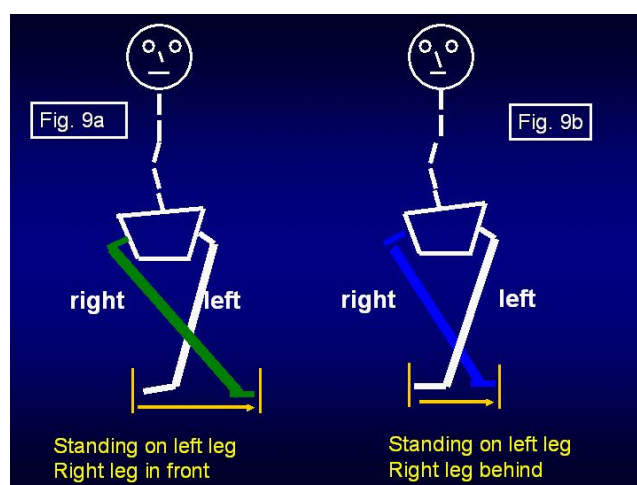


Figure 9: Test of standing on the crossed legs with loading on the left leg. Limited adduction of the right hip inhibits „big crossing" of the legs when the right leg is behind the left leg. Patient with this phenomenon refer to their „drawing" in region of right hip.

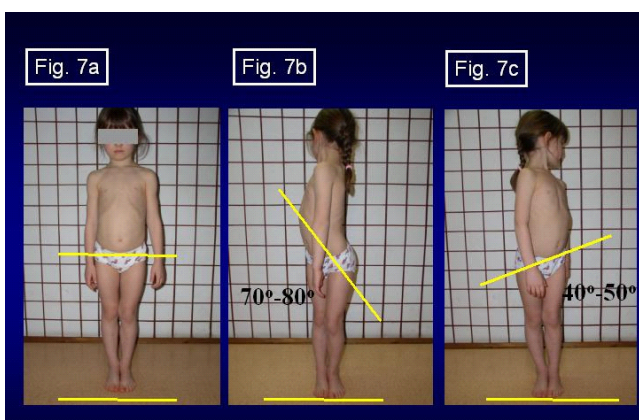


Figure 7: Rotation test of pelvis. The rotation movement from the neutral position (a) to the right side (b) is bigger than to the left side (c), because of external rotation contracture of the right hip.

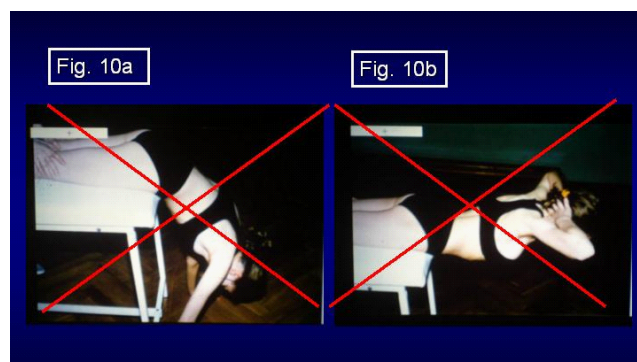


Figure 10: Examples of wrong, its mean incorrect and harmful exercises. Example of incorrectly treated child.

the group II/B "S" the spine deformity is *without stiffness and without gibbous costalis* or minimal and "round" and never stiff. Other name of "S" deformity in II/B epg is: "ky(i)phoscoliosis".

8 Illnesses (e.g. rickets).

9 Anatomical anomalies of the spine (*spina bifida occulta, pectus infundibuliforme*). If present—the proper development of the spine is endangered

10 Body build type-asthenic and picnic (bad), athletic (good).

11 Willingness /intention to participate in sports, if yes-good, if no-bad.

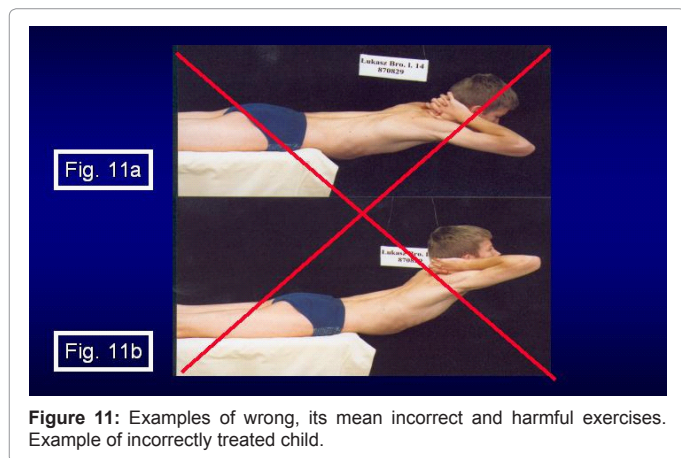


Figure 11: Examples of wrong, its mean incorrect and harmful exercises. Example of incorrectly treated child.

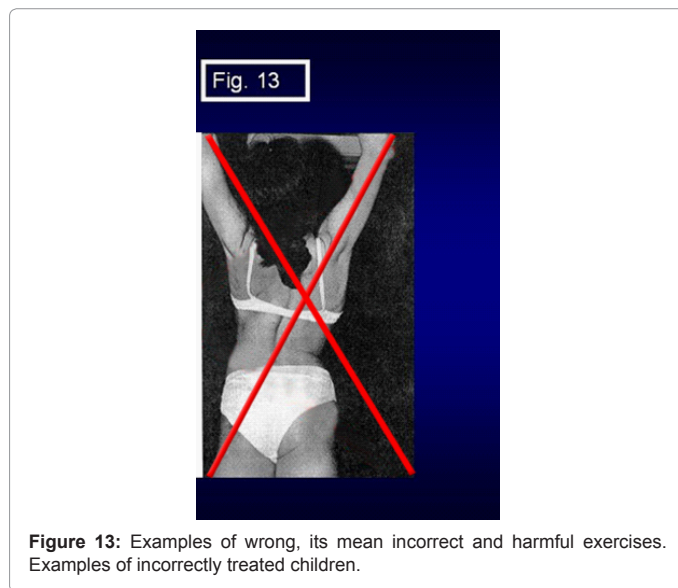


Figure 13: Examples of wrong, its mean incorrect and harmful exercises. Examples of incorrectly treated children.

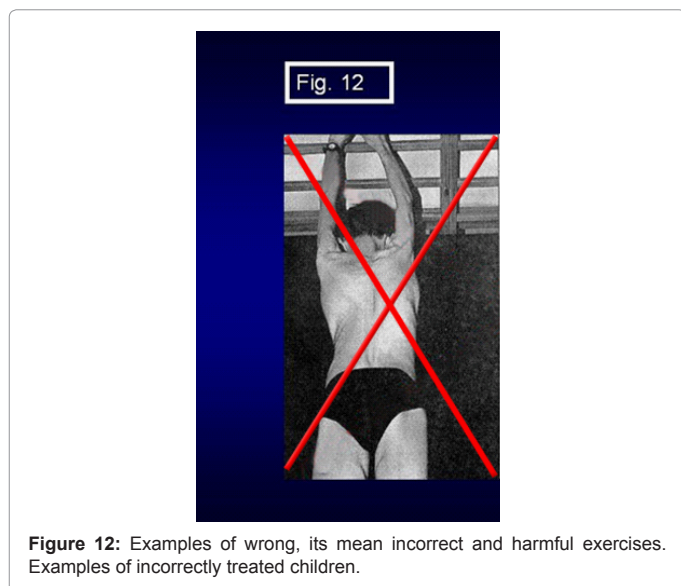


Figure 12: Examples of wrong, its mean incorrect and harmful exercises. Examples of incorrectly treated children.

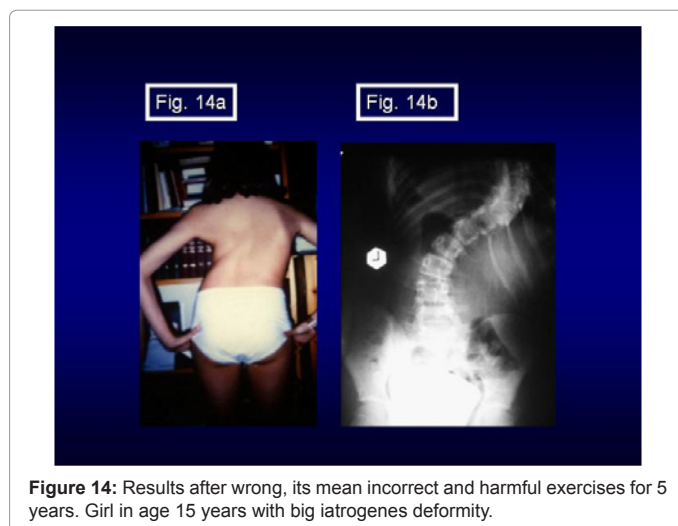


Figure 14: Results after wrong, its mean incorrect and harmful exercises for 5 years. Girl in age 15 years with big iatrogenes deformity.

Old, Harmful Rehabilitation Exercises in Therapy of Scoliosis. Examples of Pitfalls

All old (from the XX century) exercises were based on the conviction that scoliosis is a result of “weakness of muscles”. Because of this, in the past the “strengthened” exercises were very popular and were admitted in many countries. There were as follow:

- a) all exercises in prone position (on stomach) on mattress,
- b) exercises in laying on the rehabilitation table in prone position and lifting up of the trunk,
- c) all other strengthening exercises, presented in figures 10-13.

This old therapy was completely incorrect and wrong. Also so-called “correcting exercises” performed in Polish schools and kindergartens were and still are mostly wrong.

In patients coming to our Department in years 1985–2009 (till 2009 Prof. Karski was the Head of the Department) after such wrong therapy only a huge deformity with big asymmetries of trunk was observed, accompanied by a big hump and totally stiff spine (Figures 14-18). To explain to parents the bad results of therapy—the doctors introduced the term “*the natural history of scoliosis*”.

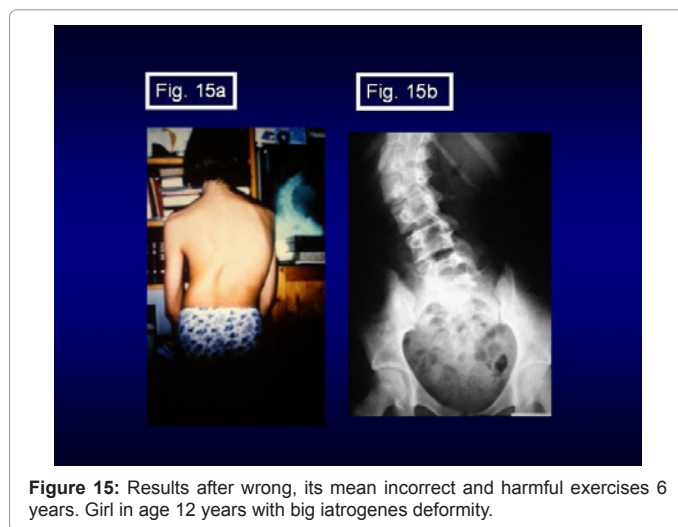

Figure 15: Results after wrong, its mean incorrect and harmful exercises 6 years. Girl in age 12 years with big iatrogenes deformity.

In past, in the treatment and prognosis of results, the special value was putting on “Risser test”. Why—the results were only bad,

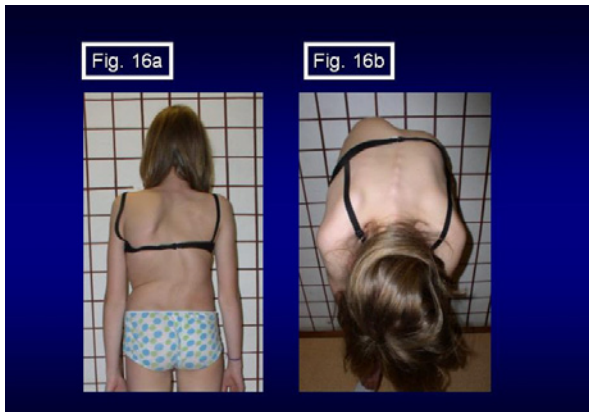

Figure 16: Results after wrong, its mean incorrect and harmful exercises 5 years. Girl in age 12 years with very big iatrogenes deformity.

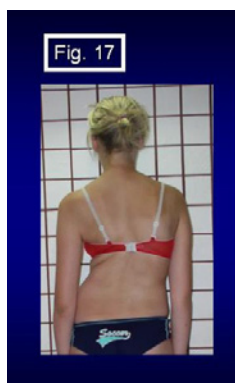


Figure 17: Results after wrong, its mean incorrect and harmful exercises 2 years. Girl in age 13 years with big iatrogenes deformity.

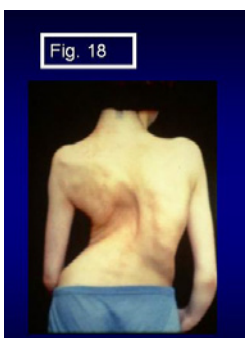

Figure 18: Results after wrong, its mean incorrect and harmful exercises 10 years. Girl in age 18 years with very big iatrogenes deformity.

the worsening of scoliosis was special big in acceleration period of growth—so was important to known which period of growth is before child. To answer for such question, doctors looked to “riser test” and observe Cobb angle of curves [50-54].

New Rehabilitations Exercises

Proper solution for the “scoliosis problem” is an early prophylactics based on “new exercises” taking into consideration the “biomechanical aetiology”. The new rehabilitation exercises should remove the contracture in the region of pelvis, of the hips and in the whole spine. The flexion-rotation exercises should be performed

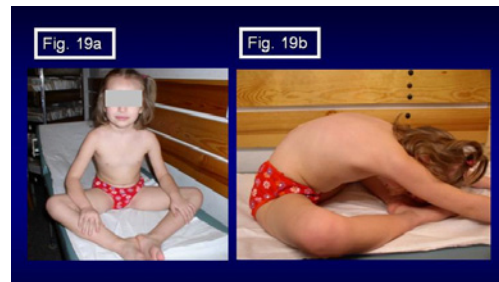

Figure 19: Example of correct exercises for scoliosis. Child is sitting in “Polish way” (Polish manner). Flexion exercises forward from this position. Proper exercises in the programme of prophylaxis and treatment of scoliosis.




Figure 20: Example of proper exercises—for flexion of spine. Two children.




Figure 21: Example of proper exercises—for flexion of spine. Two children.

already at very small children in age of 3-4. It was /is also important to change the position of standing, seating and sleeping (Figures 19-24).

Principles of the new rehabilitation exercises and examples of good results:

- a. removal of the contracture of the right hip,
- b removal of the flexion contracture of the right hip /both hips,

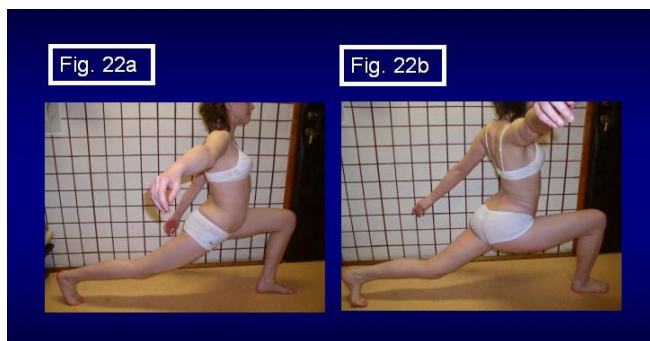


Figure 22: Example of proper exercises—stretching exercises to remove the flexion contracture of hips, especially right hip.

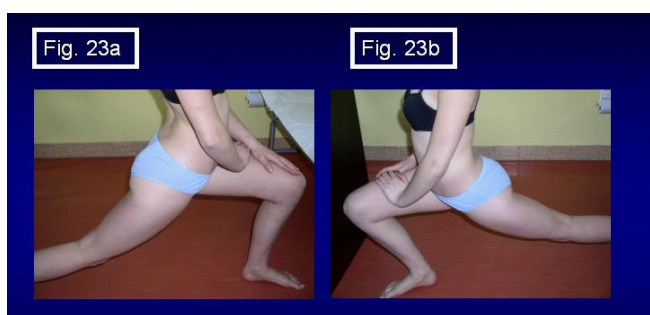

Figure 23: Example of proper exercises—stretching exercises to remove the flexion contracture of hips, especially right hip.




Figure 24: Example of proper exercises—flexion, stretching exercises for spine to remove the contracture on concave side of spine and to restore the “flexion possibility of spine”.

c removal of the contracture on concave side of the both curves—on the left convex lumbar curve and on right convex thoracic curve,

d removal of the extension contracture-“stiffness” of the spine in the thoracic part or in the whole spine (lumbar and thoracic),

e active participation in sports at school and at home every day. Especially are beneficial Kung fu, taekwondo, karate, aikido, tai chi, yoga (Figures 25-27).

f sitting position at school and at home—relaxed, never straight up
g sleeping during the first ten years of life (also later) on the side, in “foetal position” with fully flex spine,

h “standing” on both legs which is with no influence on the spine, “standing at ease” on the left leg—beneficial influence on the spine (protects against scoliosis). Also “the standing” in the position “*uchi hachi ji dachi*” or “*kiba dachi*” (terms taken from Karate) is safe for



Figure 25: Example of proper sport exercises (karate, aikido, taekwondo, joga) in the treatment or in prophylaxis of scoliosis.



Figure 26: Example of proper sport exercises (karate, aikido, taekwondo, joga) in the treatment or in prophylaxis of scoliosis.



Figure 27: Example of proper sport exercises (karate, aikido, taekwondo, joga) in the treatment or in prophylaxis of scoliosis.

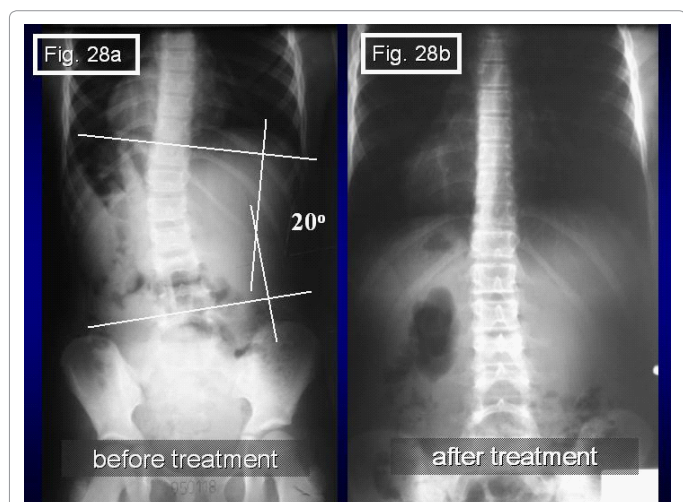


Figure 28: Example of good results after 4 years of the new, proper therapy. Child-Zofia 10 years old. Scoliosis "C" II/A epg (a) and after 4 years of proper exercises (b).

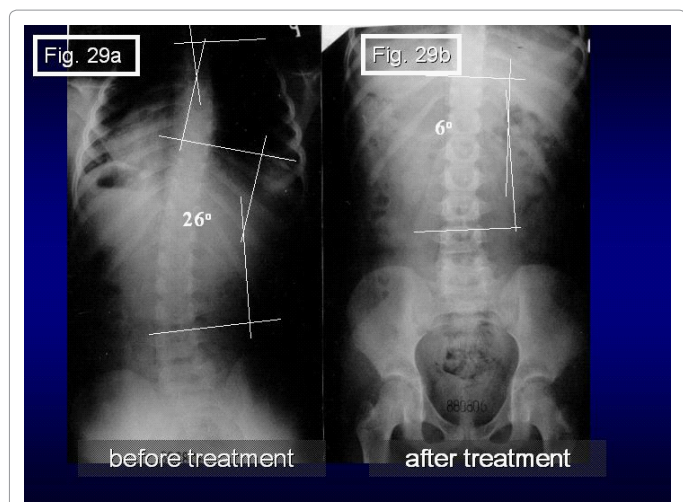


Figure 29: Example of good results after 4 years of new, proper therapy. Child-Anna 13 years old. Initial treatment by incorrect, its mean harmful exercises 2 years. From 2008 new exercises. Results after 2.5 years.

deformities. Such examination should be started in age of 3- 4 years because development of scoliosis start when the child start to stand and start to walk. In new therapy by exercises, should be used the stretching exercises to remove the contractures in region of pelvis and hips as well in concave side of curves.

The children with oncoming scoliosis should take part in extensive sport and the best is karate, taekwondo, aikido and others similarly Far East sport arts.

Conclusions

1. In the rehabilitation therapy of the so-called idiopathic scoliosis-the treatment in every case should be planned in connection to the biomechanical aetiology and the aim of therapy should be "the removal of contractures"

2. Before treatment, every child should undergo the "new screening":

a. should be examined to discover the difference of adduction movement of the hips,

b in Adams test (bending test for scoliosis) or in Lublin test (side

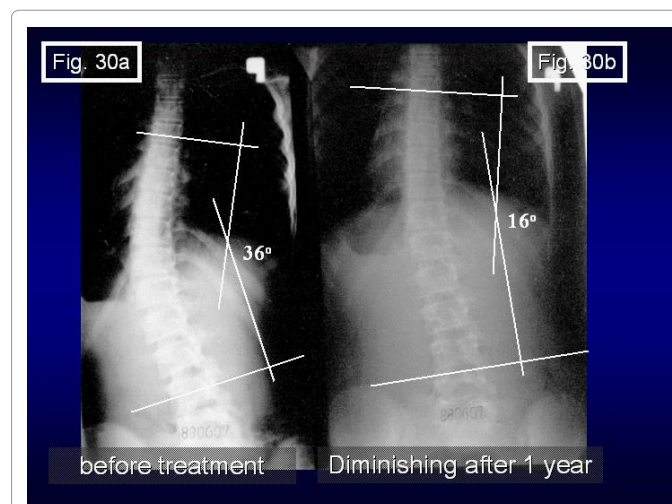


Figure 30: Child-Magdalena 14 years old. Scoliosis "C" II/A epg. Diminishing of curve after 1 year correct exercises and sport.

the spine.

i. corset-model according to Cheneau or "Lublin model" is used mostly for children from the I epg group.-("S" double scoliosis with stiff spine), or for II/B epg group ("S" double scoliosis with flexible spine). In our study 15%-20% of children used the corset.

j. In some children from II/A and II/B epg group of scoliosis we advise the usage of inserts for left shoes 1 cm or 1.5 cm, sometimes 2 cm (necessary clinical examination).

k. After 1-2 years of proper exercises we see the good results. When the child was primary treated by incorrect, harmful exercises the child must make proper exercises for good result longer time (Figures 28-31).

Discussion

In so-called idiopathic scoliosis it is necessary to introduced to Clinic, to orthopaedics and rehabilitation as well to physiotherapy the new method of examination, its mean new tests for discovery of spine

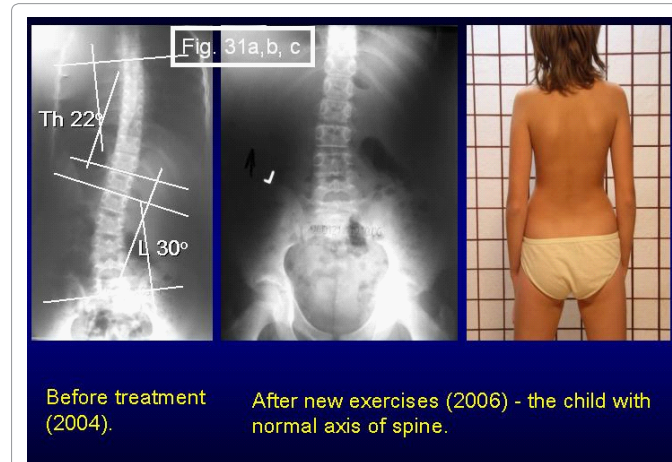


Figure 31: Child-Maria 10 years old. Scoliosis "S" I epg. Diminishing of curves after 2.5 years of correct exercises and sport.

bending test for scoliosis) should be estimated the shape of spine, whether or not the curves are present,

every child should be examined to estimate “the position of pelvis”,

every child should be checked for “the habit of standing ‘at ease’ on left /versus right leg”.

3. In treatment and in prophylaxis only are the proper stretching exercises.

4. All at-risk children should be included in an early program of “prophylactics”:

a sit physiologically (relax), never straight up;

b sleep in foetal position and

c stand “at ease” on the left leg or on both legs.

5. Early prophylactic programmes should also include such sports like: karate, kung fu, taekwoon do, tai chi, aikido, yoga etc.

6. Neo-prophylaxis is possible and very effective-but it should be started very early, in small children in kindergartens and in the first years (1 to 6 grade) of primary school.

Acknowledgement

Many thanks for correcting of English to Claudia Ramirez from USA, student in Medical University in Lublin.

References

- Adams in Tomaschewski R, Popp B (1922) Die Funktionelle Behandlung der beginnenden idiopathischen Skoliose. Jahann Ambrosius Barth, Leipzig Heidelberg 1-96.
- Barlow TG Early diagnosis and treatment of congenital dislocation of the hip. *J.B.J.S.*, 962 44: 292-301
- Benli IT, Akalin S, Aydin E, Baz A, Citak M, et al. (2001) Isola spinal instrumentation system for idiopathic scoliosis. *Arch Orthop Trauma Surg* 121: 17-25.
- Bialik V. in Karski T. Skoliozy tzw. idiopatyczne—etiologia, rozpoznawanie zagrozen, nowe leczenie rehabilitacyjne, profilaktyka. The etiology of the so-called idiopathic scoliosis. The new rehabilitation treatment. Prophylaxis, FOLIUM, Lublin, 2003.
- Burwell G, Dangerfield PH, Lowe T, Margulies J. Spine. Etiology of Adolescent Idiopathic Scoliosis: Current Trends and Relevance to New Treatment Approaches, Volume 14/Number 2, Hanley&Belfus, Inc, May 2000., Philadelphia, str 324.
- Cheneau J. & Matussek in Skoliozy tzw. idiopatyczne—etiologia, rozpoznawanie zagrozen, nowe leczenie rehabilitacyjne, profilaktyka. The etiology of the so-called idiopathic scoliosis. The new rehabilitation treatment. Prophylaxis, FOLIUM, Lublin, 2003.
- Cheung KM, Luk KD (1997) Prediction of correction of scoliosis with use of the fulcrum bending radiograph. *J Bone Joint Surg Am* 79: 1144-1150.
- Cotrel Y, Dubousset J, Guillaumat M (1988) New universal instrumentation in spinal surgery. *Clin Orthop Relat Res* 227: 10-23.
- Dangerfield PH, Dorgan JC, Scutt D, Gikas G, Taylor JF. Stature in Adolescent Idiopathic Scoliosis (AIS).14 Meeting EPOS, Brussels, 5-April 1995, Papers and Abstracts, Page 210.
- Estève de Miguel C. in Karski Tomasz: „Biomechanical Etiology of the So-called Idiopathic Scoliosis (1995-2007). New Classification: Three Groups, Four Sub-types. Connection with „Syndrome of Contractures”, Pan Arab J. Orth. Trauma, vol. (14), No 2, July 2010, pages 69-79.
- Green NE, Griffin PP (1982) Hip dysplasia associated with abduction contracture of the contralateral hip. *J Bone Joint Surg Am* 64: 1273-1281.
- Heikkilä E (1984) Congenital dislocation of the hip in Finland. An epidemiologic analysis of 1035 cases. *Acta Orthop Scand* 55: 125-129.
- Hensinger RN (1979) Congenital dislocation of the hip. *Clin Symp* 31: 1-31.
- Hyanek J.—Prague, Czech Republic—personal information (2004).
- Howorth B. The etiology of the congenital dislocation of the hip, *Clin. Orthop.*, 1977, 29, 164-179
- Karski T. Skoliozy tzw. idiopatyczne—przyczyny, rozwój i utrwalanie sie wady. Profilaktyka i zasady nowej rehabilitacji. The etiology of the so-called idiopathic scoliosis. Progress and fixation of the spine disorders. The prophylaxis and principles of the new rehabilitation treatment, KGM, Lublin, 2000, 1-143.
- Karski T. Skoliozy tzw. idiopatyczne—etiologia, rozpoznawanie zagrozen, nowe leczenie rehabilitacyjne, profilaktyka. The etiology of the so-called idiopathic scoliosis. The new rehabilitation treatment. Prophylaxis. Kontraktury in der Atiologie des sogenannten “idiopathischen Skoliosen”. Prinzipien der neuen Übungstherapie. Möglichkeiten der Prophylaxe, FOLIUM, Lublin, 2003, 1-233.
- Karski T, Karski J, Madej J, Latalski M Persönliche Überlegungen zur Ätiologie der idiopathischen Skoliosen. Praktische Hinweise zur Entdeckung beginnender Skoliosen. Prinzipien der neuen Übungstherapie. Möglichkeiten der Prophylaxe. *Orthop. Praxis*, 02/2002, 38, 75–83.
- Karski T, Makai F, Rehak L, Karski J, Madej J, Kalakucki J The new Rehabilitation treatment of so-called idiopathic scoliosis. The dependence of results on the age of children and the stage of deformity. *Locomotor System* vol. 8, 2001 No.2, 66-71
- Karski T Hip abductor contracture as a biomechanical factor in the development of the so-called “idiopathic scoliosis”. Explanation of the etiology, *Magyar Traumatologia, Ortopedia, Kezsebeszet, Plasztikai Sebeszet*, 1998; 3: 239-246.
- Karski T (1988) The rehabilitation exercises in the therapy and prophylaxis of the so-called “idiopathic scoliosis”, *Acta Ortopaedica Yugoslavica* 29: 5-9.
- Karski T. in Burwell, Dangerfield—Spine. Aetiology of Adolescent Idiopathic Scoliosis: Current Trends and Relevance to New Treatment Approaches, Volume 14/Number 2, Hanley & Belfus, Inc, May 2000., Philadelphia, 324.
- Karski T. Aetiology of the so-called “idiopathic scoliosis”. Biomechanical explanation of spine deformity. Two groups of development of scoliosis. New rehabilitation treatment. Possibility of prophylactics, *Studies in Technology and Informatics, Research into Spinal Deformities* 4, Vol. 91., IOS Press 2002, Amsterdam, Berlin, Oxford, Tokyo, Washington DC, 37-46.
- Karski T Biomechanical aetiology of the so-called idiopathic scoliosis (1995–2007). New clinical and radiological classification. Rules of new rehabilitation treatment and causal prophylactics”. 8th Central European Orthopaedic Congress, June 16–17, 2010, Pecs, Hungary, Abstracts, page: 39-40.
- Karski Tomasz: Biomechanical Etiology of the So-called Idiopathic Scoliosis (1995-2007). New Classification: Three Groups, Four Sub-types. Connection with „Syndrome of Contractures”, *Pan Arab J. Orth. Trauma*, 14: 69-79.
- Karski T. “Skoliozy tzw. idiopatyczne- etiologia, rozpoznawanie zagrozen. Nowa klasyfikacja (2001–2004/2006). Nowe leczenie rehabilitacyjne. Profilaktyka. The etiology of the so-called idiopathic scoliosis. New classification (2—1–2004/2006). The new rehabilitation treatment. Prophylaxis. Ätiologie der sogenannten idiopathischen Skoliosen. Drei pathogenetische Gruppen, vier Typen der Wirbelsäuledeformitäten. Neu Übungstherapie. Prophylaxe”. *Drukarnia KGM, Lublin*, 2011, Ksiazka /stron 420.
- Karski T.: Biomechanical Etiology of The So-Called Idiopathic Scoliosis (1995–2007)—Connection with “Syndrome of Contractures”—Fundamental Information for Pediatricians in Program of Early Prophylactics /*Journal of US-China Medical Science, USA*, May 2011, Volume 8, No 78, pages 259-272.
- Karski Tomasz: Present day explanation of the clinical signs in the biomechanical aetiology of the so-called idiopathic scoliosis (1995–2011). The relationship between the “model of hips movement” and the character of scoliosis; three groups and four types. The causative role of “gait” and “standing ‘at ease’ on the right leg” /*Studies in Health Technology and*

- Informatics, Research into Spinal Deformities 8, IOS Press, Amsterdam–Berlin–Tokyo–Washington DC, 2012, pages 133–138.
29. Karski T. Biomechanical Explanation of Aetiology of the So-Called Idiopathic Scoliosis. Two etiopathological Groups-Important for Treatment and Neo-Prophylaxis *Pan Arab Journal* Vol. (9) No. (1)/January 2005 pp 123-135.
30. Kokavec M L Rehak & P Tissovski–personal information (2000).
31. Kokavec M L Rehak & P Tissovski in Karski Tomasz: Present day explanation of the clinical signs in the biomechanical aetiology of the so-called idiopathic scoliosis (1995-2011). The relationship between the “model of hips movement” and the character of scoliosis; three groups and four types. The causative role of “gait” and “standing “at ease” on the right leg”176: 133-138.
32. Komprda J. in Karski T. Aetiology of the so-called “idiopathic scoliosis”. Biomechanical explanation of spine deformity. Two groups of development of scoliosis. New rehabilitation treatment. Possibility of prophylactics, *Studies in Technology and Informatics, Research into Spinal Deformities* 4, Vol. 91., IOS Press 2002, Amsterdam, Berlin, Oxford, Tokyo, Washington DC, 37-46.
33. Labelle H, Dansereau J, Bellefleur C, de Guise J, Rivard CH, et al. (1995) Peroperative three-dimensional correction of idiopathic scoliosis with the Cotrel-Dubousset procedure. *Spine (Phila Pa 1976)* 20: 1406-1409.
34. La Grone MO (1988) Loss of lumbar lordosis. A complication of spinal fusion for scoliosis. *Orthop Clin North Am* 19: 383-393.
35. Lenke LG, Bridwell KH, Baldus C, Blanke K, Schoenecker PL (1992) Cotrel-Dubousset instrumentation for adolescent idiopathic scoliosis. *J Bone Joint Surg Am* 74: 1056-1067.
36. Magoun (1974) in Normelly H. Asymmetric rib growth as an aetiological factor in idiopathic scoliosis in adolescent girls, Stockholm 1985,1-103.
37. Malawski S (1994) [The author's principles for treating small angle scoliosis in view of current concepts about scoliosis etiology and pathogenesis]. *Chir Narzadow Ruchu Ortop Pol* 59: 189-197.
38. Mau H (1979) [Aetiopathogenesis of scoliosis, hip dysplasia and torticollis in infancy (author's transl)]. *Z Orthop Ihre Grenzgeb* 117: 784-789.
39. Mau H. Die (1982) Aetiopathogenese der Skoliose, Bücherei des Orthopäden, Band 33, Enke Verlag Stuttgart 1-110.
40. Meyer in Tomaszewski R, Popp B. Die (1992) Funktionelle Behandlung der beginnenden idiopathischen Skoliose. Jahann Ambrosius Barth, Leipzig Heidelberg 1-96.
41. Lowe T, Lawellin D, Smith D, Price C, Haher T, et al. (2002) Platelet calmodulin levels in adolescent idiopathic scoliosis: do the levels correlate with curve progression and severity? *Spine (Phila Pa 1976)* 27: 768-775.
42. Oleszczuk J, Szymanski W, Wilczynski: “Patologia ciąży” in ‘Poloznictwo’ Klimek Rudolf, Dream Publ. Comp.Inc., Kraków, 1999, pp. 395-499
43. Rapala K. in Tylman D. Patomechanika bocznych skrzywien kregoslupa, Wydawnictwo Severus, Warszawa, 1995, Seiten 167.
44. Rapala K. in Karski T. Skoliozy tzw. idiopatyczne–etiologia, rozpoznawanie zagrozen, nowe leczenie rehabilitacyjne, profilaktyka. The etiology of the so-called idiopathic scoliosis. The new rehabilitation treatment. *Prophylaxis, FOLIUM*, Lublin, 2003, 1–233.
45. Rehak L., M. Kokavec and P. Tissovsky–personal information during Orthopaedic Congress (Cervenansky Days) in Bratislava, Slovakia (1995–2008).
46. 46.Saji MJ, Upadhyay SS, Leong JC (1995) Increased femoral neck-shaft angles in adolescent idiopathic scoliosis. *Spine (Phila Pa 1976)* 20: 303-311.
47. Staniszew A., Poland–personal information (2010).
48. Stokes IAF. *Studies in Technology and Informatics, Research into Spinal Deformities* 2, Vol. 59., IOS Press 1999, Amsterdam, Berlin, Oxford, Tokyo, Washington DC, 1-385.
49. Tarczynska M, Karski T, Frelek-Karska M. Prenatal conditions for the development of the hip dysplasia in the material of 223 pregnant women, followed-up study of the newborn children”. *EPOS 2000, XIX Meeting of the European Pediatric Orthopaedic Society, Congress Book, Milan, April 5-8.2000*, page P8.
50. Tomaszewski R, Popp B. Die Funktionelle Behandlung der beginnenden idiopathischen Skoliose. Jahann Ambrosius Barth, Leipzig Heidelberg 1992, 1-96.
51. Tylman D. Patomechanika bocznych skrzywien kregoslupa, Wydawnictwo Severus, Warszawa, 1995, Seiten 167.
52. Willers U, Transfeldt EE, Hedlund R (1996) The segmental effect of Cotrel-Dubousset instrumentation on vertebral rotation, rib hump and the thoracic cage in idiopathic scoliosis. *Eur Spine J* 5: 387-393.
53. Willner (1972) in Normelly H: Asymmetric rib growth as an aetiological factor in idiopathic scoliosis in adolescent girls, Stockholm 1985,1-103.
54. Wynne-Davies (1975) in Normelly H: Asymmetric rib growth as an aetiological factor in idiopathic scoliosis in adolescent girls, Stockholm 1985, 1-103.

Citation: Karski J, Karski T (2013) So-Called Idiopathic Scoliosis: Diagnostic Tests: Examples of Children Incorrect Treated: New Therapy by Stretching Exercises and Results. *J Nov Physiother* 3: 147. doi:[10.4172/2165-7025.1000147](https://doi.org/10.4172/2165-7025.1000147)

This article was originally published in a special issue, **Physical Activity and Quality of Life in Chronic Disease** handled by Editor. Dr. Theofilou Paraskevi, Panteion University Athens, Greece

Submit your next manuscript and get advantages of OMICS Group submissions

Unique features:

- User friendly/feasible website-translation of your paper to 50 world's leading languages
- Audio Version of published paper
- Digital articles to share and explore

Special features:

- 250 Open Access Journals
- 20,000 editorial team
- 21 days rapid review process
- Quality and quick editorial, review and publication processing
- Indexing at PubMed (partial), Scopus, EBSCO, Index Copernicus and Google Scholar etc
- Sharing Option: Social Networking Enabled
- Authors, Reviewers and Editors rewarded with online Scientific Credits
- Better discount for your subsequent articles

Submit your manuscript at: <http://www.omicsonline.org/submission/>