

## The Role of Overtube-assisted Deep Enteroscopy ERCP in Roux-en-Y Gastric Bypass Patients

Mohammad F. Ali<sup>1</sup>, Haseeb Ahmed and Shahzad Iqbal

Winthrop University Hospital, Department of Gastroenterology, Hepatology and Nutrition, Mineola, NY, USA

\*Corresponding author: Mohammad F. Ali; MD, Winthrop University Hospital, Department of Gastroenterology, Hepatology and Nutrition, Mineola, NY, USA; E-mail: mfali@winthrop.org

Received: August 22, 2014; Accepted: September 20, 2014; Published: September 25, 2014

Copyright: © 2014 AliMF, et al. This is an open-access article distributed under the terms of the Creative Commons Attribution License, which permits unrestricted use, distribution, and reproduction in any medium, provided the original author and source are credited.

### Abstract

Bariatric surgery is the fastest growing medical intervention for obesity performed in the US and Roux-en-Y Gastric Bypass (RYGB), is considered the "gold standard" comprising more than 60% of these cases. However, patients with surgically altered anatomy after undergoing RYGB pose serious challenges to the endoscopist when access to the biliary or pancreatic systems is required. Hurdles include reaching the major papilla after navigating the length of the roux limb (often >100 cm) given the limitations of standard gastroscopes and even push enteroscopes in achieving sufficient depth of insertion, orientation (upside-down configuration of the papilla), and the lack of accessories that are actually designed for the long endoscopes required for performing ERCPs in this patient population.

To work around the aforementioned problems—specifically the length of the Roux limb—innovative techniques, notably overtube systems have been developed to allow the enteroscope to reach the ampulla and perform ERCP. Three overtube systems are presently available: Double-balloon Enteroscopy (DBE), Single-balloon Enteroscopy (SBE), and Spiral Enteroscopy (SE). This review is designed to describe the role of these 3 overtube systems in assisting with ERCP in RYGB patients based on existing literature and evaluate their success rates in reaching the ampulla, diagnostic & therapeutic yields, and complication rates.

Our review shows good success rates when comparing ability to reach ampulla (DBE-ERCP: 83%; SBE-ERCP: 71%; SE-ERCP: 70%), diagnostic (DBE-ERCP: 77%; SBE-ERCP: 55%; SE-ERCP: 41%) and therapeutic yields (DBE-ERCP: 75%; SBE-ERCP: 81%; SE-ERCP: 68%) with low complication rates for all three systems.

The sheer volume of RYGB procedures being performed and the associated predicted increase in complications will lead to advanced endoscopists encountering more patients with surgically altered anatomy and our review provides evidence that overtube-assisted systems are effective and safe, and should be considered as a first-line modality in RYGB patients requiring ERCP.

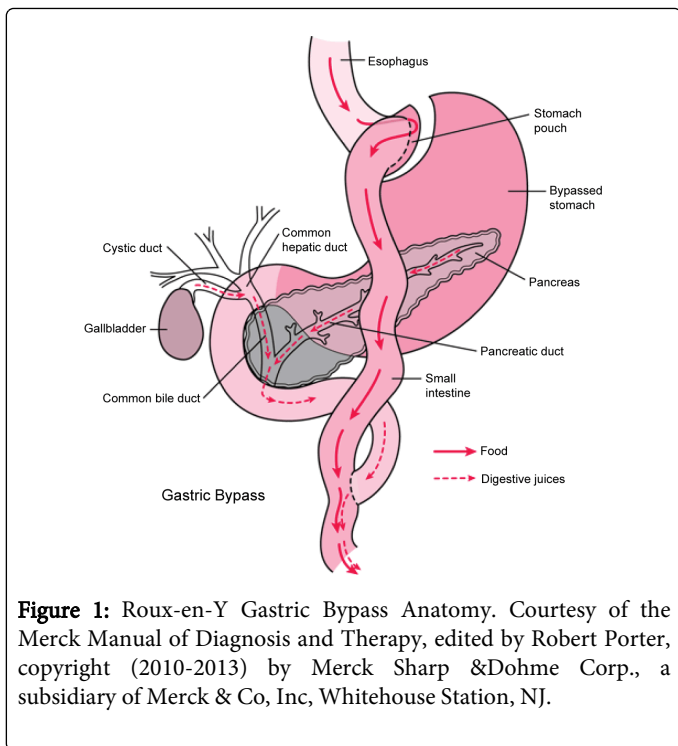
**Keywords:** Enteroscopy; Roux-en-Y gastric bypass; Gold standard; Gut hormones

### Introduction

Bariatric surgical procedures are routinely performed in the United States for weight loss, numbering approximately 200,000 operations annually [1-3]. These procedures achieve that objective through two fundamental mechanisms: (i) malabsorption and (ii) restriction. The Roux-en-Y Gastric Bypass (RYGB), considered the "gold standard" and comprising more than 60% of bariatric procedures performed in the US [4,5], takes advantage of both these processes to accomplish weight loss. It has repeatedly been demonstrated to be better than purely restrictive procedures, such as Vertical Banded Gastroplasty (VBG), in long term weight reduction [6,7]. Other mechanisms purported to contribute to weight loss seen in gastric bypass include dumping syndrome, Roux limb length (usually <150 cm), and gut hormones (ghrelin, Glucagon-like Peptide-1; GLP-1, Cholecystokinin; CCK). The expected weight loss after 2 years is approximately 70% [8].

RYGB entails creating a small gastric pouch (<30ml) that is divided and separated from the distal stomach and anastomosed to a Roux limb of small bowel 75 to 150 cm in length [9,10]. The small gastric pouch and the narrow anastomotic outlet restrict caloric intake, while the major digestion and absorption of nutrients follow in the common channel (Figure 1) where gastric acid, pepsin, Intrinsic Factor (IF), pancreatic enzymes, and bile mix with ingested food [11].

Patients with surgically altered anatomy after undergoing RYGB pose serious challenges to the endoscopist when access to the biliary or pancreatic systems is required. The first hurdle is reaching the major papilla after navigating the length of the roux limb (often >100 cm). Studies have shown the limitation(s) of standard gastroscopes and even push enteroscopes in achieving sufficient depth of insertion in these patients [12,13]. The second hurdle/obstacle involves the orientation. Endoscopists use front viewing scopes so they are not habituated to the upside-down configuration of the papilla in RYGB patients, making cannulation difficult [14]. The third barrier is the lack of accessories that are actually designed for the long endoscopes required for performing Endoscopic Retrograde Cholangiopancreatographies (ERCPs) in this patient population [14,15]. Table 1 lists available enteroscopy length ERCP accessories.



**Figure 1:** Roux-en-Y Gastric Bypass Anatomy. Courtesy of the Merck Manual of Diagnosis and Therapy, edited by Robert Porter, copyright (2010-2013) by Merck Sharp &Dohme Corp., a subsidiary of Merck & Co, Inc, Whitehouse Station, NJ.

To work around the aforementioned problems—specifically the length of the Roux limb— innovative techniques notably overtube systems have been developed to allow the enteroscope to reach the ampulla and perform ERCP. Three overtube-systems are presently available: Double-balloon Enteroscopy (DBE), Single-balloon Enteroscopy (SBE), and Spiral Enteroscopy (SE). This review is designed to describe the role of these 3 overtube systems in assisting with ERCP in RYGB patients based on existing literature and evaluate their success rates in reaching the ampulla, diagnostic & therapeutic yields as defined below, and complication rates.

## Definitions

Diagnostic yield has been defined as successful duct cannulation.

Therapeutic yield has been defined as the ability to successfully carry out an endoscopic therapy when indicated in patients who have been successfully cannulated.

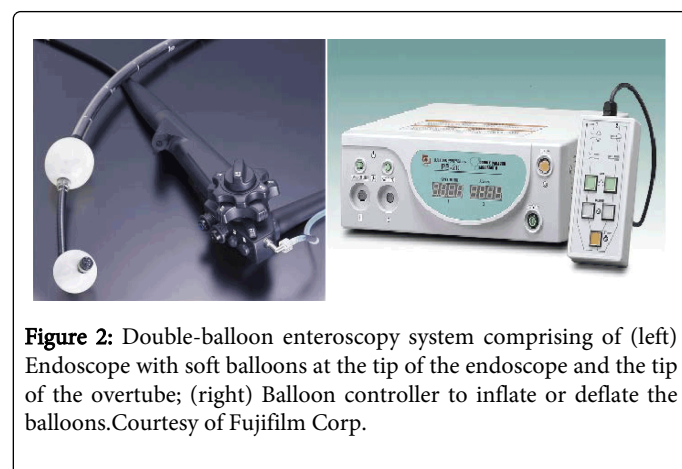
Equipment	Length (cm)	Manufacturer
Sphincterotome Pull-type and needle-knife	250	Fujinon, Cook
Cannula	320	Cook, Olympus
Guidewires	500 550-600 420 480	Medwork Cook, Olympus Boston Scientific
Extraction balloons	multiple sizes	Cook, Olympus
Retrieval basket	230, 250, 260	Olympus, Cook, Fujinon, Medwork
Dilators	240 and 320	Cook, Boston Scientific

Graded passage Balloon or controlled-radial expansion dilators		
Snares	230 250 350	MTW Fujinon US Endoscopy
Stents 5F and 7F		Cook
Cytology brush	350	US Endoscopy
Distal attachment EMR cap		Olympus

**Table 1:** List of available enteroscopy length ERCP accessories.

## DBE-ERCP

The Double-balloon Enteroscopy (DBE) technique, introduced by Yamamoto et al., permits deep intubation of the small bowel. Its development was based on the concept that ‘stretching’ of the small bowel wall prevents further endoscopic advancement, and so using a balloon would grip the intestinal wall and prevent subsequent loop formation [16]. DBE therefore entails a series of steps that employ a push-and-pull technique, facilitating pleating of the small bowel over the enteroscope, allowing for deep enteroscopy. This procedure has led to deeper intubation (240-360 cm antegrade and 102-140cm retrograde) than possible with push enteroscopy (90-150cm) or ileoscopy (50-80cm) [17]. DBE has been validated in case series to be a useful tool in post-surgical patients who require ERCP. Kuga et al. in their paper underlined the usefulness of DBE for endoscopic evaluation of the bypassed stomach after vertical banded gastroplasty with RYGB for morbid obesity and the significant learning curve associated, as reflected in procedure time and the need for fluoroscopic guidance (although with gain of experience the use of fluoroscopy decreased continuously) [18]. DBE-assisted ERCP enables the endoscope to reach the papilla or ductal anastomoses in patients with previous small bowel surgery that would otherwise be challenging with a normal duodenoscope or forward-viewing endoscope (Figure 2).



**Figure 2:** Double-balloon enteroscopy system comprising of (left) Endoscope with soft balloons at the tip of the endoscope and the tip of the overtube; (right) Balloon controller to inflate or deflate the balloons. Courtesy of Fujifilm Corp.

In one of the first case series by Emmett DS and Mallat DB describing DB-ERCP in 6 patients with Roux-en-Y gastric bypass surgery, the ampulla was successfully reached in 100% of the cases,

with adequate cannulation of either the biliary or pancreatic duct in 88% of them [19]. Therapeutic interventions ranged from stone removal to pancreaticobiliary-duct dilation to sphincterotomy. The mean total duration of the procedure was 99+/-48 minutes and there was no reported immediate or short-term complication.

Given the forward-viewing nature of the endoscopes used for ERCP and the limited number of accessories compatible with the standard double enteroscope due to its length, cannulation of the native papilla may be difficult with DBE-ERCP. This issue can be overcome with the use of a 'short' DBE system that has a 152 cm working length and is compatible with conventional accessories.

A multicenter study by Siddiqui et al. performed ERCPs in 39 RYGB patients using the 'short' double balloon enteroscope (EC-450BI5; Fujinon), achieving successful bile duct cannulation in 29 of the 32 patients in whom the papilla/surgical anastomoses was reached. A full spectrum of therapeutic maneuvers was performed, including sphincterotomy, stone extraction, balloon dilation, and the insertion of plastic/metal stents [20-25]. Additionally, studies have been done by Moreels et al. [22] and Patel et al. [26] demonstrating the feasibility of diagnostic and therapeutic DBE-ERCP in large cohorts of patients who had undergone a variety of Roux-en-Y reconstructive surgeries. These studies along with others are summarized in Table 2.

Indications for DBE-ERCP in the tabulated articles ranged from abdominal pain, abnormal LFTs, anemia/GI bleed, acute/chronic pancreatitis, cholangitis, and biliary/pancreatic duct dilatation to removal of a previously placed stent, sphincter of Oddi dysfunction type 1, post-cholecystectomy bile leak [27], pancreatic anastomotic stricture, suspected common bile duct stone/stricture, and suspected pancreaticobiliary cancer.

Various factors have been cited as affecting yield in these studies. In the Shah et al. multicenter experience, three-fourths of ERCP failures

were related to the inability of the enteroscope to be advanced to the papilla of the pancreaticobiliary-enteric anastomosis [25]. Given such mechanical obstacles, yield can be impacted if the primary end point of the study is therapeutic intervention. For instance, even if cholangiography is achieved but the intended therapeutic intervention is unsuccessful, it may be considered a technical failure. Patel et al. added that diagnostic yield was dependent on the type of altered bowel anatomy and the indication for ERCP, such as biliary versus pancreatic indication [26]. The success rate of DBE-ERCP according to them was much lower for pancreatic indication compared with biliary indication. Along parallel lines Choi et al. opined that DBE-ERCP had a reasonable success rate for managing biliary stone disease but did not adequately address Sphincter of Oddi Dysfunction (SOD) and pancreatic diseases [24]. Note must also be made of the possible advantages afforded by the short DBE system namely better maneuverability, effective pressure application to the enteroscope (increasing the likelihood of reaching the papilla or anastomosis, and allowing the use of commercially available ERCP cannulas), and the use of instruments to intervene therapeutically— benefits which clearly improved the overall success rate/yields in those respective studies.

Additionally, authors urged further evaluation of the role of the endoscopist's training for complex DBE, technical limitation of the DBE endoscope (increasing accessory channel, incorporating a side-vision optical system, adding an elevator system), and DBE accessories for ERCP (longer pancreaticobiliary stent delivery system) on the diagnostic yield of DBE in patients with surgically altered bowel anatomy.

Overall, DBE-ERCP enabled the ampulla to be reached in 83% (90 of 108 attempts) of the cases, with a diagnostic yield of 77%, and a therapeutic yield of 75%. Time needed to complete the procedure was between 90-134 minutes with minimal complications (3-12% overall).

Author	Year	# of patients/cases	Ampulla reached (%)	Diagnostic Yield (%)	Therapeutic Yield (%)	Time (mins)	Complications
Mehdizadeh et al.	2006	4	3/4(75)	N/A	N/A	96.2+/-28.8	none
Emmett & Mallat	2007	6	6/6 (100)	5/6(88)	N/A	110+/- 37	none
Kuga et al.	2009	1	1/1 (100)	1/1(100)	1/1(100)	134	none
Siddiqui et al.†	2012	39	32/39 (82)	29/32 (91)	68/79(86) overall	N/A	Abdominal pain (3/79), pancreatitis (3), bleeding (1)
Choi et al.†	2013	28	25/32 (78)	20/32 (63)	18/32(56)	101.2+/- 36.8	3.1%; Pancreatitis (1)
Shah et al.	2013	15	13/15 (87)	N/A	10/15(67)	90-120 (50% reported)	Overall 12%; Perforation (2), abdominal pain (3), throat pain (4), pancreatitis (5), bleeding (1), death (1)
Patel et al.	2013	11§	10/11 (91)	8/11(73)	7/11(64)	N/A	none
Overall/Total		104	90/108 (83)	63/82 (77)	101/138 (75)	90-134	

**Table 2:** DBE-ERCP studies in RYGB patients.†Short DBE used; §Includes few non-bariatric roux-en-y cases.

### SBE-ERCP

Single-balloon Enteroscopy (SBE), introduced in 2007, is a novel technique that uses a single-balloon splinting overtube to sequentially reduce and pleat the small bowel over a standard endoscope (Figure 3). The splinting overtube also lets the endoscopist negotiate acute angulations sometimes found at gastroenteric or enteroenteric anastomosis. Of note, the balloon is on the tip of the overtube but not on the endoscope so unlike DBE eliminates the step of inflating an endoscope balloon. Thus SBE is technically easier to perform than DBE. Despite this advantage, the maximal length of insertion achieved with DBE is significantly greater, 254 +/- 174 cm beyond the pylorus, 180 +/- 150 cm beyond the ileo-cecal valve, [28] than that with SBE (155 cm).

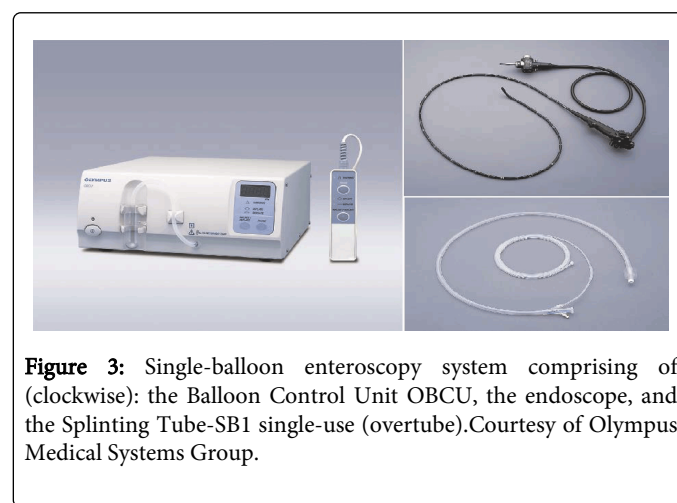
Dellon et al. initially proved the feasibility of SBE-ERCP in a small case series of patients with prior Roux-en-Y anastomosis [29]. Consequently, larger experiences with SBE-ERCP in patients with Roux-en-Y in the setting of gastric bypass have been published. The findings of these studies are summarized in Table 3.

Indications for SBE-ERCP ran the gamut from the evaluation of abdominal pain with abnormal LFT results and/or biliary ductal dilation, acute/recurrent cholangitis, cholangitis with retained biliary stent after pancreaticoduodenectomy to symptomatic choledocholithiasis with a PTC (Percutaneous Transhepatic Cholangiogram) drain in place, pancreatitis secondary to microlithiasis, biliary stricture or ampullary mass, cholestasis, recurrent primary sclerosing cholangitis with strictures, and choledocholithiasis amongst others [30].

While Saleem et al. [31], attributed unsuccessful ERCPs negatively affecting yield to failure to identify the afferent limb of the Roux-en-Y anastomosis, marked bowel loop angulations, inability to enter the afferent limb, and failed cannulation of native papillae, Lennon et al. highlighted that the only factor associated with increasing diagnostic

yield was operator experience which was associated with a significant increase in diagnostic success rates in SBE-ERCP [32]. Dellon et al. reported the time- and labor- intensive (two person procedure) nature of SBE-ERCP and the persistent challenges related to reliably identifying the biliary jejunal limb, stable endoscope positioning for cannulation, and appropriate accessory devices as probable contributors to yield and success rates [29]. Other postulated influencing factors were the type of roux-en-y anatomy, cannulation rates in patients with surgical anastomosis versus native ampulla, and the type of sedation.

Overall, the ampulla was reached in 71% (81 of 114) of the patients/cases when single-balloon enteroscopy assisted ERCP; the diagnostic yield of 55% and a therapeutic yield of 81% were achieved. Average time (mean) needed to complete the procedure was between 72-120 minutes with minimal complications (3.5-12.5% overall).



**Figure 3:** Single-balloon enteroscopy system comprising of (clockwise): the Balloon Control Unit OBCU, the endoscope, and the Splinting Tube-SB1 single-use (overtube). Courtesy of Olympus Medical Systems Group.

Author	Year	# of patients/cases	Ampulla reached (%)	Diagnostic Yield (%)	Therapeutic Yield (%)	Time (mins)	Complications
Dellon et al.	2008	1	1/1 (100)	1/1(100)	N/A	91	none
Wang et al.	2010	6	6/6 (100)	6/6(100)	6/6(100)	91-212	Overall 12.5%; Pancreatitis (2)
Saleem et al.	2010	15	42/56 (75) overall	7/15(47)	21/23(91) overall	78.27	none
Lennon et al.	2011/ 2012	12	16/29 (55)	14/29(39)	8/8(100)	72+/-34	Perforation (3.5%)
Shah et al.	2013	22	16/22 (73)	N/A	13/22(59)	90-120 (50% reported)	Overall 12%; Perforation (2), abdominal pain (3), throat pain (4), pancreatitis (5), bleeding (1), death (1)
Overall		56	81/114 (71)	28/51(55)	48/59(81)	72-120	

**Table 3:** SBE-ERCP studies in RYGB patients.

### SE-ERCP

Spiral Enteroscopy (SE) employs a 'rotating' overtube that tucks the small bowel onto the overtube resulting in deep advancement of an endoscope (Figure 4). Dr. Paul Akerman was the first advocate of this

method for enteroscopy. The first case employing the "rotate to advance" concept was performed in 2006 by him and Cantero [33]. Potential advantages of spiral enteroscopy-assisted ERCP over DB-ERCP or SB-ERCP as pointed to by Kogure et al. in their review

include relative ease of use, better endoscope control, and perhaps a shorter learning curve [34].


Spiral overtube-assisted ERCP was at the outset reported only as small retrospective case series in abstract form. Wagh and Draganov were the first to publish a prospective evaluation of SE-ERCP in patients with surgically altered anatomy [35]. Thereafter, studies assessing SE-ERCP in RYGB patients were published. These studies are summarized in Table 4.

Indications for SE-ERCP were akin to the other overtube assisted systems: biliary obstruction, bile duct stones, pancreatic duct leaks, abnormal LFTs, cholangitis, abnormal liver enzyme levels, and pancreatitis.

As far as factors affecting yield, Wagh et al. contended that if the papilla/duct enterostomy was reached, cannulation of the desired duct and endoscopic therapy was successful in 90% of the procedures [35]. This observation is in keeping with the Shah et al. multicenter experience, where three-fourths of ERCP failures were related to the

inability of the enteroscope to reach the papilla of pancreaticobiliary-enteric anastomosis.

Overall, utilizing SE-ERCP aided access to the ampulla 70% (45 of 64) of the time in RYGB patients. Diagnostic yield of 41% and therapeutic yield of 68% was attained across cases. Mean time required to complete the procedure was 81-120 minutes.



Author	Year	# of patients/cases	Ampulla reached (%)	Diagnostic Yield (%)	Therapeutic Yield (%)	Time (mins)	Complications
Lennon et al.	2011/ 2012	12	16/25(64)	10/25 (40)	7/8(87.5)	81.9 +/- 34.6	none
Wagh et al.	2012	4	10/13 (77) overall	2/4(50)	9/13(69) overall	95.6 (24-249) overall	none
Shah et al.	2013	26	19/26 (73)	N/A	16/26(62)	90-120 (50% reported)	Overall 12%; Perforation (2), abdominal pain (3), throat pain (4), pancreatitis (5), bleeding (1), death (1)
Overall		42	45/64 (70)	12/29 (41)	32/47(68)	81-120	

**Table 4:** Spiral Enteroscopy-ERCP studies in RYGB patients.

## Comparative

A few studies to date have pitted DB-ERCP against the two other forms of deep enteroscopy assisted ERCP, Single Balloon-ERCP (SB-ERCP) and spiral/rotational- ERCP, especially in RYGB patients. Shah et al. recently published a multicenter, U.S. experience to evaluate and compare ERCP success by using any of the aforesaid 3 modalities in this subset of patients. It draws from a pool of 129 individuals, 63 with RYGB and breakdown their SB-, DB-, spiral- enteroscopy success (73% vs. 87% vs. 73% respectively) and assisted ERCP success (59% vs. 67% vs. 62% respectively) numbers. The study concluded that enteroscopy success was similar among SBE, DBE, and rotational overtubeenteroscopy methods [25].

Likewise, Lennon et al. compared single-balloon assisted ERCP and spiral assisted ERCP in patients with Roux-en-Y anatomy in terms of diagnostic and therapeutic yield, procedure time, and complications [32]. They concluded that diagnostic and therapeutic yields are similar with SBE-ERCP and SE-ERCP in patients with Roux-en-Y anatomy with no significant differences in procedure time or complication rates.

As far as comparative studies exploring transoral (e.g. double-balloon) versus surgical approach is concerned, Choi et al. identified 72 RYGB patients who had ERCP via either gastrostomy (GERCP) vs. double balloon enteroscopy [24]. Of the 32 DB-ERCPs performed, the ampulla was reached 78% of the time with a diagnostic yield of 63%

and therapeutic yield of 56%. This was in comparison to 97% across the board (accessing MP, cannulation rate, intervention) for gastrostomy assisted ERCP. The major weakness/downside of GERCP was the complication rate, nearly 5 times (14.5% vs. 3.1%) that of DB-ERCP.

Similarly, studies like that undertaken by Schreiner et al. have looked at RYGB patients who underwent Laparoscopy-assisted (LA) as opposed to Balloon Enteroscopy-assisted (BEA) ERCP [36]. BEA included single- and double-balloon enteroscopy. Understandably, LA-ERCP was superior to BEA-ERCP in papilla identification and cannulation rate, but data from the retrospective chart review suggested that patients having a Roux + LTJJ (from ligament of Treitz to jejunojejunal anastomosis) limb length less than 150 cm had significantly higher rate of therapeutic success with BEA-ERCP compared with those with Roux + LTJJ limb length 150 cm or longer (88% vs 25%, respectively) and hence the authors recommended it be offered first in these individuals. There was no difference in postprocedure hospital stay or complication rate between the LA-ERCP and BEA-ERCP groups. Univariate and multivariate analysis revealed greater success rate with double-balloon enteroscopy than with single balloon enteroscopy.

Desai et al. has published an analogous study matching spiral enteroscopy versus laparoscopic-assisted endoscopy for completion of ERCP in patients with RYGB surgery [37]. The primary outcome

measured was successful cannulation of the bile duct which, was found to be 57% in spiral group vs. 100% in surgical group. However, the conclusion was that if cholangiogram was successful using spiral enteroscopy, there was a decrease in the need for hospitalization, length of stay and total cost. In other words, spiral enteroscopy was deemed to be a potential cost saving alternative in patients with Roux-en-Y anatomy with biliary complications.

## Discussion/Conclusions

RYGB is one of the fastest emerging hospital procedures and the most common bariatric/weight-loss intervention in the United States. Complications of RYGB are varied and are dependent on surgical approach (open versus laparoscopic). They include gastric remnant distension, stomal stenosis, marginal ulcers, cholelithiasis, hernias and Dumping/Short Bowel Syndrome amongst others [38]. Given the sheer volume of RYGB procedures being performed and the associated predicted increase in complications, advanced endoscopists can expect to encounter more patients with surgically altered anatomy in the years to come and hence the need for more training.

The main hurdle as mentioned before has been identifying and traversing the transformed anatomy post RYGB during ERCP. This has been overcome with the help of overtube systems. Currently three are available: double-balloon, single-balloon, and rotational.

Our review, based on recent literature & publications, shows good success rates when comparing ability to reach ampulla (DBE-ERCP: 83%; SBE-ERCP: 71%; SE-ERCP: 70%), diagnostic (DBE-ERCP: 77%; SBE-ERCP: 55%; SE-ERCP: 41%) and therapeutic yields (DBE-ERCP: 75%; SBE-ERCP: 81%; SE-ERCP: 68%) with low complication rates for all three systems. Given these results, the overtube system of choice to be used for a given procedure/ERCP is at the discretion and comfort-level of the endoscopist.

Mention must be made of the "short" DBE system, which measures 152 cm in length and is short enough to let standard length ERCP accessories to be used. The length of the conventional "long" double-balloon enteroscope (200cm) precludes the use of many standard ERCP devices. This makes biliary and pancreatic interventions challenging and time consuming. Another reason why more accessories need to be developed for overtube assisted systems in the future.

In conclusion, our data gives an overview of all three available overtube systems for ERCP in RYGB patients. The current literature supports the use of all overtube-assisted systems. They are effective and safe, with low complication rates. So they need to be considered as a first line modality in RYGB patients requiring ERCP.

## References

1. American Society for Metabolic and Bariatric Surgery (2009) Fact Sheet: Metabolic & Bariatric Surgery.
2. Nguyen NT, Masoomi H, Magno CP, Nguyen XM, Laugenour K, et al. (2011) Trends in use of bariatric surgery, 2003-2008. *J Am Coll Surg* 213: 261-266.
3. Metabolic and Bariatric Surgery Accreditation and Quality Improvement Program. American College of Surgeons.
4. Nelson DW, Blair KS, Martin MJ (2012) Analysis of obesity-related outcomes and bariatric failure rates with the duodenal switch vs gastric bypass for morbid obesity. *Arch Surg* 147: 847-854.
5. Santry HP, Gillen DL, Lauderdale DS (2005) Trends in bariatric surgical procedures. *JAMA* 294: 1909-1917.
6. Gentileschi P, Kini S, Catarci M, Gagner M (2002) Evidence-based medicine: open and laparoscopic bariatric surgery. *SurgEndosc* 16: 736-744.
7. Melvin WS (2004) Roux-en-Y gastric bypass is the operation of choice for bariatric surgery. *J Gastrointest Surg* 8: 398-400.
8. Khashab MA, Okolo PI 3rd (2011) Accessing the pancreaticobiliary limb and ERCP in the bariatric patient. *GastrointestEndosc Clin N Am* 21: 305-313.
9. Elder KA, Wolfe BM (2007) Bariatric surgery: a review of procedures and outcomes. *Gastroenterology* 132: 2253-2271.
10. Samuel I, Mason EE, Renquist KE, Huang YH, Zimmerman MB, et al. (2006) Bariatric surgery trends: an 18-year report from the International Bariatric Surgery Registry. *Am J Surg* 192: 657-662.
11. ASBMS The Story of Surgery for Obesity. Brief History and Summary of Bariatric Surgery. Chapter 3, Gastric Bypass.
12. Upchurch BR, Vargo JJ (2008) Small bowel enteroscopy. *Rev GastroenterolDisord* 8: 169-177.
13. ASGE Technology Committee, Tierney WM, Adler DG, Conway JD, Diehl DL, et al. (2009) Overtube use in gastrointestinal endoscopy. *GastrointestEndosc* 70: 828-834.
14. Ross AS (2009) Endoscopic retrograde cholangiopancreatography in the surgically modified gastrointestinal tract. *GastrointestEndosc Clin N Am* 19: 497-507.
15. Haber GB (2007) Double balloon endoscopy for pancreatic and biliary access in altered anatomy (with videos). *GastrointestEndosc* 66: S47-50.
16. Yamamoto H, Sekine Y, Sato Y, Higashizawa T, Miyata T, et al. (2001) Total enteroscopy with a nonsurgical steerable double-balloon method. *GastrointestEndosc* 53: 216-220.
17. Elena RM, Riccardo U, Rossella C, Bizzotto A, Domenico G, et al. (2012) Current status of device-assisted enteroscopy: Technical matters, indication, limits and complications. *World J GastrointestEndosc* 4: 453-461.
18. Kuga R, Safatale-Ribeiro AV, Sakai P, Ishida RK, Faintuch J, et al. (2006) Usefulness of the Double-Balloon Endoscope for Endoscopic Evaluation of the Bypassed Stomach After Vertical Banded Gastroplasty with Roux-En-Y Gastric Bypass for Morbid Obesity. *Gastrointestinal Endoscopy* 63: AB 162.
19. Emmett DS, Mallat DB (2007) Double-balloon ERCP in patients who have undergone Roux-en-Y surgery: a case series. *GastrointestEndosc* 66: 1038-1041.
20. Siddiqui AA, Chaaya A, Shelton C, Marmion J, Kowalski TE, et al. (2013) Utility of the Short Double-balloon Endoscope to Perform Pancreaticobiliary Interventions in Patients with Surgically Altered Anatomy in a US Multicenter Study. *Digestive Diseases and Sciences* 58: 858-864.
21. Mehdizadeh S, Ross A, Gerson L, Leighton J, Chen A, et al. (2006) What is the learning curve associated with double-balloon enteroscopy? Technical details and early experience in 6 U.S. tertiary care centers. *Gastrointestinal Endoscopy* 64: 740-750.
22. Moreels TG, Hubens GJ, Ysebaert DK, Op de Beeck B, Pelckmans PA (2009) Diagnostic and therapeutic double-balloon enteroscopy after small bowel Roux-en-Y reconstructive surgery. *Digestion* 80: 141-147.
23. Kuga R, Furuya CK Jr, Hondo FY, Ide E, Ishioka S, et al. (2008) ERCP using double-balloon enteroscopy in patients with Roux-en-Y anatomy. *Dig Dis* 26: 330-335.
24. Choi EK, Chiorean MV, Coté GA, El Hajj II, Ballard D, et al. (2013) ERCP via gastrotomy vs. double balloon enteroscopy in patients with prior bariatric Roux-en-Y gastric bypass surgery. *SurgEndosc* 27: 2894-2899.
25. Shah RJ, Smolkin M, Yen R, Ross A, Kozarek RA, et al. (2013) A multicenter, U.S. experience of single-balloon, double-balloon, and rotational overtube-assisted enteroscopy ERCP in patients with surgically altered pancreaticobiliary anatomy. *GastrointestEndosc* 77: 593-600.
26. Patel MK, Horseley-Silva J, Gómez V, Stauffer JA, Stark ME, et al. (2013) Double Balloon Endoscopy Procedure in Patients with Surgically

- Altered Bowel Anatomy: Analysis of a Large Prospectively Collected Database. *J Laparoendosc&Adv Surgical Techniques* 23: 409-413.
27. Gutierrez JP, Smith IB, Wilcox CM, Mönkemüller K (2013) Bile leak from the duct of Luschka treated with double-balloon enteroscopy ERCP in a patient with Roux-en-Y gastric bypass. *Endoscopy* 45 Suppl 2 UCTN: E404.
  28. Di Caro S, May A, Heine DG, Fini L, Landi B, et al. (2005) The European experience with double-balloon enteroscopy: indications, methodology, safety, and clinical impact. *GastrointestEndosc* 62: 545-550.
  29. Dellon ES, Kohn GP, Morgan DR, Grimm IS (2009) Endoscopic retrograde cholangiopancreatography with single-balloon enteroscopy is feasible in patients with a prior Roux-en-Y anastomosis. *Dig Dis Sci* 54: 1798-1803.
  30. Wang AY, Sauer BG, Behm BW, Ramanath M, Cox DG, et al. (2010) Single-balloon enteroscopy effectively enables diagnostic and therapeutic retrograde cholangiography in patients with surgically altered anatomy. *GastrointestEndosc* 71: 641.
  31. Saleem A, Baron TH, Gostout CJ, Topazian MD, Levy MJ, et al. (2010) Endoscopic retrograde cholangiopancreatography using a single-balloon enteroscope in patients with altered Roux-en-Y anatomy. *Endoscopy* 42:656.
  32. Lennon AM, Kapoor S, Khashab M, Corless E, Amateau S, et al. (2012) Spiral assisted ERCP is equivalent to single balloon assisted ERCP in patients with Roux-en-Y anatomy. *Dig Dis Sci* 57: 1391-1398.
  33. Akerman PA, Cantero D (2009) Spiral enteroscopy and push enteroscopy. *GastrointestEndoscClin N Am* 19: 357-369.
  34. Kogure H, Watabe H, Yamada A, Isayama H, Yamaji Y, et al. (2011) Spiral enteroscopy for therapeutic ERCP in patients with surgically altered anatomy: actual technique and review of the literature. *J HepatobiliaryPancreatSci* 18: 375-379.
  35. Wagh MS, Draganov PV (2012) Prospective evaluation of spiral overtube-assisted ERCP in patients with surgically altered anatomy. *GastrointestEndosc* 76: 439-443.
  36. Schreiner MA, Chang L, Gluck M, Irani S, Gan SI, et al. (2012) Laparoscopy-assisted versus balloon enteroscopy-assisted ERCP in bariatric post-Roux-en-Y gastric bypass patients. *GastrointestEndosc* 75: 748-756.
  37. Desai SV, Naveed M, Jazwinski A, Jowell PS, Branch MS (2011) Spiral Enteroscopy Versus Laparoscopic-Assisted Endoscopy for Completion of ERCP in Patients With Roux-en-Y Gastric Bypass Surgery. *GastrointestEndosc*. 73: AB122.
  38. Wright BE, Cass OW, Freeman ML (2002) ERCP in patients with long-limb Roux-en-Y gastrojejunostomy and intact papilla. *GastrointestEndosc* 56: 225-232.