

## Verrucous Psoriasis and Verrucous Lichen Associated With an Autoimmune Hepatitis

Inani Kawtar<sup>1\*</sup>, Meziane Mariame<sup>1</sup>, Lakjiri Siham<sup>1</sup>, Mernissi Fatimazahra<sup>1</sup>, Ameurtesse Hassania<sup>2</sup>, Harmouch Taoufiq<sup>1</sup>, Amarti Afaf<sup>2</sup> and Noureddine Aqodad<sup>3</sup>

<sup>1</sup>Dermatology Department Chu Hassan II Fez 30000 Morocco

<sup>2</sup>Pathology Department Chu Hassan II FEZ 30000 Morocco

<sup>3</sup>Gastroenterology department CHU HASSAN II FEZ 30000 Morocco

### Abstract

Verrucous psoriasis is a rare form of Psoriasis which has a clinical characteristic and histological appearance. Only few cases have been reported in the literature.

We report a rare case of verrucous psoriasis associated with verrucous lichen appeared in a patient with an autoimmune hepatitis.

**Keywords:** Verrucous psoriasis; Verrucous lichen; Autoimmune hepatitis

### Introduction

Psoriasis is a common inflammatory skin disease with a wide range of presentation and a relapsing course. In its typical presentation, it is a scaly erythematous plaque with thick silvery white scale. Verrucous psoriasis is a rare form of psoriasis with a clinical characteristic and histological presentation, it presents as a warty erythematous plaque, with a narrow differential diagnosis with warts [1].

Lichen planus is a cell-mediated immune response of unknown origin. In addition to the cutaneous eruption, it can involve the mucous membranes, nails and scalp. It has various clinical presentations, in which verrucous lichen presents as a hypertrophic plaque mainly in the lower extremities [2].

We report a case of these 2 entities that appeared in a patient suffering from an autoimmune hepatitis.

### Report

A 43 years old woman with a history of an autoimmune hepatitis and psoriasis vulgaris with a relapsing course in the last 15 years treated with dermocorticosteroids, with poor medical follow-ups.

The examination revealed scaly erythematous plaques in the face, trunk and extremities, warty erythematous plaques in the feet, verrucous plaques in the right thigh, fingers and in perianal area, and many pigmented plaques in the legs Figures 1 and 2.

A Skin biopsy of the erythematous scaly lesion showed psoriasis as an epidermal hyperplasia with parakeratosis. In addition, the biopsies of the verrucous lesions made on the thigh, hand and perianal area pointed out a verrucous psoriasis with an epidermal hyperplasia with parakeratosis and prominent papillomatosis Figure 3, while the biopsy of the warty lesion of the leg revealed verrucous lichen as an orthokeratotic hyperkeratosis, papillomatosis with a lymphocytic infiltrate band Figure 4.

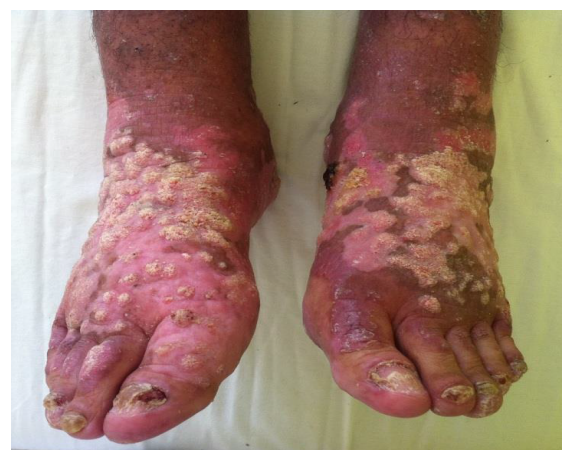Hematological tests reveal an elevated sedimentation rate, liver enzymes, and gamma immunoglobulin. Anti nuclear antibody were positive at 1/320, but the anti SLA antibody, anti LC1, anti endoplasmic reticulum, anti smooth muscle and the hepatitis serology were all negative.

The liver puncture biopsy showed a lymphocytic and plasma cell periportal infiltration that invades the limiting plate Figure 5. The diagnosis of a certain autoimmune hepatitis was made [3].

Our patient was prescribed topical corticosteroids, keratolytics and systemic corticosteroids prednisone at 1 mg/kg/day, without another immunosuppressive treatment due to financial problems. She died few months later.

### Discussion

Verrucous psoriasis is a rare form of Psoriasis; just 20 cases have been reported in the literature. The researches demonstrated that Men



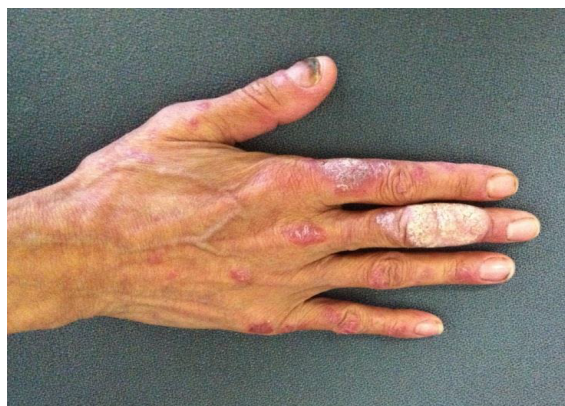**Figure 1:** Warty Erythematous plaques in the feet.

**\*Corresponding author:** Kawtar I, Dermatology Department Chu Hassan II Fez 30000 Morocco, Tel. 00 34 93 521 4100; E-mail: [docteurkawtar@gmail.com](mailto:docteurkawtar@gmail.com)

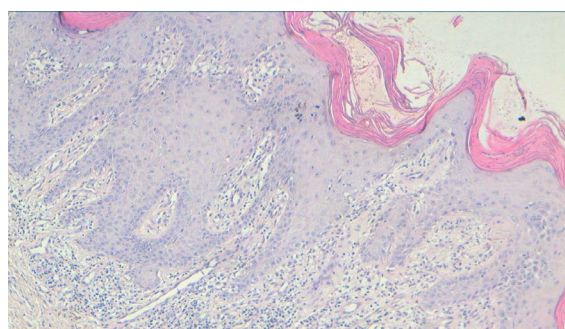
**Received** March 21, 2014; **Accepted** July 17, 2014; **Published** July 25, 2014

**Citation:** Kawtar I, Mariame M, Siham L, Fatimazahra M, Hassania A, et al. (2014) Verrucous Psoriasis and Verrucous Lichen Associated With an Autoimmune Hepatitis. J Clin Diagn Res 2: 107. doi: [10.4172/2376-0311.1000107](https://doi.org/10.4172/2376-0311.1000107)

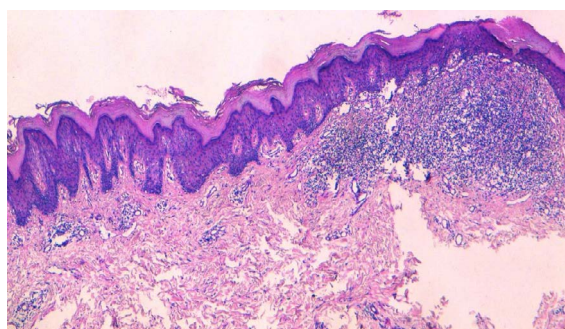
**Copyright:** © 2014 Kawtar I, et al. This is an open-access article distributed under the terms of the Creative Commons Attribution License, which permits unrestricted use, distribution, and reproduction in any medium, provided the original author and source are credited.



**Figure 2:** Erythematous and verrucous plaques at the right hand.



**Figure 3:** Epidermal hyperplasia with parakeratosis and prominent papillomatosis (HES 10X).



**Figure 4:** An orthokeratotic hyperkeratosis, papillomatosis with a lymphocytic infiltrate band (HES 10X).

were affected more than women with a sex ratio of 1.6 and the medium age of 53 years old [4-7].

Verrucous psoriasis has a characteristic scaly erythematous plaque with a verrucous surface. In this respect, histology indicated acanthotic epidermis with parakeratotic hyperkeratosis, an atrophy of the Malpighi mucous body, and Munro's micro abscess associated with an important papillomatosis [1,6,7].

The lesions are localised mainly in the elbows, hands, knees and feet, which are frictions area. This is closely associated with the theory of repeated trauma in the genesis of verrucous lesions. Other etiologies have been reported as predisposing factors for verrucous psoriasis like problems at the lymphatic's circulation, or microangiopathy in

diabetes and obesity. Other authors consider it as a progressive form of vulgaris psoriasis [5-7].

This entity doesn't respond well to local therapy (dermocorticosteroid, vitamine D, puvatherapy), some authors reported the efficacy of etretinate, adalimumab and methotrexate. But it's not a codified therapy because it's a rare form [4-8].

Our patient didn't have predisposing factors for verrucous psoriasis, as a result, we consider it a progressive form of vulgaris psoriasis. On the other hand our patient had atypical localizations, in the right thigh and the perianal area which are not a friction sites.

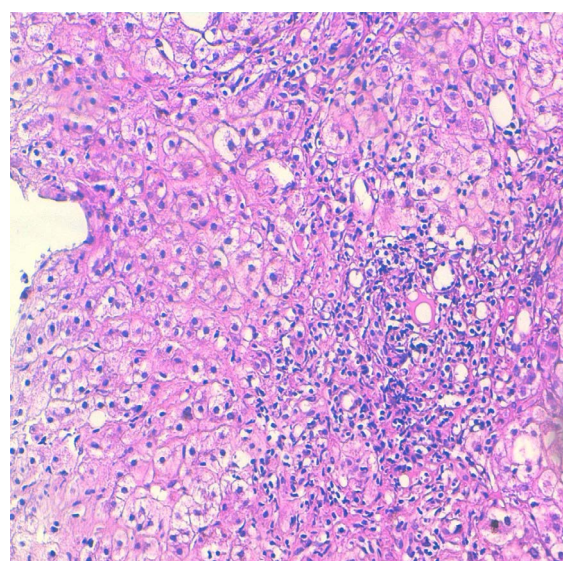
Verrucous lichen is a variant of lichen planus, it presents as a verrucous plaques mainly in the lower extremities with chronic course leaving a residual hyperpigmentation. At the histology we find an acanthosis, papillomatosis, hypergranulosis and an orthokeratotic hyperkeratosis. The choice of a therapeutic agent depends indeed on the extend of lesions, using topical or systemic steroids, puvatherapy, acitretine and cyclosporine with a good outcome [3,4].

The associations that are stated in the literature are as follow: vulgaris psoriasis with lichen sclerosus in one report, and an autoimmune hepatitis with vulgaris psoriasis in two reports [9,10].

Our patient had two dermatologic affections that have a trouble of the keratinisation in common, verrucous psoriasis and hypertrophic lichen; their association has never been reported in the literature. Additionally, our patient had an autoimmune hepatitis; this diagnosis was made on the simplified criteria of the score 2008 of the International Autoimmune Hepatitis Group.

This combination can be explained by the genetic and immunologic predisposition belonging to a mosaic of autoimmunity defining a spectrum of 3 immune diseases [10].

Our case is the first to be reported in the literature, it shows the association of 2 autoimmune diseases with an inflammatory disease: autoimmune hepatitis, verrucous psoriasis, vulgaris psoriasis and verrucous lichen.



**Figure 5:** Periportal infiltration, a lymphocytic and plasma cell that invades the limiting plate (HES 20X).

## Conclusion

We reported a unique case where many autoimmune diseases are present, and which need a multidisciplinary approach.

## References

1. Monroe HR, Hillman JD, Chiu MW (2011) A case of verrucous psoriasis. *Dermatol Online J* 17: 10.
2. Youssef S, Ben Abdallah M, Hanchi I, Dhaoui MR, Jaber K, et al. (2008) Linear verrucous lesions of the trunk and limbs. *Ann Dermatol Venereol* 135: 606-609.
3. Corpechot C, Chazouillères O (2010) Autoimmune hepatitis: diagnostic and therapeutic up-to-date. *Rev Med Interne* 31: 606-614.
4. Curtis AR, Yosipovitch G (2012) Erythrodermic verrucous psoriasis. *J Dermatolog Treat* 23: 215-218.
5. Okuyama R, Tagami H (2006) Psoriasis verrucosa in an obese Japanese man; a prompt clinical response observed with oral etretinate. *J Eur Acad Dermatol Venereol* 20:1359-1361.
6. Wakamatsu K, Naniwa K, Hagiya Y, Ichimiya M, Muto M (2010) Psoriasis verrucosa. *J Dermatol* 37:1060-1062.
7. Khalil FK, Keehn CA, Saeed S, Morgan MB (2005) Verrucous psoriasis: a distinctive clinicopathologic variant of psoriasis. *Am J Dermatopathol* 27: 204-207.
8. Maejima H, Katayama C, Watarai A, Nishiyama H, Katsuoka K (2012) A case of psoriasis verrucosa successfully treated with adalimumab. *J Drugs Dermatol* 11: 74-75.
9. Efe C, Wahlin S, Ozaslan E, Berlot AH, Purnak T, et al. (2012) Autoimmune hepatitis/primary biliary cirrhosis overlap syndrome and associated extrahepatic autoimmune diseases. *Eur J Gastroenterol Hepatol* 24: 531-534.
10. Hsu LN, Armstrong AW (2012) Psoriasis and autoimmune disorders: a review of the literature. *J Am Acad Dermatol* 67: 1076-1079.