

A Rare Cause of Intestinal Perforation in a Patient on Continuous Ambulatory Peritoneal Dialysis Therapy: Abdominal Cocoon Syndrome

Berhan Genç^{1*}, Seyhan Yalaz², Atilla Çökmez², Aynur Solak¹ and Erkan Yılmaz¹

¹Şifa University School of Medicine, Department of Radiology, İzmir, Turkey

²Şifa University School of Medicine, Department of General Surgery, İzmir, Turkey

*Corresponding author: Dr. Berhan Genç, Department of Radiology, Şifa University, İzmir, Turkey Fevzipaşa Boulevard, No: 172/2 Basmane 35240, İzmir/Türkiye, Tel: +90- 232- 4460880/+90-533-5441328; Fax: +902324460770; E-mail: berhangenc@gmail.com

Received date: 3 February, 2014, Accepted date: 21 February, 2014, Published date: 26 February, 2014

Copyright: © 2014 Genç B, et al. This is an open-access article distributed under the terms of the Creative Commons Attribution License, which permits unrestricted use, distribution, and reproduction in any medium, provided the original author(s) and source are credited.

Abstract

Abdominal Cocoon Syndrome (ACS) or sclerosing encapsulating peritonitis is characterized by intestinal obstruction and ileus as a result of encasement of small intestines totally or partially by a thick fibrous sac. We herein present a patient undergoing Continuous Ambulatory Peritoneal Dialysis (CAPD) therapy for chronic renal failure for 3 years who developed intestinal obstruction and perforation and was subsequently diagnosed with abdominal cocoon syndrome. Abdominal cocoon should be remembered in patients on CAPD therapy. One should also be aware that clinical signs of peritonitis may not become evident in the case of intestinal perforation in patients with ACS. In such cases, computed tomography has an important role in making the diagnosis.

Keywords: Abdominal cocoon syndrome; Computed Tomography; Continuous ambulatory peritoneal dialysis

Introduction

Abdominal cocoon or sclerosing encapsulating peritonitis is a rare cause of small intestinal obstruction caused by encasement of small intestines by a thick fibrotic capsule at varying lengths [1-3]. Its exact cause is not known. It has two types as primary and secondary. The primary form is seen in pubertal girls in tropical or subtropical countries. The secondary form is more common than the primary form. Although many factors are held responsible from the secondary form, it is most commonly seen in patients with chronic renal failure undergoing continuous ambulatory peritoneal dialysis (CAPD) treatment [1]. Cessation of CAPD by diagnosing ACS early will prevent further complications associated with this syndrome. An early diagnosis coupled with adequate treatment avoids the need of future surgical therapies including intestinal resection [4,5]. However, the diagnosis of the ACS is challenging owing to its nonspecific symptoms. Computed tomography is beneficial for diagnosis. We herein present a patient undergoing CAPD therapy for chronic renal failure for 3 years who developed intestinal obstruction and perforation and was subsequently diagnosed with ACS.

Case Report

A 52-year-old male patient presented with colic abdominal pain, nausea and vomiting for 1 week. He told that he had similar episodes in the preceding months. He, however, did not receive a specific therapy since his symptoms abated spontaneously. His past history was remarkable for CAPD therapy for chronic renal failure for the last 3 years. However, he began to undergo hemodialysis treatment owing to ineffective CAPD sessions for the past 2 months due to recurrent attacks of peritonitis. He had no history of a previous abdominal surgery. Abdominal examination was notable for upper quadrant pain. His laboratory tests revealed normal electrolytes, a mild anemia,

hypoalbuminemia, and mildly increased C-reactive protein level. BUN and creatinine levels were high, consistent with end-stage renal failure. Abdominal ultrasonography demonstrated cholelithiasis and thickening of the gallbladder wall. Considering the recurrent peritonitis attacks, cholecystectomy was performed from a mini subcostal incision. Gallbladder was severely edematous. Due to diffuse and severe adhesions, abdominal cavity could not be explored. The patient was discharged with full recovery 2 days later. However, he admitted to the hospital 2 days after discharge with abdominal pain, nausea, and vomiting. On physical examination a mild abdominal distention and increased bowel sounds were noted. An abdominal Computed Tomography (CT) with contrast revealed mildly dilated, conglomerated small intestinal loops encased by a membrane as well as moderate amount of ascites surrounding the intestinal loops (Figures 1a and b). Under the light of these findings a provisional diagnosis of abdominal cocoon was made. The patient began to be monitored with the diagnosis of sub-ileus and oral feeding was stopped. At the second hospital day he developed respiratory distress and thoracic and abdominal CTs were obtained, which showed signs of intestinal perforation. An emergency laparotomy was performed. During the operation it was noted that all intestinal segments were encased by a hard fibrous sac. That fibrous structure encased the entire abdominal cavity that contained about five liters intestinal contents and gas (Figures 2a and b). Intestinal contents oozed through a point on the fibrous sac. The sac was opened and all intestinal loops were exposed by resecting some loops. A perforation was noted 15 cm proximal to the ileocecal valve. The ileum was resected for approximately 1 meter and an end ileostomy was performed. The patient developed postoperative sepsis and died 12 days later from multi-organ failure.

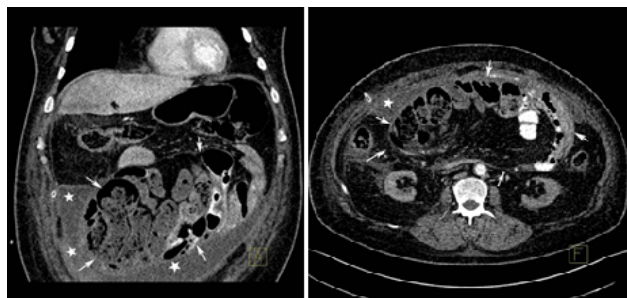


Figure 1a-b: Abdominal coronal (a) and axial (b) maximum intensity projection (MIP) CT images show small intestinal loops encased by a thin fibrous membrane and concentrated to a zone inside a cocoon-like structure (arrows). A fluid collection surrounding the sac is also visible (asterisks). The colonic loops are seen outside the sac.

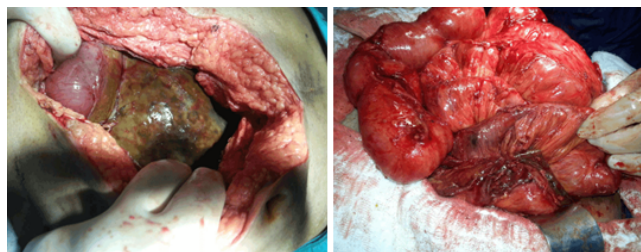


Figure 2a-b: During the operation all small intestinal segments as well as omentum were encased by a thick fibrous membrane (a). Omentum and intestinal loops freed after adhesiolysis (b) are seen.

Discussion

Abdominal cocoon or sclerosing encapsulating peritonitis is a rare condition that was first described by Foo et al. in 1978 [6]. It is characterized by intestinal obstruction and ileus as a result of encasement of small intestines totally or partially by a thick fibrous sac. It is classified as idiopathic and secondary. The former is seen in young women in tropical countries and subclinical peritonitis secondary to retrograde menstruation is considered responsible [7-10]. The secondary form, on the other hand, develops as a result of long term peritoneal dialysis [1,7,8], ventriculoperitoneal shunt [9], long term treatment with beta blockers [7,8], abdominal tuberculosis [10], abdominal surgery [7], liver transplantation [11], systemic lupus erythematosus, gastrointestinal malignancies, and protein S deficiency [12,13]. It has been suggested that the above mentioned conditions lead to fibrosis by causing peritoneal irritation and inflammation.

The clinical features of abdominal cocoon include abdominal pain, nausea, vomiting, weight loss, a non-tender palpable mass lesion, and signs and symptoms of intestinal obstruction. The laboratory findings are nonspecific and may include a mildly elevated white blood cells or C-reactive protein, hypoalbuminemia, and anemia [9].

Majority of cases are incidentally diagnosed during laparotomy performed against obstructive symptoms. A high degree of suspicion is required for preoperative diagnosis of abdominal cocoon syndrome

[14]. Imaging modalities have an important role in the diagnosis; there are well-defined radiological clues that guide diagnostic process. On upright plain abdominal film air-fluid levels may be apparent or it may be totally normal. Barium studies demonstrate dilated, small intestinal loops in addition to a delayed transit time.

Ultrasonography shows dilated intestinal loops, free fluid, and, if thickened enough, a fibrotic membrane encasing intestinal loops. However, it may not be always possible to put the diagnosis with plain film and ultrasonography. CT is considered gold standard for diagnosis of ACS. The classical finding on a CT scan is presence of ascites between small intestinal loops swept to a side or the accumulation of small intestines at midline, which is encased by an envelope having soft-tissue density [9]. Other CT findings include ascites or loculated fluid collections, peritoneal thickening and contrast uptake, peritoneal calcification particularly in patients with end-stage renal disease, intestinal mural thickening, and tethering or fixation of bowel loops. Thanks to coronal and sagittal reformatted images, multidetector CT is superior to helical CT with respect to not only delineation of the disease extent and its indistinct radiologic findings, but also preoperative planning for surgery.

Surgical resection of the membrane and the adhesions is the best treatment option. Recently, cases successfully treated with laparoscopic technique have been reported [14,15]. In mildly symptomatic patients total parenteral nutrition and nasogastric decompression are the treatment modalities of choice. In addition to these, colchicine, corticosteroids, and immunosuppressive agents (mycophenolatemophetyl, azathioprine) may be used in mild disease. Lafrance et al. [15] successfully treated 2 cases with ACS secondary to peritoneal dialysis and Solak A and Solak I [3] one case with primary ACS with mycophenolatemophetyl and corticosteroid.

Our patient also underwent peritoneal dialysis for end-stage renal disease. Therefore, it was considered as a secondary ACS case. Abdominal cocoon syndrome is a rare and late complication of peritoneal dialysis. CAPD is one of the most common causes of secondary ACS. Our case is the first case in which CAPD-induced ACS was diagnosed and spontaneous perforation developed during follow-up. In fact, the possibility of free perforation appears unlikely because intestinal loops are encased by a fibrous membrane. We considered that perforation took place as a result of impaired microcirculation of intestinal loops. Abdominal cocoon syndrome is seen in approximately 1% of patients on CAPD therapy; its prevalence increases with longer treatment duration and at 8th year it may be present in 20% of patients [16]. Its etiology is not exactly known; however, a CAPD duration of more than a several years, type of the dialysate and episodes of bacterial and chemical peritonitis are risk factors for ACS development [17,18]. Timely diagnosis and cessation of CAPD therapy may prevent disease progression and further complications. Nevertheless, abdominal cocoon syndrome may also rarely become manifest after cessation of CAPD. Management of the disease is challenging once it is progressed. Thus, renal replacement therapy may be scheduled at an early period to prevent ACS that may cause serious morbidity and mortality by early diagnosis since the disorder is irreversible. Despite some benefits of immunosuppressive therapy have been reported, acute complications such as small intestinal obstruction can only be managed with surgical technique [19].

Conclusion

Abdominal cocoon should be remembered in patients on CAPD therapy, especially when CAPD loses its functions after recurrent attacks of peritonitis. One should also be aware that clinical signs of peritonitis may not become evident in the case of intestinal perforation in patients with ACS. In such cases, CT has an important role in making the diagnosis.

References

1. Goldstein M, Carrillo M, Ghai S (2013) Continuous ambulatory peritoneal dialysis-a guide to imaging appearances and complications. *Insights Imaging* 4: 85-92.
2. Kirshtein B, Mizrahi S, Sinelnikov I, Lantsberg L (2011) Abdominal cocoon as a rare cause of small bowel obstruction in an elderly man : report of a case and review of the literature. *Indian J Surg* 73: 73-75.
3. Solak A, Solak İ (2012) Abdominal cocoon syndrome: preoperative diagnostic criteria, good clinical outcome with medical treatment and review of the literature. *Turk J Gastroenterol* 23: 776-779.
4. Devay AO, Gomceli I, Korukluoglu B, Kusdemir A (2006) An unusual and difficult diagnosis of intestinal obstruction: the abdominal cocoon. Case report and review of the literature. *World J Emerg Surg* 1: 8.
5. Da Luz MM, Barral SM, Barral CM, Bechara Cde S, Lacerda-Filho A (2011) Idiopathic encapsulating peritonitis: report of two cases. *Surg Today* 41: 1644-1648.
6. Foo KT, Ng KC, Rauff A, Foong WC, Sinniah R (1978) Unusual small intestinal obstruction in adolescent girls: the abdominal cocoon. *Br J Surg* 65: 427-430.
7. Rokade ML, Ruparel M, Agrawal JB (2007) Abdominal cocoon. *J Clin Ultrasound* 35: 204-206.
8. Basu A, Sukumar R, Sistla SC, Jagdish S (2007) "Idiopathic" abdominal cocoon. *Surgery* 141: 277-278.
9. Sigaroudinia MO, Baillie C, Ahmed S, Mallucci C (2008) Sclerosing encapsulating peritonitis: a rare complication of ventriculoperitoneal shunts. *J Pediatr Surg* 43: 31-33.
10. Bani-Hani MG, Al-Nowfal A, Gould S (2009) High jejunal perforation complicating tuberculous abdominal cocoon: a rare presentation in immune-competent male patient. *J Gastrointest Surg* 13: 1373-1375.
11. Maguire D, Srinivasan P, O'Grady J, Rela M, Heaton ND (2001) Sclerosing encapsulating peritonitis after orthotopic liver transplantation. *Am J Surg* 182: 151-154.
12. Tan FL, Loh D, Prabhakaran K (2005) Sclerosing encapsulating peritonitis in a child secondary to peritoneal dialysis. *J Pediatr Surg* 40: e21-e23.
13. Vijayaraghavan SB, Palanivelu C, Sendhilkumar K, Parthasarathi R (2003) Abdominal cocoon: sonographic features. *J Ultrasound Med* 22: 719-721.
14. Hu WM, Han FH, Zhang ZD, Zhou X, Jia W et al. (2007) Diagnosis and surgical treatment of abdominal cocoon: a report of 16 cases. *Zhonghua Wei Chang WaiKeZaZhi* 10: 261-264.
15. Lafrance JP, Létourneau I, Ouimet D, Bonnardeaux A, Leblanc M et al. (2008) Successful treatment of encapsulating peritoneal sclerosis with immunosuppressive therapy. *Am J Kidney Dis* 51: e7-e10.
16. Rigby RJ, Hawley CM (1998) Sclerosing peritonitis: the experience in Australia. *Nephrol Dial Transplant* 13: 154-159.
17. Ti JP, Al-Arabi A, Conlon PJ, Lee MJ, Morrin MM (2010) Imaging features of encapsulating peritoneal sclerosis in continuous ambulatory peritoneal dialysis patients. *AJR Am J Roentgenol* 195: W50-W54.
18. Dobbie JW (1992) Pathogenesis of peritoneal fibrosing syndromes (sclerosing peritonitis) in peritoneal dialysis. *Perit Dial Int* 12: 14-27.
19. Sieck JO, Cowgill R, Larkworthy W (1983) Peritoneal encapsulation and abdominal cocoon. Case reports and a review of the literature. *Gastroenterology* 84: 1597-1601.