

# Multidisciplinary Management of Airway Obstruction and Superior Vena Cava Obstruction Secondary to Huge Retrosternal Goiter

Chen YC<sup>1</sup>, Ikhwan SM<sup>1</sup>, Ziyadi MG<sup>2</sup>, Zaidi Z<sup>1</sup>, Amin NS<sup>3</sup> and Narendran B<sup>1</sup>

<sup>1</sup>Department of Surgery, Universiti Sains Malaysia, Malaysia

<sup>2</sup>Cardiothoracic Surgery Unit, Universiti Sains Malaysia, Malaysia

<sup>3</sup>Department of Surgery, Universiti Malaysia Sabah, Malaysia

## Abstract

Airway obstruction and superior vena cava syndrome (SVC) secondary to huge retrosternal goiter are medical emergencies which need meticulous attention to prevent potentially life threatening events. We reported a case of huge retrosternal goiter which was neglected for years and later complicated by obstruction to airway and superior vena cava. Team effort which mainly involved endocrine surgeon, cardiothoracic surgeon and anaesthetist had successfully removed the gland without significant morbidity. He was on tracheostomy due to tracheomalacia and was managed by ENT surgeon. He was discharged well after 2 weeks.

**Keywords:** Retrosternal goiter; Airway obstruction; Superior vena cava syndrome

## Introduction

Retrosternal goiter is defined as more than 50% of thyroid gland descends in the thorax [1]. Goitres are often idiopathic; however can be caused by the following 1) Iodine deficiency, 2) Goitrogens, 3) Hereditary, 4) Autoimmune diseases and 5) Malignancy [2].

Its progressive extension may lead to compression of the surrounding structures such as trachea, esophagus, nerves and great vessels which leads to disastrous symptoms; dyspnea, dysphagia, hoarseness of voice and facial plethora [3]. An identified retrosternal goiter is an absolute indication for surgery.

Airway obstruction and superior vena cava syndrome (SVC) secondary to huge retrosternal goiter are medical emergencies which need meticulous attention to prevent potentially life threatening events. Airway obstruction results in hypoventilation, difficulty in breathing and impaired gas exchange with development of hypercarbia and ultimately hypoxemia if left untreated. Obstruction resulted from the compression may be partial or complete. Partial obstruction will have more insidious onset whereas complete obstruction will rapidly cause hypoxia and cardiac arrest [4].

SVC syndrome is caused by gradual compression of the SVC, leading to edema and retrograde flow; clinically manifested as cough, dyspnea, dysphagia, and swelling or discoloration of the neck, face and upper extremities. The involvement of collateral venous circulation often causes distension of the superficial veins in the chest wall [5]. Complications such as downhill esophageal varices and exudative pleural effusion tend to occur [6].

## Case Summary

A 61-year-old gentleman, known case of advanced follicular thyroid cancer for 10 years, presented with progressively worsening shortness of breath and altered consciousness associated with fever for 3 days prior to admission. He was ventilated in casualty.

Upon further history from his wife, the anterior neck swelling was progressively increased in size for the past 3 months which was associated with stridor, unable to lie flat during sleep, hot flush and irritability. However there was no pain and difficulty during swallowing as well as no hoarseness of voice. He did not seek for any treatment.

On current examination there was multinodular swelling at anterior neck, firm in consistency with retrosternal extension and presence of dilated vein. He was admitted to ICU and treated as airway and SVC obstruction secondary to huge retrosternal goiter with concurrent severe community acquired pneumonia.

CT scan was done and showed follicular thyroid carcinoma with retrosternal extension with local mass effect and lung metastasis.

Semi emergency Total thyroidectomies with sternotomy were performed after 4 days ICU admission. Intraoperative, there was a huge retrosternal thyroid gland compressing on the right brachiocephalic vein, brachiocephalic trunk from behind the vessel and right carotid artery along with right internal jugular vein. There was presence of hard nodule at isthmus measuring 3cm x 2 cm. Tracheostomy was created due to presence of tracheomalacia (weakening of trachea due to long standing compression).

Postoperatively patient was recovering well and transferred out from ICU at Day 3 post operatively. He was referred to ENT surgeon for vocal cord assessment and tracheostomy was successfully removed at Day 14. He was discharged 2 days later with oral Thyroxine supplement. Histopathological report revealed multinodular goiter with component of left papillary thyroid carcinoma. He was further referred to Oncologist for Radioactive Iodine Therapy.

## Discussion

A multidisciplinary team comprises of surgeons, anesthesiologists, ENT specialists/surgeons, oncologists and pathologists warrants a coordinated team effort in approaching and managing patient with

**\*Corresponding author:** Ikhwanani Mohamad, USM, Kota Bharu, Kelantan Malaysia; E-mail: [ikhwanani@yahoo.com.my](mailto:ikhwanani@yahoo.com.my)

**Received** June 14, 2014; **Accepted** June 24, 2014; **Published** June 30, 2014

**Citation:** Chen YC, Ikhwan SM, Ziyadi MG, Zaidi Z, Amin NS, et al. Multidisciplinary Management of Airway Obstruction and Superior Vena Cava Obstruction Secondary to Huge Retrosternal Goiter. Journal of Surgery [Jurnalul de chirurgie] 2014; 10(2): 191-194 DOI: [10.7438/1584-9341-10-2-18](https://doi.org/10.7438/1584-9341-10-2-18)

**Copyright:** © 2014 Chen YC, et al. This is an open-access article distributed under the terms of the Creative Commons Attribution License, which permits unrestricted use, distribution, and reproduction in any medium, provided the original author and source are credited.

huge retrosternal goiter with compressive symptoms such as airway obstruction and superior vena cava syndrome.

### Surgeons

With multidisciplinary team involvement, the proper diagnosis is ascertained. Surgery is the treatment of choice for retrosternal goiter [7]. Thyroidectomy for retrosternal goiters should be performed by surgeons with a specific interest and experience in thyroid surgery to ensure that complications are minimized [1,8,9].

Multiple studies have revealed that conventional cervical approach; cervical collar incision is best performed, accomplished and successful in the maximum number of cases under experienced hand. The majority of cervicomedial type goiters can be removed through the conventional approach. The operative mortality is negligible and the incidence of complication is reduced by abiding the strict surgical principles [1,7,8,10,11].

Sternotomy should be performed without hesitation when required [7]. Hardy et al. and Singh et al. reviewed only approximately 2% of patients undergoing thyroidectomy for retrosternal goitre will require surgical access other than a standard collar incision; either by manubriotomy, sternotomy or thoracotomy [1,11].

In cases with huge retrosternal goitre extended to below the aortic arch, the cervical approach alone can increase the risks of surgery due to poor access. Therefore, intrathoracic approach should be employed for full access and exposure including manubriotomy, full sternotomy and lateral thoracotomy. Full sternotomy has been proven to be more advantageous over lateral thoracotomy as the incision can be performed quickly and reliably with very low morbidity, providing excellent exposure to the retrosternal portion of the gland without having to reposition the patient. Thus, it is the main choice of approach [9,10,12].

The prognosis was good after resection except for lymphomas [8]. It is undeniable that thyroidectomy carries certain risks of complication such as hemorrhage, laryngeal edema, recurrent laryngeal nerve damage, superior laryngeal nerve damage, tracheomalacia, hypoparathyroidism, pneumothorax and thyroid storm. The associated complications must be kept in mind so the surgeon can carefully evaluate the surgical and medical therapeutic options, have more precise surgical indications and adequate information can be given to patients [13,14].

### Anesthesiologists

The anesthesiologists face numerous daunting tasks in dealing with retrosternal goiter preoperatively, intraoperative and postoperatively. The role of the anesthesiologist, as a part of the interdisciplinary treatment team, is to ensure a safe perioperative period [15].

Airway examination is the foremost preoperative evaluation which needs to be done. It should include assessment of neck movements in all planes (especially atlanto-axial flexion and extension), estimation of thyro-mental distance, any protruding incisors, protruding or retrognathic mandible and Mallampatti grading [16-18]. Classical predictive criteria (mouth opening <35 mm, Mallampatti III or IV, short neck, neck mobility <80 degrees, thyromental distance <65 mm, and a retrognathic mandible) were significantly reliable in the univariate analysis as risk factors for difficult intubation [19].

Large retrosternal goiter extension presents several potential difficulties for anesthetists. The airway management is planned in advanced after a thorough airway examination in order to prevent airways problems during induction of general anesthesia. CT scan of the airway is mandatory as the diameter of the trachea and the site of obstruction must be measured accurately as well as prediction for the need of sternotomy. Furthermore, dynamic airway function studies

enable to assess the functional degree of impairment. Therefore, maximal inspiratory and expiratory flow volume loops will be obtained with the patient in upright and supine positions. Safe and logical technique like awake fiberoptic intubation as an early option for patient with retrosternal goiter will be planned. William's airway has been reported to be superior to the other airways in directing the fiberscope towards the glottis. This will ensure successful endotracheal intubation later [18,20].

Anesthetic management of patients with mediastinal masses such as huge retrosternal goiter remains very challenging as acute intraoperative or postoperative cardiorespiratory decompensation and critical hemodynamic situation might occur that may results in death after induction of general anesthesia [21-23].

The standard of intraoperative management stated by Erdős includes induction of anaesthesia in the operating theatre on an adjustable surgical table, the use of short-acting anaesthetics, avoidance of muscle relaxants and maintenance of spontaneous respiration which is the anesthetic goal whenever possible [15,23].

### ENT specialists/surgeon

Detailed ENT examination should be carried out perioperatively. Indirect laryngoscopy should preferably be carried out by an ENT specialist as 3-5% of population invariably has unilateral paralysis of vocal cords [24].

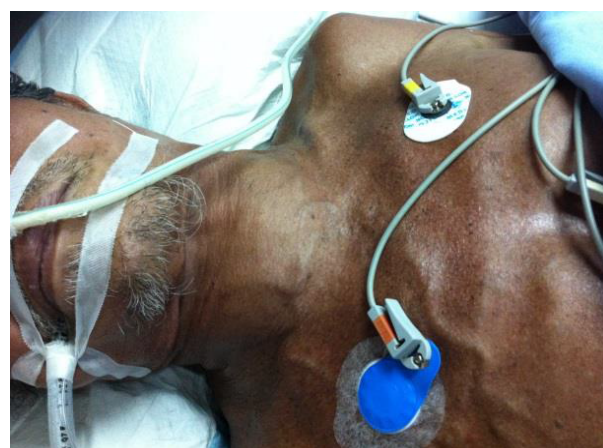The presence of an ENT surgeon in the Operation Theater is also essential as there can be need for establishing a definite surgical airway during the induction period. The presence of a retrosternal goiter, especially being present more than 5 years and causing significant tracheal compression, is likely a risk factor for tracheomalacia and tracheostomy [12,25].

Tracheomalacia can usually be recognized only following extubation [10]. Elective ventilation for few days is carried out if tracheomalacia occurs in these patients. It allows a fibrous connection to develop between the tracheal wall and the surrounding structures hindering its collapse [12,13].

Meticulous approach from ENT specialists/surgeon will avoid preoperative complications and ensure a speedy postoperative recovery of the patients.

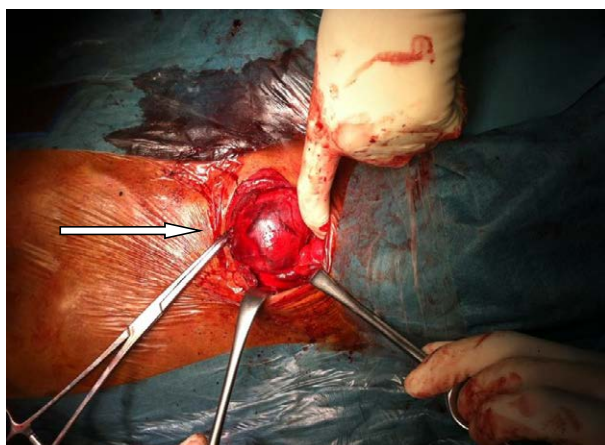
### Radiologists

Imaging specialties are essential in the diagnosis and staging of

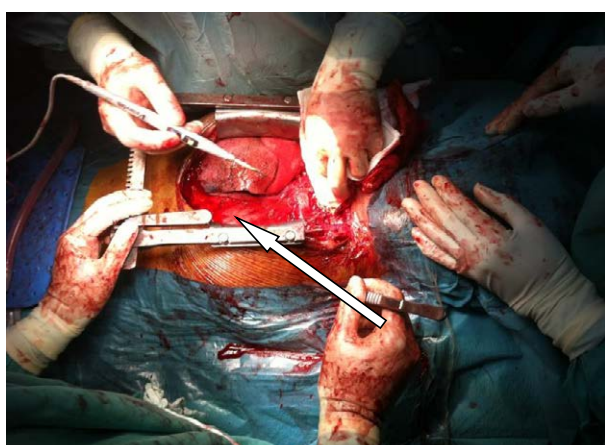

**Figure 1:** Preoperative picture showed huge thyroid swelling with dilated veins (arrow).

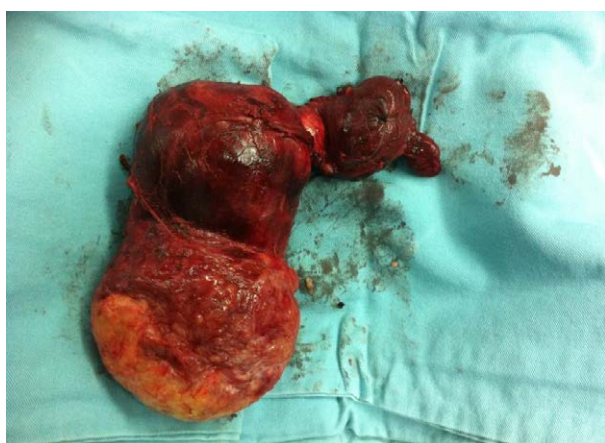



**Figure 2:** Thyroid gland which was first mobilized via collar incision.



**Figure 3:** Sternotomy and mobilization of retrosternal goiter (arrow).



**Figure 4:** Total thyroidectomy specimen.

cancer. They work in hand with oncologists for subsequent detailed management. They would be able to delineate the exact location and extension during preoperative assessment. A written report is thus, mandatory. Although it is commonplace to order standard menus, it is up to the radiologists' discretion for the best techniques in particular problems.

Conventional chest X-ray, tracheal laminography and CT scan provide the most important information for diagnosis purposes.

Thyroid scans and fine-needle aspiration often failed to show the intrathoracic goiter [8,10].

However, CT scan has been said to be the most useful tool showing the nature and extent of the lesion. Cross-sectional images provided by CT or MRI allow good understanding of the complex anatomy of the mediastinum. Thus, CT scan is an important component of the preoperative evaluation and operative planning [12,26-28].

### Oncologists

The medical oncologist should participate in the decisions concerning the choice of therapy. Radioactive iodine (RAI) is used in treatment of patients with differentiated papillary and follicular thyroid cancer. It is typically used after thyroidectomy, both as a means of imaging to detect residual thyroid tissue or metastatic disease, as well as a means of treatment by ablation if such tissue is found. According to NCCN 2012 guidelines, it is indicated in all patients with gross extrathyroidal extension, primary tumor size >4cm, and distant metastases [29].

### Pathologists

The pathologist is arguably an indispensable member of every interdisciplinary team. The pathologist is responsible for giving as definitive a description of the tumor as determined effort can guarantee: its extent, its relationship to surgical margins, and normal structures, and the involvement of lymph nodes, lymphatics, and blood vessels.

### Conclusion

Multidisciplinary management is essentially crucial to deliver comprehensive healthcare and provide the best possible outcome for the physical and psychosocial needs of a patient and their caregivers. The medical professionals from a range of disciplines with complementary skills, knowledge and experiences work in unity alongside with patients as the center of care in order to meet their needs and improve their quality of life.

### Conflict of interest

The authors have no conflict of interest to report.

### References

- Hardy RG, Bliss RD, Lennard TWJ (2009) Retrosternal Goitre: The Case for Operation in All Patients. *Ann R Coll Surg Engl*: 8–11.
- Hughes K, Eastman C (2012) Goitre - causes, investigation and management. *Aust Fam Physician* 41: 572-576.
- Anders HJ (1998) Compression syndromes caused by substernal goitres. *Postgrad Med J* 74: 327-329.
- McPherson K, Stephens RC (2012) Managing airway obstruction. *Br J Hosp Med (Lond)* 73: C156-160.
- Higdon ML, Higdon JA (2006) Treatment of oncologic emergencies. *Am Fam Physician* 74: 1873-1880.
- Rice TW (2007) Pleural effusions in superior vena cava syndrome: prevalence, characteristics, and proposed pathophysiology. *Curr Opin Pulm Med* 13: 324-327.
- Tărcoveanu E, Vasilescu A, Vlad N, Niculescu D, Cotea E, et al. (2012) Retrosternal goiters. *Rev Med Chir Soc Med Nat Iasi* 116: 523-531.
- Sanders LE, Rossi RL, Shahian DM, Williamson WA (1992) Mediastinal goiters. The need for an aggressive approach. *Arch Surg* 127: 609-613.
- Sand ME, Laws HL, McElvein RB (1983) Substernal and intrathoracic goiter. Reconsideration of surgical approach. *Am Surg* 49: 196-202.
- Vadasz P, Kotsis L (1998) Surgical aspects of 175 mediastinal goiters. *Eur J Cardiothorac Surg* 14: 393-397.
- Singh B, Lucente FE, Shaha AR (1994) Substernal goiter: a clinical review. *Am J Otolaryngol* 15: 409-416.
- Khairy G, Alsaif A (2010) Large Retrosternal Goitre: A Diagnostic and Treatment Dilemma. *OMJ*: 25.

13. Bajwa SJ, Sehgal V (2013) Anesthesia and thyroid surgery: The never ending challenges. *Indian J Endocrinol Metab* 17: 228-234.
14. Rosato L, Avenia N, Bernante P, De Palma M, Gulino G, et al. (2004) Complications of thyroid surgery: analysis of a multicentric study on 14,934 patients operated on in Italy over 5 years. *World J Surg* 28: 271-276.
15. Erdős G, Tzanova I (2009) Perioperative anaesthetic management of mediastinal mass in adults. *Eur J Anaesthesiol* 26: 627-632.
16. Bouaggad A, Nejmi SE, Bouderkha MA, Abbassi O (2004) Prediction of difficult tracheal intubation in thyroid surgery. *Anesth Analg* 99: 603-606.
17. Mallampati SR, Gatt SP, Gugino LD, Desai SP, Waraksa B, et al. (1985) A clinical sign to predict difficult tracheal intubation: a prospective study. *Can Anaesth Soc J* 32: 429-434.
18. Gothard JW (2008) Anesthetic considerations for patients with anterior mediastinal masses. *Anesthesiol Clin* 26: 305-314.
19. Amathieu R, Smail N, Catineau J, Poloujadoff MP, Samii K, et al. (2006) Difficult intubation in thyroid surgery: myth or reality? *Anesth Analg* 103: 965-968.
20. Thallage A, Al-Zahrani T (2004) Anesthetic Management of Huge Goiter with Retrosternal Extension. *The Internet Journal of Anesthesiology*.
21. Choi WJ, Kim YH, Mok JM, Choi SI, Kim HS (2010) Patient repositioning and the amelioration of airway obstruction by an anterior mediastinal tumor during general anesthesia -A case report-. *Korean J Anesthesiol* 59: 206-209.
22. Tan PC, Esa N (2012) Anesthesia for massive retrosternal goiter with severe intrathoracic tracheal narrowing: the challenges imposed -A case report-. *Korean J Anesthesiol* 62: 474-478.
23. Slinger P, Karsli C (2007) Management of the patient with a large anterior mediastinal mass: recurring myths. *Curr Opin Anaesthesiol* 20: 1-3.
24. Chin SC, Edelstein S, Chen CY, Som PM (2003) Using CT to localize side and level of vocal cord paralysis. *AJR Am J Roentgenol* 180: 1165-1170.
25. White ML, Doherty GM, Gauger PG (2008) Evidence-based surgical management of substernal goiter. *World J Surg* 32: 1285-1300.
26. Ben Nun A, Soudack M, Best LA (2006) Retrosternal thyroid goiter: 15 years experience. *Isr Med Assoc J* 8: 106-109.
27. Grainger J, Saravanappa N, D'Souza A, Wilcock D, Wilson PS (2005) The surgical approach to retrosternal goiters: the role of computerized tomography. *Otolaryngol Head Neck Surg* 132: 849-851.
28. Shaham D, Skilakaki MG, Goitein O (2004) Imaging of the mediastinum: applications for thoracic surgery. *Thorac Surg Clin* 14: 25-42.
29. Carballo M, Quiros RM (2012) To treat or not to treat: the role of adjuvant radioiodine therapy in thyroid cancer patients. *J Oncol* 2012: 707156.