

Plasma Cell Mastitis-Anatomo-Clinical and Therapeutic Considerations

Roxana Maria Livadariu¹, Radu Danilă^{1*}, Daniel Timofte¹, Delia Ciobanu² and Corneliu Diaconu¹

¹Department of Surgery, 3rd Surgical Unit, "St. Spiridon" Hospital, Iași, University of Medicine and Pharmacy "Gr.T. Popa" Iași, Romania

²Department of Pathology, "St. Spiridon" Hospital, Iași, University of Medicine and Pharmacy "Gr.T. Popa" Iași, Romania

Abstract

Plasma cell mastitis is a rare chronic inflammatory disease of the breast. Its cause and treatment have not yet been clearly identified. The aim of the study is to present the author's experience with various treatment methods applied on this disease. **MATERIAL AND METHODS:** We retrospectively analyzed the clinical findings, biological tests, imaging results, therapeutic approach and the pathological response from 25 patients diagnosed with plasma cells mastitis between 2005 and 2013. **RESULTS:** Only 7 cases underwent from the beginning to wide surgical excision of the inflammatory mass with favorable evolution. The rest of the patients, treated with antibiotherapy, corticotherapy or surgical drainage of the collections (when needed) presented early relapse that required surgical treatment: large excision to subcutaneous mastectomy. **CONCLUSIONS:** Surgical treatment represented by wide excision going up to subcutaneous mastectomy is the most effective therapeutic method for this benign, but with high relapsing potential, disease. It also has the advantage of giving a more accurate positive and differential diagnosis, most important with breast carcinoma.

Keywords: Plasma cells mastitis; Granulomatous mastitis

Introduction

Also known in literature as granulomatous lobular mastitis, plasma cell mastitis is a rare chronic inflammatory disease of the breast. It is a non-infectious, non-neoplastic mastitis, not occurring during the post-partum and breastfeeding period [1]. Its etiology is unknown and controversial. There are two theories regarding the etiology of granulomatous mastitis: autoimmune and hypersensitivity processes versus an infectious pathogenesis. Although the majority of cases of plasma cells mastitis appear aseptic, case reports of documented coinfection with *Corynebacterium sp.* have been reported in the United Kingdom, France and Italy [2,3]. It commonly presents with the clinical symptoms of inflammation, breast mass, breast indurations, erythema, "peau d'orange", ulcerative lesions, and even cutaneous fistulae with pus discharge. Most of the patients develop recurrences and many other develop complications such as abscess formation and fistulae. Histopathological examination is the most definitive method of diagnosis and makes it possible to differentiate granulomatous mastitis from breast cancer, other granulomatous diseases and infectious etiologies. There is no agreement about the most appropriate treatment approach for these patients, although surgical excision and corticosteroid therapy have been recently shown to be effective for the disease.

The aim of the study was to review the clinical and diagnostic features of the disease and to discuss the results of medical and surgical treatment in a series of 25 patients with granulomatous mastitis.

Material and Methods

We retrospectively evaluated the clinical findings, biological tests, imaging results, therapeutic applied methods and postoperative evolution of 25 patients diagnosed, treated and followed by the same surgical team between 2005 and 2013.

Results

The age of the patients ranged from 29 to 39 years old, with a median of 34 years old, time of last childbirth ranged from 2 to 7 years; all of the patients have history of breastfeeding. We did not detect any history of using contraceptive medication, smoking, trauma of

the breast, sarcoidosis, tuberculosis or other infectious diseases. On admission, 16% of the patients (n= 4) presented breast painful tumor mass, other 16% (n= 4), breast mass and abscess of the mammary gland, 64% (n=16) had multiple abscesses and fistulae of the breast and 4% (n= 1) presented multiple abscesses accompanied by neurological symptoms and peripheral vasculitis. In all cases the lesions were unilateral, occurring in any quadrant of the breast.

The ultrasound exam revealed the presence of intraglandular collection, some with important modification (retraction) of the surrounding glandular tissue. The blood tests showed leukocytosis (with a median of 12,000/mm³) and increased values of C reactive protein (CRP), median value of 5.2 mg/L. The chest X-rays were normal in all cases.

The initial surgery consisted in wide surgical excision of the inflammatory mass in 7 cases (28%), with favorable local outcome and no recurrence (Table I). The rest of the patients refused the initial radical approach and drainage of the intraglandular collections associated with antibiotherapy was performed. All of these 18 last patients (72%) presented early relapse (from 1 to 9 months) with intraglandular abscesses that required surgical treatment: subcutaneous mastectomy in 28% (5 cases) and large excisions of the inflammatory tissue in 66.6% (12 cases) (Table II). The postoperative recovery was uneventful with satisfactory healing of surgical wound.

A particular difficult evolution was noticed in one patient that, following the initial drainage of collections, presented recurrent abscesses despite antibiotherapy and corticotherapy; these local

***Corresponding author:** Radu Dănilă MD, PhD, 3rd Surgical Unit, "St. Spiridon" Hospital, 700111, Bd. Independenței, No 1, Iași, Romania, Tel: +40 (0) 232 24 08 22; Fax: +40 (0) 232 24 08 22; E-mail: r_danila@yahoo.com

Received March 13, 2014; **Accepted** March 27, 2014; **Published** September 20, 2014

How to cite: Livadariu RM, Danilă R, Timofte D, Ciobanu D, Diaconu C. Plasma Cell Mastitis - Anatomo-Clinical and Therapeutic Considerations. Journal of Surgery [Jurnalul de chirurgie] 2014; 10(2): 141-143 DOI: [10.7438/1584-9341-10-2-7](https://doi.org/10.7438/1584-9341-10-2-7)

Copyright: © 2014 Livadariu RM, et al. This is an open-access article distributed under the terms of the Creative Commons Attribution License, which permits unrestricted use, distribution, and reproduction in any medium, provided the original author and source are credited.

Table I: Patients who underwent initial surgical excision.

	Age	Symptoms	Biologic tests	Ultrasound	Treatment	Follow-up
1.	28	Pain, local mass, fistulae	WBC=16,000/mm ³ CRP=5.2 mg/L	Multiple abscesses, glandular mass in the same quadrant	Quadraneotomy ATB	Favorable, no relapse
2.	31	Induration, multiple fistulae	WBC=14,000/mm ³ CRP=6 mg/L	Intraglandular abscesses, same quadrant	Large excision - Biquadraneotomy ATB	Favorable, no relapse
3.	32	Induration, multiple masses	WBC=14,200/mm ³ CRP=6.3mg/L	Multiple abscesses, same quadrant	Large excision - Biquadraneotomy ATB	Favorable, no relapse
4.	34	Pain, erythema, mass, fistulae	WBC=11,500/mm ³ CRP=4.1mg/L	Intraglandular mass and abscess, same quadrant	Sectorectomy ATB	Favorable, no relapse
5.	34	Pain, erythema, fever, extended induration	WBC=13,200/mm ³ CRP=4.8mg/L	Multiple abscesses, same quadrant	Quadraneotomy ATB	Favorable, no relapse
6.	35	Erythema, multiple fistulae	WBC=11,000/mm ³ CRP=4.1mg/L	Multiple abscesses	Quadraneotomy ATB	Favorable, no relapse
7.	38	Induration, painful tumor mass	WBC=11,600/mm ³ CRP=3.8mg/L	Intraglandular mass, important tissue retraction	Sectorectomy ATB	Favorable, no relapse

WBC White Blood Cells; CRP C reactive proteins; ATB Antibiotherapy

Table II: Patients who underwent initial conservative treatment.

	Age	Symptoms	Biologic tests	Ultrasound	Initial treatment	Follow-up	Final treatment
1.	29	Induration, mass	WBC=11,600/mm ³ CRP=5.6mg/L	Glandular mass, tissue retraction-	ATB; AINS	Relapse after 2 & 4 months	1. Antibiotics 2. Quadraneotomy
2.	29	Induration, mass	WBC=12,200/ mm ³ CRP=4.5mg/L	Abscesses, mass – same quadrant	Drainage; ATB; AINS	Relapse after 9 months	Quadraneotomy
3.	30	Mass, fistulae	WBC=14,200/mm ³ CRP=5.9mg/L	Multiple abscesses, glandular mass – same quadrant	Drainage; ATB; AINS	Relapse after 6 months	Quadraneotomy
4.	31	Pain, mass	WBC=12,100/mm ³ CRP=0.8mg/L	Tissue retraction, glandular mass – same quadrant	ATB; AINS	Relapse after 1 month	Quadraneotomy
5.	31	Erythema, mass	WBC=10,400/mm ³ CRP=4.4mg/L	Multiple abscesses, glandular mass – same quadrant	Drainage; ATB; AINS	Relapse after 4, 6 & 9 months	1. Antibiotics 2. Drainage 3. Subcutaneous mastectomy
6.	32	Mass, fistulae	WBC=13,000/mm ³ CRP=5.6mg/L	Multiple abscesses, glandular mass – same quadrant	Drainage; ATB; AINS	Relapse after 3 months	Quadraneotomy
7.	33	Multiple masses	WBC=11,600/mm ³ CRP=3.8mg/L	Multiple abscesses, glandular mass – same quadrant	Drainage; ATB; AINS	Relapse after 7 months	Subcutaneous mastectomy
8.	34	Pain, mass, erythema	WBC=10,800/mm ³ CRP=4.4mg/L	Abscess, glandular mass-	ATB; AINS	Relapse after 3 months	Quadraneotomy
9.	34	Mass, erythema	WBC=11,400/mm ³ CRP=5.1mg/L	Multiple abscesses, glandular mass – same quadrant	Drainage; ATB; AINS	Relapse after 3 months	Subcutaneous mastectomy
10.	35	Mass, fistulae	WBC=10,400/mm ³ CRP=4.8mg/L	Important tissue retraction, mass	Drainage; ATB; AINS	Relapse after 2 months	Quadraneotomy
11.	36	Mass, local adenopathy	WBC=12,200/mm ³ CRP=6mg/L	Multiple abscesses, glandular mass – same quadrant	ATB; AINS	Relapse after 1 month	Quadraneotomy
12.	37	Mass, fistulae	WBC=12,800/mm ³ CRP=5.3mg/L	Profound abscess	Drainage; ATB; AINS	Relapse after 4 months	Quadraneotomy
13.	37	Induration, multiple fistulae	WBC=14,400/mm ³ CRP=5.2mg/L	Multiple abscesses, glandular mass – same quadrant	Drainage; ATB; AINS; AIS	Relapse after 5 months	Subcutaneous mastectomy
14.	37	Mass, pain	WBC=11,100/mm ³ CRP=5.3mg/L	Small abscess, glandular mass – same quadrant	ATB; AINS	Relapse after 8 months	Quadraneotomy
15.	38	Mass, pain	WBC=10,800/mm ³ CRP=4.8mg/L	Glandular mass, tissue retraction-	ATB; AINS	Relapse after 2 & 6 months	1. Drainage 2. Biquadraneotomy
16.	38	Induration, fistulae	WBC=12,000/mm ³ CRP=5.1mg/L	Multiple abscesses, glandular mass – same quadrant	Drainage; ATB; AINS	Relapse after 4 months	Subcutaneous mastectomy
17.	39	Mass, fistulae	WBC=13,300/mm ³ CRP=6.3mg/L	Multiple abscesses, glandular mass – same quadrant	Drainage; ATB; AINS	Relapse after 3 months	Biquadraneotomy
18.	39	Abscesses, fever, neurologic symptoms	WBC=39,800/mm ³ CRP=9.6mg/L	Multiple abscesses, glandular mass – same quadrant	Drainage; ATB; AINS; AIS	Multiple relapse within 21 days, despite therapy	Subcutaneous mastectomy

modifications were accompanied by high fever (up to 40 Celsius degrees), frequent and persistent chills, neurologic symptoms such as violent headaches during fever access and peripheral symptoms - vasculitis (Figure 1). The blood cultures were negative and she presented high values of leukocytes (up to 40,000/mm³) with no identification of other infection source. Suspecting cerebrovascular thrombosis by septic micro embolus, we performed a cerebral CT that did not reveal any cerebral modifications. After a prolonged hospital stay during which she underwent for several surgical procedures consisting of multiple drainage of the intraglandular collections and

multiple associations of antibiotics with corticotherapy, when the general status allowed, we performed a subcutaneous mastectomy. Within 6 days, the recovery of the patient was perfect with no sign of infection, neurological or peripheral symptoms. The pathological exam of the resected specimen showed multiple abscesses of different sizes, surrounded by inflammatory sclerosis tissue (Figure 2). Histopathology revealed suggestive aspects for chronic inflammation, presence of multiple granulomatous lesions with a centrilobular distribution and the destruction of the glandular architecture. The granulomatous masses contained epithelioid hystiocytes, giant cells, central infiltration

of neutrophils and eosinophils, and surrounding lymphocytes and plasma cells (Figure 3). The bacterial, fungal and *Mycobacterium* cultures of the intraoperative specimen were negative.

Discussion

Idiopathic granulomatous mastitis is a rare inflammatory disease of the breast whose etiology and treatment have not yet been clearly identified despite the efforts of many researchers. The treatment methods known to date include observation, antibiotics, steroids, drainage, excision, and mastectomy, but an optimal treatment method still needs to be determined [5-7]. In this study, various treatment methods were applied based on the medical conditions of the patients and on the stage of the lesions.

It has been reported that plasma cells mastitis is a self-limiting condition and can be expected to disappear on its own within 6-12 months with close surveillance [8]. We have not experienced this on our patients. Although steroid treatment was not effective in this study, many studies have reported the importance and effectiveness of steroids on granulomatous mastitis treatment [9].

The drainage method is also still controversial in treating this disease because the incision wound does not heal easily and can leave a fistula tract, and treatment can last for an extended time. In our study, all the patients that underwent at the beginning with surgical drainage associated with antibiotics and/or corticotherapy presented long lasting treatment of the wound and early relapse. All the patients who underwent surgical excision as an initial treatment recovered faster, with an average recovery period of 6 days compared to the recovery periods for the other treatment methods that came up to 21 days.

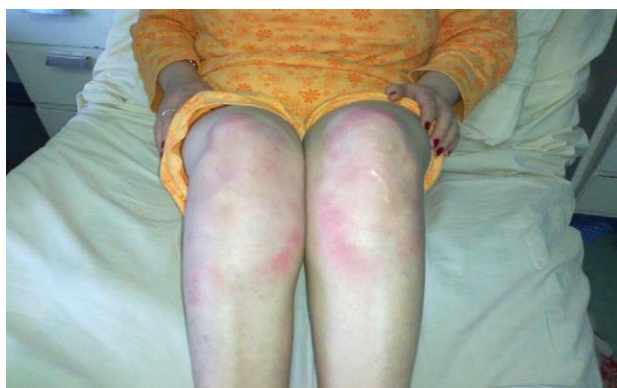

Figure 1: Peripheral vasculitis.

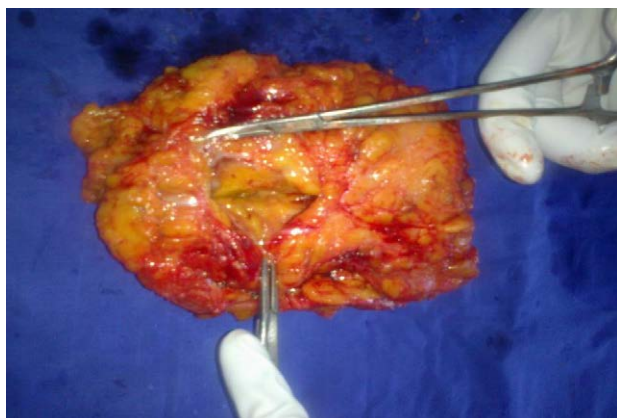

Figure 2: Macroscopic image in granulomatous mastitis; presence of abscess.

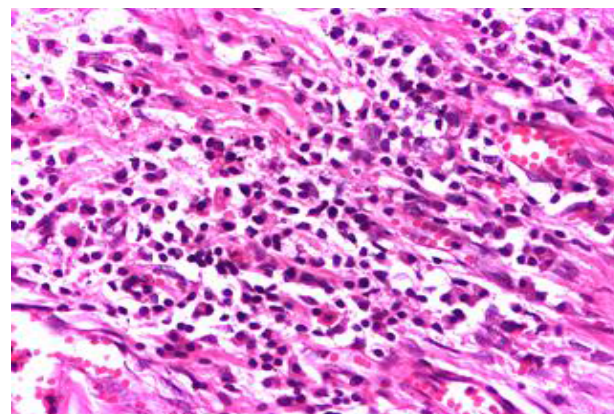


Figure 3: Microscopic image in plasma cell mastitis: inflammatory infiltrate with numerous plasma cells.

Conclusions

We consider that surgical excision as an initial treatment is the most effective therapeutic method for this benign but with high relapsing potential disease. Surgical excision of affected and surrounding normal tissue as well showed particularly fast recovery and a high success rate. It also has the advantage of giving a more accurate positive and differential diagnosis, most important with breast carcinoma, of plasma cells mastitis.

Conflict of Interests

Authors have no conflict of interests to disclose.

References

1. Tournant B (1995) [Lymphocytic plasma cell mastitis]. See comment in PubMed Commons below Arch Anat Cytol Pathol 43: 88-92.
2. Ang LM, Brown H (2007) *Corynebacterium accolens* isolated from breast abscess: possible association with granulomatous mastitis. See comment in PubMed Commons below J Clin Microbiol 45: 1666-1668.
3. Binelli C, Lorimier G, Bertrand G, Parvery F, Bertrand AF, et al. (1996) [Granulomatous mastitis and corynebacteria infection. Two case reports]. See comment in PubMed Commons below J Gynecol Obstet Biol Reprod (Paris) 25: 27-32.
4. Al-Jarrah A, Taranikanti V, Lakhtakia R, Al-Jabri A, Sawhney S (2013) Idiopathic Granulomatous Mastitis: Diagnostic strategy and therapeutic implications in Omani patients. See comment in PubMed Commons below Sultan Qaboos Univ Med J 13: 241-247.
5. Going JJ, Anderson TJ, Wilkinson S, Chetty U (1987) Granulomatous lobular mastitis. See comment in PubMed Commons below J Clin Pathol 40: 535-540.
6. Heer R, Shrimankar J, Griffith CD (2003) Granulomatous mastitis can mimic breast cancer on clinical, radiological or cytological examination: a cautionary tale. See comment in PubMed Commons below Breast 12: 283-286.
7. Wilson JP, Massoll N, Marshall J, Foss RM, Copeland EM, et al. (2007) Idiopathic granulomatous mastitis: in search of a therapeutic paradigm. See comment in PubMed Commons below Am Surg 73: 798-802.
8. Lai EC, Chan WC, Ma TK, Tang AP, Poon CS, et al. (2005) The role of conservative treatment in idiopathic granulomatous mastitis. See comment in PubMed Commons below Breast J 11: 454-456.
9. Hovanessian Larsen LJ, Peyvandi B, Klipfel N, Grant E, Iyengar G (2009) Granulomatous lobular mastitis: imaging, diagnosis, and treatment. See comment in PubMed Commons below AJR Am J Roentgenol 193: 574-581.