

A Case of Inflammatory Reduction with Ozone Treatment of Disc Herniation and Histological Changes

Dario Apuzzo¹, Paolo Ferrazza^{2*}, Marchilia Piscitelli² and Ergena Melengu²

¹Centro Recovery and Functional Rehabilitation, "SALUTE OK" Rome, Italy

²Centro Clinical Research LNage S.r.l, Link Neuroscience and Health Care, Rome, Italy

Corresponding author: Paolo Ferrazza, Centro Clinical Research LNage S.r.l, Link Neuroscience and Health Care, Via Luigi Rizzo, 62, 00136 Rome, Italy, E-mail: paolo.ferrazza@lnage.it

Rec Date: Mar 08, 2016; **Acc Date:** Apr 21, 2016; **Pub Date:** Apr 29, 2016

Copyright: © 2016 Apuzzo D, et al. This is an open-access article distributed under the terms of the Creative Commons Attribution License, which permits unrestricted use, distribution, and reproduction in any medium, provided the original author and source are credited.

Abstract

Objectives: Ozone therapy can stop pain caused by the intervertebral disc degeneration, associated with an extrusion of nucleus pulposus that cause inflammatory changes.

Materials and methods: Bilateral intramuscular O₂O₃ infiltrations, injected on the disk lesion site with a paravertebral approach. An Oxygen-Ozone mixture at a rate of 20 µg/ml was obtained by means of an Ozone generator.

Results: The loss of matrix components of nucleus pulposus herniation causes pain due to stimulation of inflammation and not caused by mechanical nerve pressure.

Conclusion: The action of oxygen-ozone is the regeneration of the annulus fibrosus of disc herniation and reduction of inflammatory chain generation. It is also confirmed by the persistence of the mechanical pressure on the nerve but the inflammatory and pain symptoms have disappeared.

Keywords: Collagen; Hernia; Ozone; Back pain

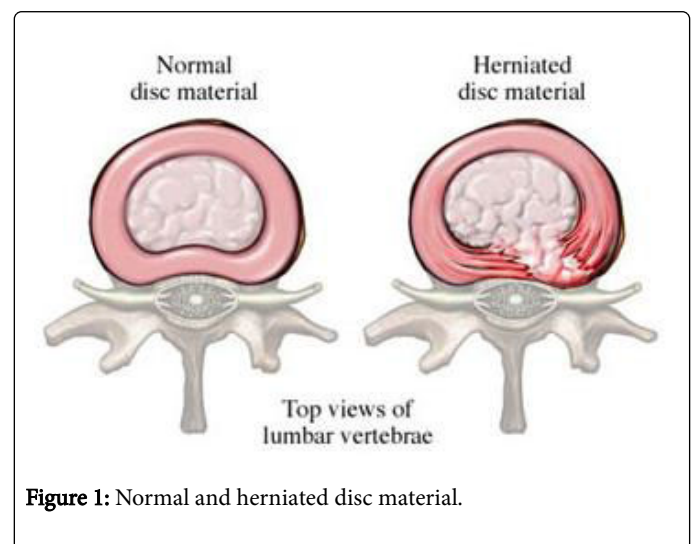
Introduction

The intervertebral disc is a hydrodynamic system deputed for absorption of shock and anatomically composed of three parts, the fibrous ring, the nucleus pulposus and the articular cartilage. The first two zones allow the disc to function as a shock absorber and to resist the forces of traction and torsion. For that purpose, the nucleus pulposus, included in the annulus fibrosus, consists of a high concentration of water, proteoglycans and collagen.

The migration of the nucleus pulposus through the fibers of the annulus and its eventual migration outside, causes herniated disc and involve a mechanical compression of neural structures. An inflammatory reaction with release of various biochemical factors (prostaglandins, leukotrienes, etc...) is supposed to be associated with this pathology.

The displacement of the disc material can happen at the center or, more commonly, laterally. Lateral disc herniation is a common cause of sciatica with leg pain (lumbar radiculopathy). Lumbar disc herniation most commonly is located between the fourth and fifth lumbar vertebrae, and between the fifth lumbar and first sacral vertebrae. These levels are also called L4/L5 and L5/S1 and are considered to constitute more than 90% of lumbar disc herniation (Figure 1) [1].

Many studies have suggested the possibility that the pain is mainly due to an inflammatory reaction by extrusion of the nucleus pulposus and not by mechanical compression on the nerve. Ozone has both the ability to act on the transformation of the herniated nucleus and to block the pro-inflammatory factors.



Case Report

On October 2009, a Caucasian woman of 44 years, reports right lumbosciatica. Physical examination detects the VAS 7/10, discrete motor deficits (the patient cannot stand on the tip of the right foot) and the absence of Achilles and right plantar reflex. Spinal MRI shows extruded right hernia L5-S1, with compression on the S1 root.

The patient decides to submit to a cycle of Oxygen-ozone therapy, including 12 intramuscular paravertebral infiltrations L5/S1, with bi-weekly frequency, of gaseous oxygen-ozone mixture with a

concentration of 20 µg/ml as this is the typical indication for ozone therapy. The therapy, however, gave rise to a moderate remission of pain but not of the motor deficit, so decided for neurosurgical advice and is given indication for surgical treatment.

The surgery resolved the symptoms and the patient were discharged on the third day without motor deficits. During the intervention fragments of the L5-S1 disc were collected and were examined histologically to study of the structure of collagen fibers by the Laboratory of University "Sapienza" of Rome.

Discussion

The therapeutic approach to the clinical syndrome caused by slipped disc has been widely debated as well as the possible complications that can arise from the use of various therapeutic techniques. The therapeutic efficacy of oxygen-ozone therapy in the treatment of disk-root conflicts from herniated discs has been known for several years [2,3]. Our clinical experience investigated, in this case report, the histological changes that took place in the herniated disc tissue, after a cycle of oxygen ozone therapy. The histological evaluation of the intervertebral disc tissue after treatment shows the absence of inflammatory reaction, the loss of water and the proteoglycans associated with an increase of collagen fibers.

Some authors suggest that the success of the oxygen-ozone therapy in the treatment of herniated discs is attributable to action decompressed action of ozone, in fact, the dehydration of herniated nucleus pulposus or compressing of the bundles of annulus fibrosus would reduce the pressure on the nerve roots and bone. Slight modifications of the volume of the rigid vertebral canal are able to generate significant modifications of pressure. Total absence of inflammatory findings during histological examination confirms how the inflammatory reaction that is created between the nucleus pulposus and the nerve root could be effectively neutralized by ozone that has proven ability to regulate the pro-inflammatory cascade. A lot of studies [4,5] show that ozone has a strong healing action and pro-fibrotic, and therefore, a progressive fibrotic action on the hernia, highlighted by the histological analysis. This treatment may restrict or block production of pro-inflammatory substances from the hernia itself on the one hand and on the other to form a mechanical reinforcement avoiding herniation of the "nuclear" material that still remained non-fibrotic.

Comparing the histological changes of the oxygen-ozone treated hernia to another one normally treated, it confirms fibrotic change of

nucleus pulposus treated with oxygen-ozone without reduction of volume. Never the less these patients showed a significant remission of symptoms. The action of oxygen-ozone is performed in a major development of fibrous tissue of disc herniation. This would prevent the production of pro-inflammatory substances by the hernia itself, thus explaining the disappearance of the painful symptoms in the absence of volumetric reduction of the hernia.

Therefore, the now consolidated model of cause of pain due to nerve root compression should be revised.

Learning points

The intervertebral disc supports movements and impacts of the body and the displacement of the disc material causes an inflammatory reaction.

Herniated disc material involves a mechanical compression of neural structures inducing motor deficits.

Oxygen-ozone therapy restricts production of pro-inflammatory substances from the hernia, which is the responsible for the painful symptoms and restricted body movement.

References

1. Paoloni M, Sante LD, Cacchio A, Apuzzo D, Marotta S, et al. (2009) Intramuscular oxygen-ozone therapy in the treatment of acute back pain with lumbar disc herniation: A multicenter, Randomized, Double-blind, clinical trial of active and simulated lumbar paravertebral injection. *Spine* 34: 1337-1344.
2. Muto M, Andreula C, Leonardi M (2004) Treatment of herniated lumbar disc by intradiscal and intraforaminal oxygen-ozone (O₂-O₃) injection. *J Neuroradiol* 31: 183-189.
3. Andreula CF, Simonetti L, Santis FD, Agati R, Ricci R, et al. (2003) Minimally invasive oxygen-ozone therapy for lumbar disc herniation. *AJNR Am J Neuroradiol* 24: 996-1000.
4. Magalhaes FN, Dotta L, Sasse A, Teixeira MJ, Fonoff ET (2012) Ozone therapy as a treatment for low back pain secondary to herniated disc: A systematic review and meta-analysis of randomized controlled trials. *Pain Physician* 15: 115-129.
5. Movaghar VR, Eslami V (2012) The major efficient mechanisms of ozone therapy are obtained in intradiscal procedures. *Pain Physician* 15: 1007-1008.