

A Holistic Approach and Successful Treatment of Chronic Wound in Diabetes Mellitus by Platelet-Rich Plasma (PRP) Combined with Optimized Diet

Bolouri H* and Hajimirsadeghi A

Hagaklinik Research Institute, Specialist Polyclinic of Primary Health Care, Gothenburg, Sweden

Abstract

The underlying pathomechanisms of delayed wound healing in patients with diabetes mellitus is still a frequent and very severe problem. From a holistic point of view however, contemporary management of chronic wounds attempts to improve natural healing and individualization of treatment. Herein, we report an effective usage of platelet-rich plasma (PRP), both subcutaneously and topically, in combination with an optimized glycemic control diet in a chronic and non-healing wound. Over 26 weeks, a patient diagnosed with diabetes mellitus had received multiple therapies in attempt to heal a severe leg wound. The introduction to PRP therapy and the daily usage of the PRP gel topically led to an approximately 30% reduction in wound size over 12 days. Optimization of the patient's diet was eventually added to the treatment protocol after seeing the first improvement in wound healing. A weight loss was observed during the treatment period from 105 kg pre-treatment to 88 kg post-treatment, respectively. The prompt and promising outcome of this protocol indicates hope for the patients with chronic wounds and the urge of the further studies with holistic approaches.

Keywords: Non-healing; Leg wound; Sub-cutaneous; Growth factors; Glycemic control; Platelet-rich plasma; Peri wound skin

Abbreviations: PRP: Plasma Rich Plasma; CEO: Chief Executive Officer

Introduction

The complexity of wound healing process characterized by several stages of i.e., inflammation, proliferation healing and restoration. Platelet degranulation initiates in part the inflammatory stage of healing [1]. The standard treatment of diabetic ulcers includes measures to optimize glycemic control as well as extensive debridement, infection elimination by antibiotic therapy based on wound pathogen cultures, usage of moisture dressings, and offloading high pressure from the wound bed [2]. Cumulative studies have found that autologous platelet concentrate with growth factors or platelet-rich plasma (PRP) may accelerate wound healing [1-5].

For wound healing, autologous PRP gel has been used previously due to the consistence of cytokines, growth factors, chemokines and a fibrin scaffold derived from patient's blood [3]. The topical use of hemocomponents appeared to have a key role in regenerative medicine [6]. Since fifty's, autologous PRP has been used in orthopaedic surgeries and it was first reported in the mid-1980s [7] while PRP gel was later applied to stimulate wound healing in advanced treatment for both chronic and acute wounds [4]. Normal molecular and cellular wound healing process are induced by the effect of the PRP gel which contains a high concentration of thrombocytes, the alpha granules of platelets and platelet-released growth factors including molecules such as platelet-derived growth factor, vascular endothelial growth factor-b and transforming growth factor by stimulating cell proliferation and differentiation resulting in tissue formation [8,9].

In our best knowledge to date, none of the previous studies of autologous PRP gel has used a combination of optimized diet and autologous PRP injections.

Case Report

The patient was a 65-year-old man with an 8-year history of diabetes. He had having a heavy workload for 25 years, demanding responsibility for people and finances. At his private company as founder and CEO, which gave him a meaningful life. He has had a good health physically

and mentally. Exercise has been a part of his life with exceptions of very heavy workload at times.

In June 2016, he came to our Primary healthcare center & Polyclinic Hagakliniken and had a superficial mild injury on the lateral side of his right leg that developed to a non-healing wound. It did not respond to standard treatments used by different healthcare providers at different geographic locations and between different medical theories without being helped. Despite regular local wound care with the application of several ointments, the wound size was unaffected. Meanwhile, the antibiotics agents were also employed twice against skin infections with a lack of reduction in wound surface area. The patient became depressed around 5 months after realizing that the wound did not only heal but also increased in size. In February 2017, he had a wound area with (length × width) measurement of 35 × 25 mm² prior to the treatment in our clinic (Figure 1a). The patient underwent a total of 13 PRP treatments over 24 weeks starting on 27 February 2017 (Figures 1a-1j). During PRP treatment, the wound size significantly decreased from 35 × 25 mm² (Figure 1a, 27th February), 32 × 22 mm² (Figure 1b, 8th March) to 5 × 8 mm² (Figure 1h, 29th June), and pain decreased (Fig. 1a and b).

Application of PRP subcutaneously and topically

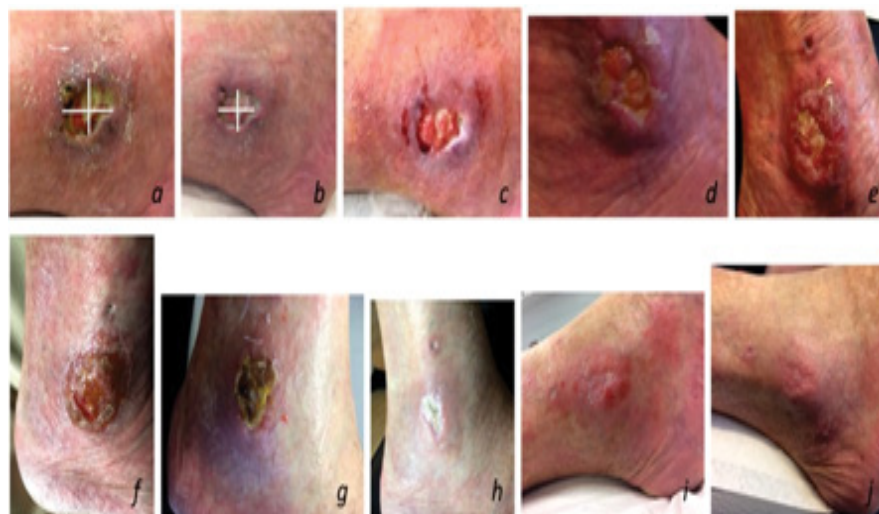
Briefly, 16 ml of peripheral blood was obtained from the median cubital vein of the patient using a 22G × 1-1/4" (0.7 × 32 mm) butterfly needle. The blood was stored 20 min at room temperature and spun in 1500 g 12 min. To minimize discomfort, the peri wound skin was anesthetized locally with EMLA containing Lidocaine 25 mg/g and

***Corresponding author:** Hayde Bolouri, Hagakliniken Research Institute, Specialist Polyclinic of Primary Health Care, Gothenburg, Sweden, Tel: +46 709 75 74 96, Fax: +46 31 711 60 06, E-mail: hayde@hagakliniken.se

Received: August 24, 2017; **Accepted:** September 12, 2017; **Published:** September 23, 2017

Citation: Bolouri H, Hajimirsadeghi A (2017) A Holistic Approach and Successful Treatment of Chronic Wound in Diabetes Mellitus by Platelet-Rich Plasma (PRP) Combined with Optimized Diet. *Dermatol Case Rep* 2: 127.

Copyright: © 2017 Bolouri H, et al. This is an open-access article distributed under the terms of the Creative Commons Attribution License, which permits unrestricted use, distribution, and reproduction in any medium, provided the original author and source are credited.



(a) Wound area with (length × width) measurement of 35 × 25 mm² prior to the treatment in our clinic.
(a-j) The patient underwent a total of 13 PRP treatments over 24 weeks starting on 27 February 2017.

Figure 1: Step by step successful treatment of chronic wound in diabetes mellitus by platelet-rich plasma (PRP) combined with optimized diet.

Prilocaine 25 mg/g cream (AstraZeneca AB, Sweden). After 10 min, a total of 2 ml autologous PRP was injected into the peri wound skin in one cm distant using a 30-gauge needle. An approximately 500 µl dropped directly onto the wound.

The procedure was well tolerated with mild tenderness present on the day of the procedure and the following 2 days. No other observation or lateral effects were noticed. The procedure was repeated twice a month. A total amount of 5 ml autologous PRP was activated with 1 ml hyaluronic acid [10] and spun in 1500 g 15 min. The activated PRP was incorporated in a gel homogenizing by overhead mix 500 rpm at 1 ml per min with a final concentration of 10 per cent.

Optimized diet

The patient was asked to follow a gluten free, lactose free and sugar free otherwise Mediterranean diet with very low consumption of carbohydrates. Initially, a period of three weeks as an elimination period was set up. The patient continued with the diet consequently when he experienced a general improvement in his energy level and health both physically and mentally. A weight loss of 15 kg occurred successively within the wound-healing period of the 4 months, which was positively experienced of the patient.

Discussion

Chronic wounds cause pain to the patients both physically and mentally and as the name suggests, take long time to restore to health. However, the mechanism of PRP in the treatments of chronic wounds is not known or elaborated and the clinical application of the PRP may need to be standardized.

Recently research has shown that 100 chronic thalassemic leg wound were treated by PRP gel and wound size reduction was observed after 4 weeks [4]. Our patient received both autologous PRP subcutaneously and gel topically followed by an optimized diet. The wound size reduction (from 35 × 30 mm to 32 × 22 mm) was appeared approximately two weeks after the first session of the PRP. This report will perhaps help extrapolation of the use of PRP for chronic wound treatment in standard healthcare. In our opinion, an optimized diet in combination with the autologous PRP would be beneficial in future treatment of the patients

with leg ulcers and wounds caused by diabetes. Much of the literature supports the use of PRP to enhance healing [11] however, no sex difference has been reported in response to the treatment.

Conclusion

Autologous PRP has also been used for the treatment of all types wound healing including burns, diabetic, and split-thickness skin to stimulation of proliferation in skin cells however, these treatments have not been performed in combination with diet optimization.

For several decades, PRP has provided a promising alternative to traditional methods by promoting safe and natural healing [12]. The combination of autologous PRP, subcutaneously and topically, and the optimized diet opens a new therapeutic window for treatment of the chronic wounds.

Acknowledgments

The authors would like to acknowledge all colleagues from Hagakliniken who were involved in this case.

References

1. Bennett NT, Schultz GS (1993) Growth factors and wound healing: Part II. Role in normal and chronic wound healing. *Am J Surg* 166: 74-81.
2. Tsourdi E, Barthel A, Rietzsch H, Reichel A, Bornstein SR (2013) Current aspects in the pathophysiology and treatment of chronic wounds in diabetes mellitus. *Biomed Res Intl* Apr p. 1: 2.
3. Frykberg RG, Driver VR, Carman D, Lucero B, Borris-Hale C, et al. (2010) Chronic wounds treated with a physiologically relevant concentration of platelet-rich plasma gel: a prospective case series. *Ostomy Wound Manag* 56: 36.
4. Afradi H, Saghaei Y, Kachoei ZA, Babaei V, Teimourian S (2017) Treatment of 100 chronic thalassemic leg wounds by plasma-rich platelets. *Intl J Dermatol* 56: 171-175.
5. Kieb M, Sander F, Prinz C, Adam S, Mau-Möller A, et al. (2017) Platelet-rich plasma powder: A new preparation method for the standardization of growth factor concentrations. *Am J Sports Med* 45: 954-960.
6. Landi A, Tarantino R, Marotta N, Ruggeri AG, Domenicucci M, et al. (2011) The use of platelet gel in postero-lateral fusion: Preliminary results in a series of 14 cases. *Eur Spine J* 20: 61-67.
7. Knighton DR, Ciresi KF, Fiegel VD, Austin LL, Butler EL (1986) Classification and treatment of chronic nonhealing wounds. Successful treatment with autologous platelet-derived wound healing factors (PDWHF). *Annals Surg* 204: 322.

8. Minniti CP, Eckman J, Sebastiani P, Steinberg MH, Ballas SK (2010) Leg ulcers in sickle cell disease. *Am J Hematol* 85: 831-833.
9. Delclaux C, Zerah-Lancner F, Bachir D, Habibi A, Monin JL, et al. (2005) Factors associated with dyspnea in adult patients with sickle cell disease. *Chest* 128: 3336-3344.
10. Kohei I, Furukawa KI, Tsuda E, Yamamoto Y, Maeda S, et al. (2016) Hyaluronic acid induces the release of growth factors from platelet-rich plasma. *Asia-Pacific J Sports Med* 4: 27-32.
11. Knox RL, Hunt AR, Collins JC, Desmet M, Barnes S (2006) Platelet-rich plasma combined with skin substitute for chronic wound healing: a case report. *J Extra Corpor Technol* 38: 260.
12. Yotsu RR, Hagiwara S, Okochi H, Tamaki T (2015) Case series of patients with chronic foot ulcers treated with autologous platelet-rich plasma. *J Dermatol* 42: 288-295.