

## A Middle-Aged Man with Right-Sided Chest Pain, Hemoptysis and Weight Loss

Khajotia RR\*

Internal Medicine and Pulmonology, International Medical University, Seremban, Malaysia

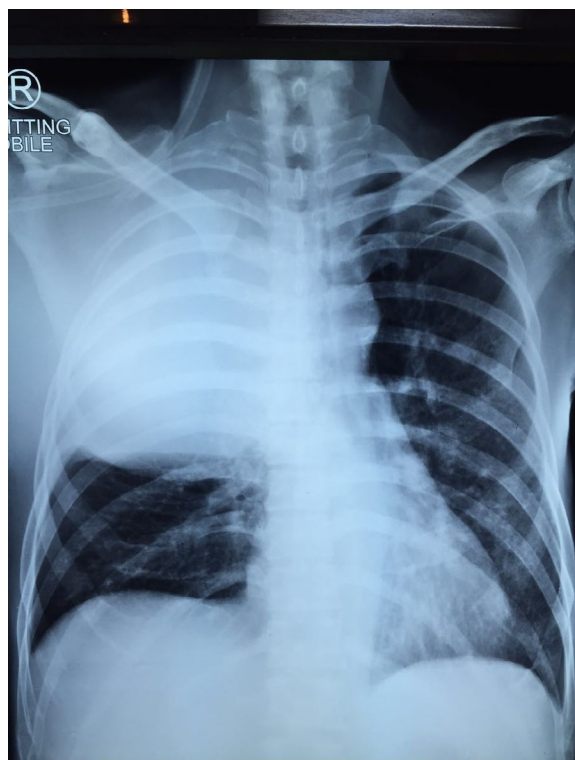


Figure 1: A chest radiograph.

### Clinical Scenario

A 50-year-old man, chronic smoker, smoking 20 cigarettes per day for the last 30 years, presents to the pulmonary out-patient department with complaints of right-sided chest pain accompanied by tenderness over the right chest wall and occasional hemoptysis, since the past 4 months. The chest pain disturbs his sleep and he now requires increasing doses of pain killers in order to combat the pain. He has lost 20 kgs weight over the last 4 months.

On examination, the right hemithorax is significantly tender on palpation, and moves less with respiration as compared to the left side. A swelling is noticed in the right supraclavicular region which is hard, non-tender and fixed to the underlying structures. The trachea is shifted to the left side. There is a dull note on percussion over the right 1<sup>st</sup> to 5<sup>th</sup> intercostal spaces, while the left side is normal. On auscultation, air entry is diminished over the right hemithorax with bronchial breath sounds in the right 4<sup>th</sup> and 5<sup>th</sup> intercostal spaces. Normal vesicular breath sounds are heard over the left hemithorax.

A chest X-ray is urgently done.

Q1) What does the chest X-ray show?

Q2) What are the possible causes for this large rounded opacity in the right hemithorax

Q3) Based on the above history and chest X-ray findings, what is the most likely clinical diagnosis?

Q4) What other investigations would you perform in this patient in order to confirm the diagnosis?

Q5) Clinically, what is the likely stage of the disease?

\*Corresponding author: Rumi R Khajotia, MBBS, Associate Professor in Internal Medicine and Pulmonology, International Medical University, Seremban, Malaysia, E-mail: [rumi@imu.edu.my](mailto:rumi@imu.edu.my)

Received April 02, 2016; Accepted April 05, 2016; Published April 11, 2016

Citation: Khajotia RR (2016) A Middle-Aged Man with Right-Sided Chest Pain, Hemoptysis and Weight Loss. J Clin Respir Dis Care 2: i002. doi: [10.4172/2472-1247.1000i002](https://doi.org/10.4172/2472-1247.1000i002)

Copyright: © 2016 Khajotia RR. This is an open-access article distributed under the terms of the Creative Commons Attribution License, which permits unrestricted use, distribution, and reproduction in any medium, provided the original author and source are credited.

Q6) How will you manage this patient?

A1) The chest X-ray shows a homogenous, large diffuse opacity over the right hemithorax (9 cm × 5.5 cm in size), which has a well-defined lower border with convexity downwards. No air-bronchogram is seen within the opacity. There is a significant narrowing of the right main-stem bronchus, about 1 cm below the carina. Rest of the right lung appears to be clear. A few ill-defined opacities are seen in the left mid-and-lower zones of the lungs. The trachea and lower mediastinum appear to be shifted to the left side.

A2) A large solid tumor mass in the right lung (with a possible underlying lung collapse).

A large loculated right pleural effusion.

A3) Bronchogenic carcinoma of the right lung with underlying partial lung collapse (and possible spread to the mediastinum).

A4) Sputum cytology for malignant cells

Tumor markers such as NSE, CYFRA 21-1, CEA.

HRCT Chest Scan and CT-guided percutaneous lung biopsy, if appropriate.

Fibreoptic/ Video Bronchoscopy.

Excision biopsy of the right cervical lymph nodes.

A5) Stage IV

A6) Palliative chemotherapy and palliative radiotherapy.

Pain management.

Treat breathlessness if it occurs, by tracheobronchial stenting, invasive ventilation.

Maintain good nutritional status.

Psychiatric management to combat depression, due to the nature of the disease.

## Discussion

This 50-year-old man, chronic smoker, presented with right-sided chest pain of increasing intensity, hemoptysis and rapid weight loss of 20 kg, since the past 4 months. On examination, severe tenderness was noted over the right chest wall anteriorly. The trachea was shifted to the left side and a dull note on percussion was heard over the right hemithorax. Bronchial breath sounds were heard in the right 4<sup>th</sup> and 5<sup>th</sup> intercostal spaces, indicative of a large tumor very close to the chest wall with a patent bronchus below it. The hard, non-tender and fixed lymph nodes in the neck were indicative of malignancy. The chest wall tenderness and malignant cervical lymphadenopathy were an indication that the tumour had infiltrated the distant lymph nodes, chest wall and possibly the rib cage as well. Chest X-ray was indicative of a large tumor mass in the right hemithorax, extending to the periphery (chest wall) along with a significant narrowing of the right main-stem bronchus. Hence, clinical and radiological findings indicated that the patient was in stage IV of the disease and management could only be supportive and palliative.

Citation: Khajotia RR (2016) A Middle-Aged Man with Right-Sided Chest Pain, Hemoptysis and Weight Loss. J Clin Respir Dis Care 2: i002. doi: 10.4172/2472-1247.1000i002

### OMICS International: Publication Benefits & Features

#### Unique features:

- Increased global visibility of articles through worldwide distribution and indexing
- Showcasing recent research output in a timely and updated manner
- Special issues on the current trends of scientific research

#### Special features:

- 700+ Open Access Journals
- 50,000+ Editorial team
- Rapid review process
- Quality and quick editorial, review and publication processing
- Indexing at major indexing services
- Sharing Option: Social Networking Enabled
- Authors, Reviewers and Editors rewarded with online Scientific Credits
- Better discount for your subsequent articles

Submit your manuscript at: [www.omicsonline.org/submission](http://www.omicsonline.org/submission)