

## A Modification to the Gill Technique of Removal of the Rattler Fragment in Isthmic Spondylolisthesis

Daniel D Lee<sup>1\*</sup> and Amit Parekh DO<sup>2</sup>

<sup>1</sup>Desert Orthopedic Center, East Desert Inn Road, Suite 100, Las Vegas, Nevada, USA

<sup>2</sup>Valley Hospital Medical Center, Graduate Medical Education-Orthopedics, 620 Shadow Lane, Las Vegas, Nevada, USA

### Abstract

Adult isthmic spondylolisthesis treated with en-bloc laminectomy has long been a standard practice. The technique of removing the rattler fragment can have associated complications including durotomy and damage to exiting nerve roots. We describe a technique of en-bloc laminectomy by mobilizing the fragment through the pars defect and resecting the ligamentum flavum with the aid of an interspinous distraction device.

**Keywords:** Spondylolisthesis; Decompression; Laminectomy; Distraction; En bloc

**Level of Evidence:** Level V Technique Guide

### Introduction

Surgical management of adult isthmic spondylolisthesis with posterior decompression by removal of the posterior elements through excision of the fibrocartilaginous pars defect was first described by Gill in 1955 [1]. The Gill technique of decompression is still used widely today with some modifications. In isthmic spondylolisthesis, a defect across the pars interarticularis occurs in childhood or adolescence as a result of acute traumatic injury, fatigue fracture nonunion from repetitive loading, or elongation of the pars as a result of multiple healed stress fractures. Gradually this can result in spondylolisthesis and symptomatic central, foraminal, or lateral recess stenosis. In 1985 Cloward described a similar technique which included posterior interbody fusion to address a complication of the Gill decompression which was instability following removal of the posterior elements [2]. The author's technique utilizes the en-bloc resection of the "rattler" fragment with the addition of stabilization via posterior instrumentation, posterolateral fusion, and interbody fusion [3,4].

When removing the posterior elements of the affected vertebra, most commonly at L5-S1, the resection occurs through the isthmic defect along the path of fibrous scar tissue. Caudally the resection occurs across the ligamentum flavum and into the zygapophyseal capsule [5]. Challenges in performing this approach include visualization and accurate identification and resection through the pars defect, the removal of the redundant or hypertrophic ligamentum flavum with underlying dural ectasia, and mobilization of the fragment from dural adhesions. This technique guide illustrates a modification of the technique of posterior decompression and excision of the "rattler" fragment utilizing a posterior lumbar interspinous distraction device [6-8].

### Case Report and Operative Indications

A 48-year-old active female with no significant comorbidities presented with bilateral L5 pars defects with a history of Grade 2 adult isthmic spondylolisthesis who developed chronic low back and progressive bilateral leg pain over the course of two years with diminished sensation over the dorsum of the foot bilaterally. Conservative management including physical therapy, anti-inflammatories, opiates, muscle relaxers, chiropractic treatments, corticosteroid injections, and gabapentin failed to alleviate her symptoms [9]. Symptoms continued to progress and she developed subtle weakness with right hallux dorsiflexion 4/5 strength, consistent with right L5 radiculopathy.

Radiographs, CT and MRI results reveal bilateral L5 pars defects with isthmic grade 2 spondylolisthesis and resulting bilateral severe neural foraminal stenosis (Figures 1A-1C, Figures 2A and 2B and Figure 3). She underwent posterior decompression with en-bloc resection of the L5 posterior elements, partial reduction of anterolisthesis, posterior instrumentation and anterior lumbar interbody fusion. The posterior decompression technique presented below was utilized. Postoperatively, the patient's symptoms resolved, and she recovered uneventfully.

### Operative Technique

The patient is taken to the operating room, general anesthesia is administered, and endotracheal intubation is performed. Arterial and central venous access is obtained. Perioperative antibiotic prophylaxis is given in accordance with standard protocol. Patient is positioned prone on the Jackson table, all bony prominences are well padded, and patient is secured to the table. The back is then cleansed with 3% chlorhexidine and prepped and draped in the usual sterile fashion [10].

A 5 cm midline skin incision is made and taken through the dorsal lumbar fascia. Sub-periosteal dissection is performed in accordance with the standard posterior approach to the lumbar spine down to the lamina of L5 which is identified using biplanar fluoroscopy. Care is taken to preserve the facet capsules above and below the operative level.

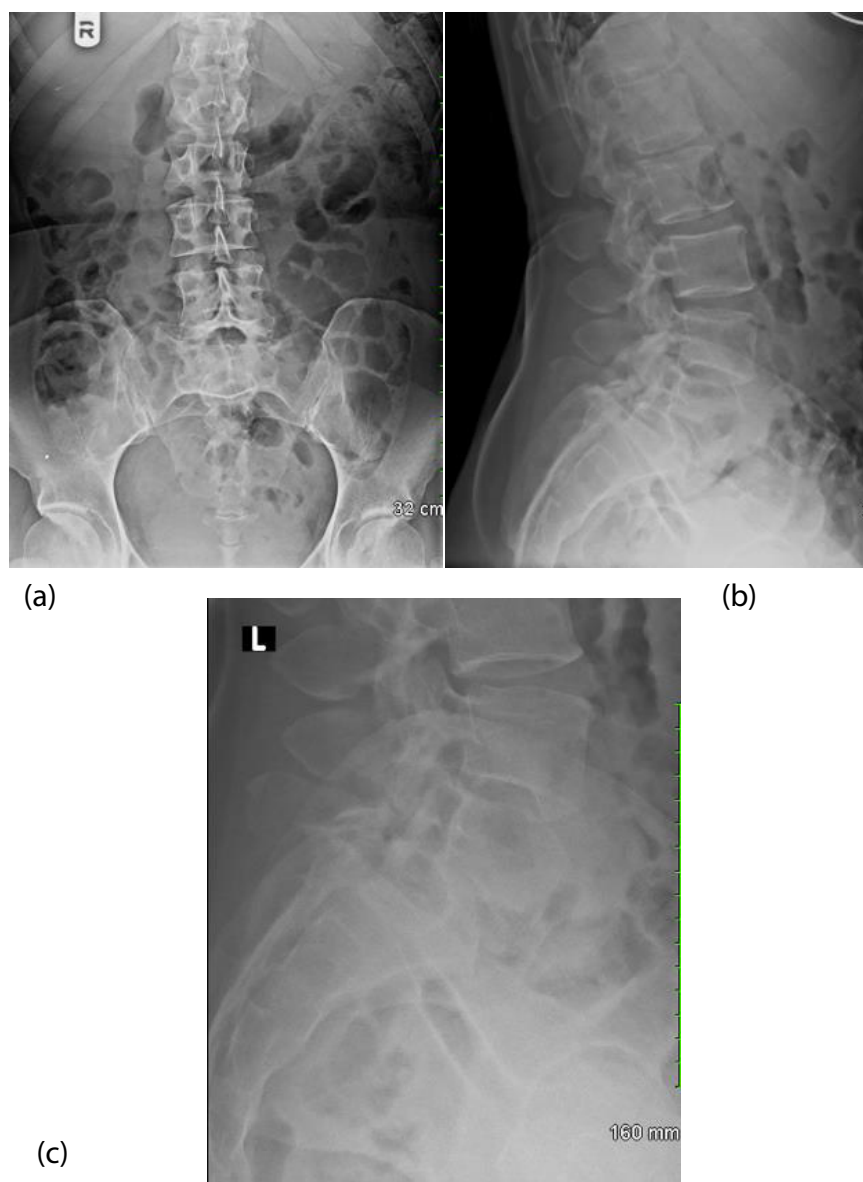
Bilateral defects of the L5 pars inter-articularis are visualized on fluoroscopy consistent with preoperative advanced imaging. A final confirmation to ensure the correct level is identified is done by grasping the spinous process of L5 which is readily felt and directly visualized to be mobile relative to L4 and sacrum. After confirmation, the interspinous ligament at L4 and L5, L5 and sacrum are removed. It is important at this step to not remove the spinous process of the segment containing the pars defect, in this case L5 (Figure 4). The zygapophyseal joint capsules of the L5 and S1 segment are then released (Figures 5A and 5B).

**\*Corresponding author:** Daniel D Lee, Desert Orthopedic Center, 2800 East Desert Inn Road, Suite 100, Las Vegas, Nevada-89121, USA; Tel: +7027314088; E-mail: [ddlee@hotmial.com](mailto:ddlee@hotmial.com)

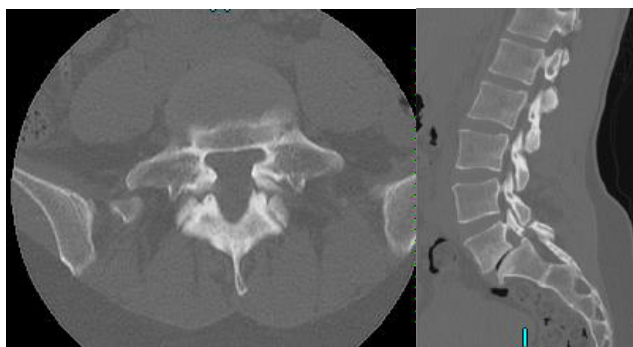
**Received** July 22, 2018; **Accepted** September 25, 2018; **Published** October 09, 2018

**Citation:** Lee DD, Amit Parekh DO (2018) A Modification to the Gill Technique of Removal of the Rattler Fragment in Isthmic Spondylolisthesis. J Spine 7: 418. doi: [10.4172/2165-7939.1000418](https://doi.org/10.4172/2165-7939.1000418)

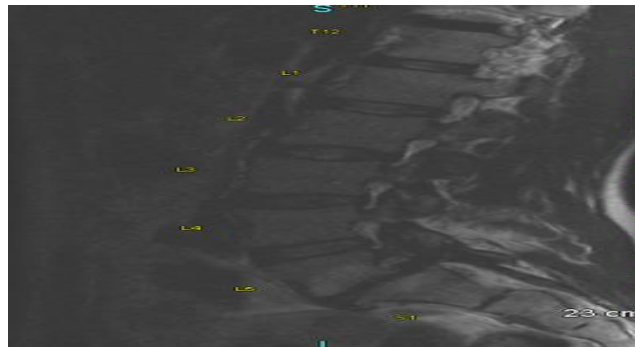
**Copyright:** © 2018 Lee DD, et al. This is an open-access article distributed under the terms of the Creative Commons Attribution License, which permits unrestricted use, distribution, and reproduction in any medium, provided the original author and source are credited.



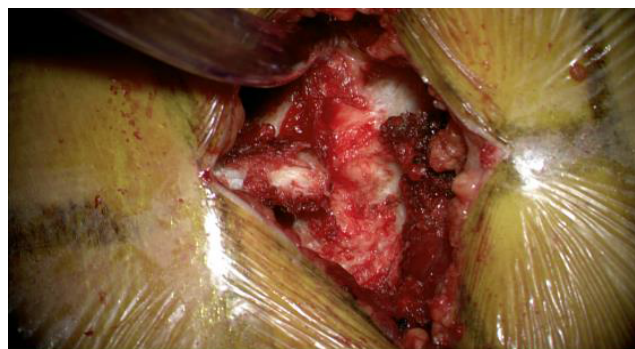**Figure 1:** (A, B and C) AP and lateral radiographs of the lumbar spine showing grade 2 isthmic spondylolisthesis with pars defect.



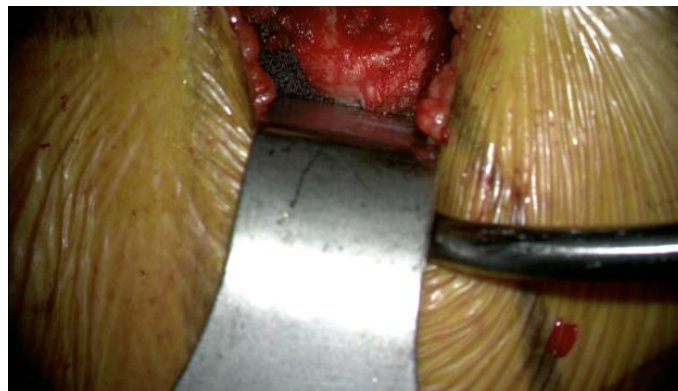**Figure 2:** (A and B) The axial CT image at the pars defect showing a fibro-osseous bridge with elongation of the pars and canal. The sagittal CT image through the right zygapophyseal joints showing the defect of the pars inter-articularis, and degenerative changes of the L5-S1 level including vacuum disc phenomenon, loss of disc height, large dorsal osteophyte of S1, and sub-chondral sclerosis.



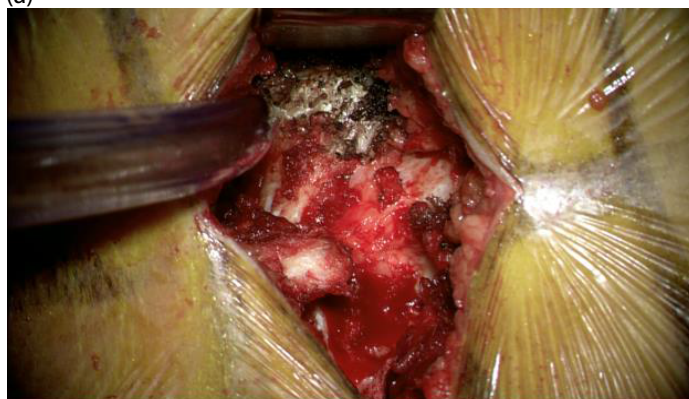**Figure 3:** MRI re-demonstrates above, also illustrates modic endplate change.



**Figure 4:** Demonstrates removal of the interspinous ligament at L4-L5. It is important to not disrupt the spinous process at L5 at this time.



(a)



(b)

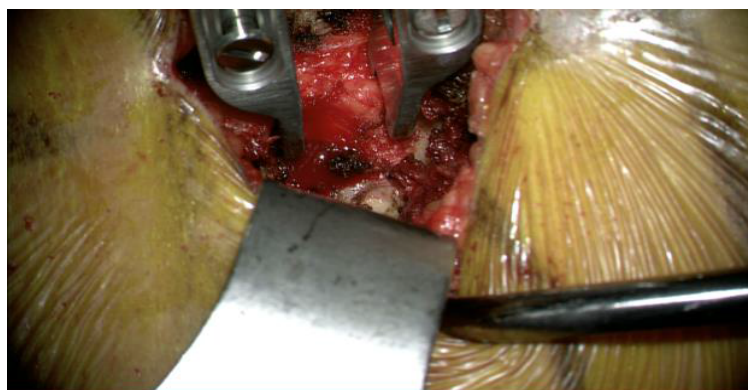
**Figure 5: (A and B)** Demonstrates the facet joints at L5-S1 before and after releasing the Facet capsules.

A small angled curette is used to identify the central raphe of the ligamentum flavum between L5 and sacrum. The ligamentum flavum is removed in a standard fashion using Kerrison rongeurs. A curette may be used to release the cephalad attachment at the caudal margin of the L5 lamina. By using a parallel lumbar rod distractor (Figures 6A and 6B) at these steps the tension across the ligamentum flavum aids in identification and separation from the underlying dura. It is important to have an assistant stabilize the distraction device as the ligamentum flavum release nears completion to prevent any slippage of the device and maintain constant tension. It is important to assess the mobility of the L5-S1 segment at this time, if there are any remaining tethers to mobilization or foraminal stenosis from capsular attachments or osteophytes secondary to facet arthropathy, one must ensure bilateral

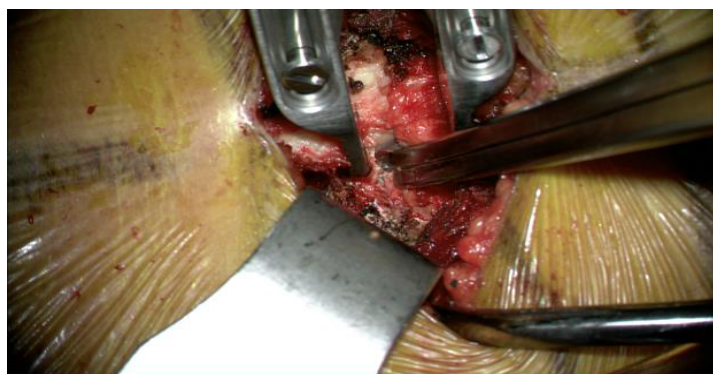
facetectomies and wide foraminal decompression are completed prior to continuing to the next step [11].

Next the L4-L5 segment releases are performed. The ligamentum flavum at the L4-L5 segment is then removed in the standard fashion with Kerrison rongeurs. The parallel lumbar rod distractor is then placed at the L4-L5 interspace. With gentle distraction, the mobile and tethered areas along the pars inter-articularis defects can be readily identified, and decompression can be safely performed despite the abnormal anatomy. There may be a fibrous/osseous bridge through the pars defect, which is released bilaterally and wide foraminal decompression performed (Figure 7).

The distractor is positioned between the L5 and S1 spinous processes,

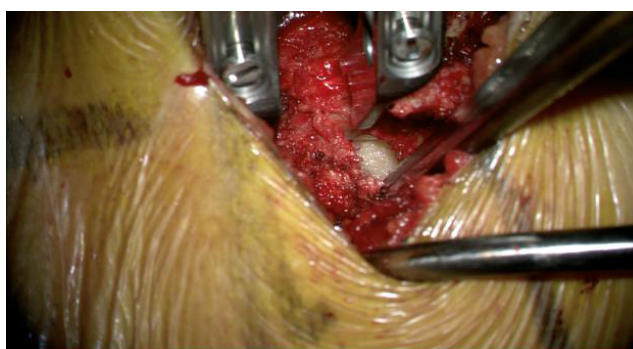

(a)



(b)

**Figure 6: (A and B)** Shows the removal of the ligamentum flavum at L5-S1 with the assistance of the distractor creating tension along the ligament and the distractor being used to further identify the right L5-S1 facet joint and release remaining capsular tethers.



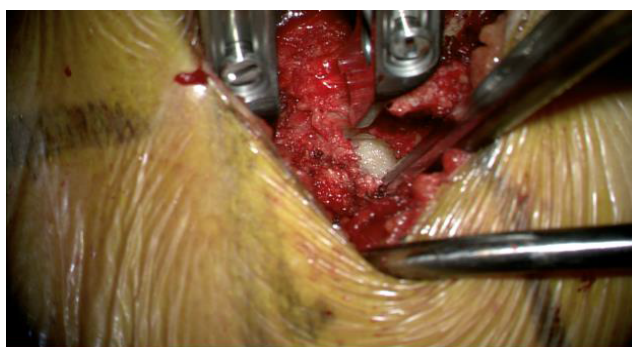**Figure 7:** Distractor is placed across the L4-L5 spinous processes. Distraction creates a gap at the fibrocartilaginous pars defects.

with distraction applied the L5 lamina elevates off of the dura (Figure 8). One must be cautious during this step to identify any remaining soft tissue tethers and dural adhesions. If significant resistance is felt while releasing, stop and re-evaluate all possible remaining tethers to complete release. Do not apply excessive force across the distractor as this may risk traction injury or dural tear if the exiting nerve roots have not been completely decompressed, or if any underlying dural adhesions are present. During posterior arch removal, it is important that one has complete two hand control over the distraction device to prevent any slippage and inadvertent injury.

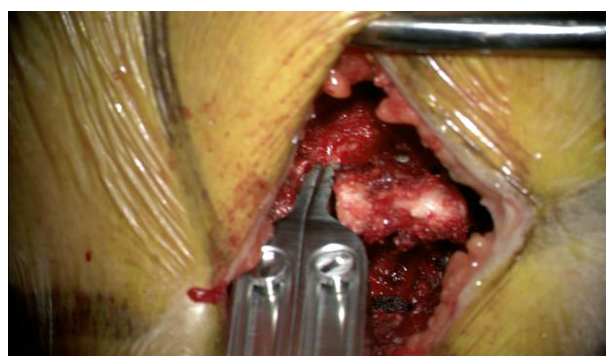While continuing to apply distraction across the segment, the spinous process of L5 is then firmly grasped with a Lexell rongeur. Using a slight twisting and side to side motion, the rattler fragment is mobilized and easily removed en-bloc (Figures 9A and 9B).

The exiting nerve roots should be widely decompressed to the lateral wall of the pedicles. There may be significant fibrous scar and osteophytes from the inferior articular process of the cranial vertebra. A Woodson probe should easily pass along the neural foramen and lateral recess without difficulty. With the decompression complete, the thecal sac should be inspected for any iatrogenic durotomy and valsalva maneuver performed (Figure 10).

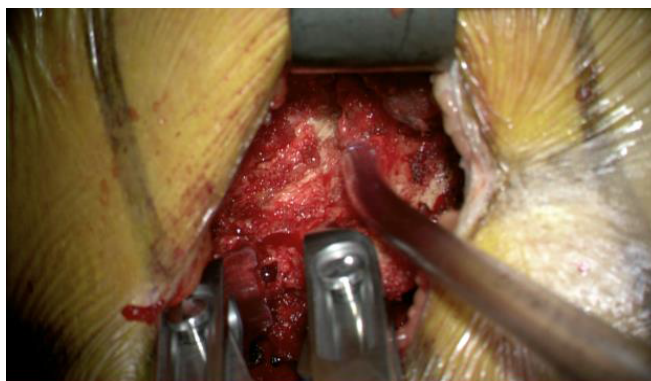The remainder of the case proceeds in the traditionally described fashion. Posterior instrumentation is placed. In this case, anterior interbody from a left sided retroperitoneal approach was performed prior to performing the posterior decompression with partial reduction of the spondylolisthesis. (Figures 11A and 11B) Alternatively, L5 and S1 segment discectomy, endplate preparation, and transforaminal interbody fusion may be performed. The purpose of this work is



**Figure 8:** The distractor being used to mobilize the "rattler" fragment of L5.

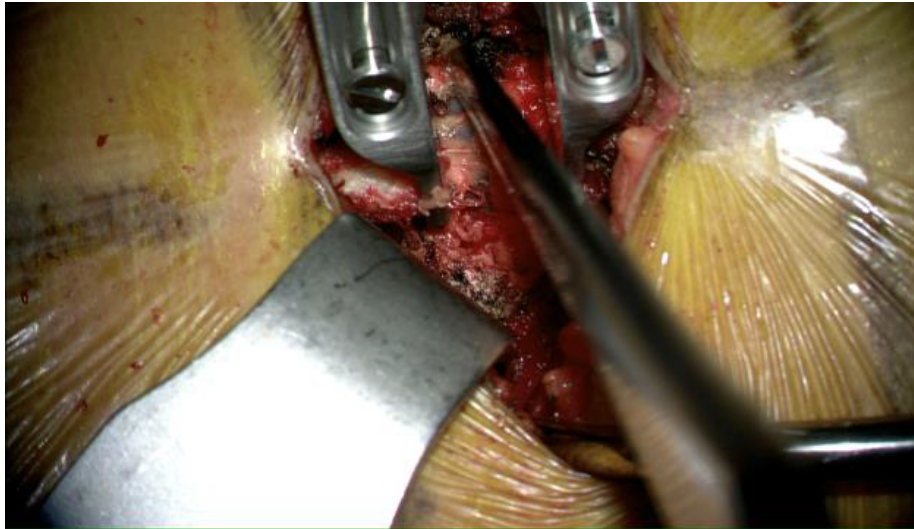

(a)

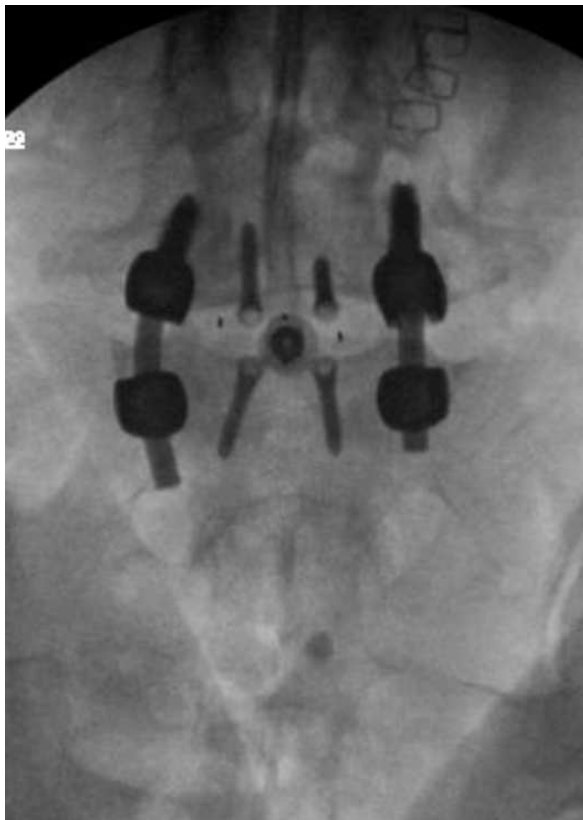


(b)

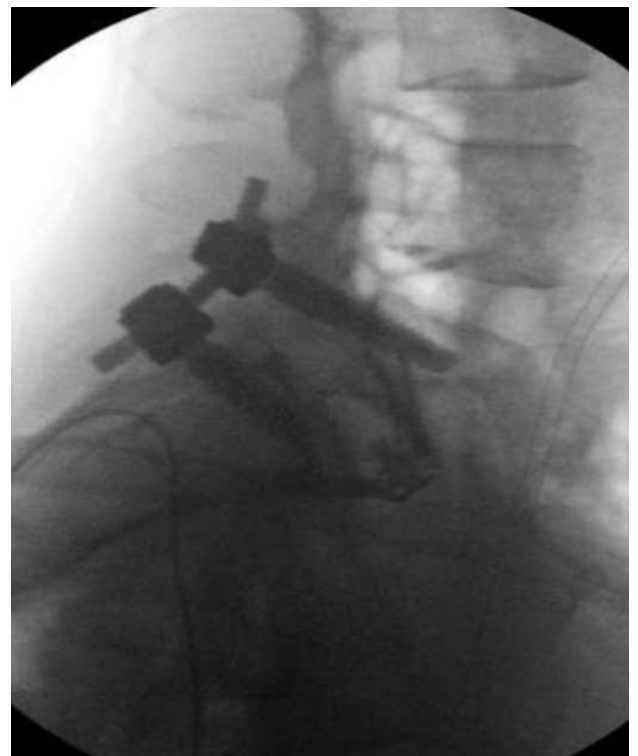
**Figure 9: (A and B)** Pre-and post-distraction images at the pars show how distraction aids identification of the fibrocartilaginous defect.



**Figure 10:** Demonstrates wide decompression with intact dura and no evidence of CSF leakage on valsalva maneuver.



(a)



(b)

**Figure 11: (A and B)** Intra-operative fluoroscopic images following instrumentation. Of note, anterior interbody fusion of L5-S1 was completed prior to performing the posterior decompression. Partial reduction of the spondylolisthesis was obtained.

not to discuss the merits of interbody fusion options or reduction of spondylolisthesis, this decision is left to the surgeon as one must take

into account patient comorbidities, prior abdominal surgery, degree of listhesis, and other (Figures 12A and 12B).



(a)



(b)

**Figure 12: (A and B)** Images of the lumbar rod distractor which was used as an interspinous distractor. (Medtronic, Minneapolis MN) Alternatively a lamina spreader may be used, however this distractor has a smaller footprint and is easier to work around.

## Discussion

The use of an interspinous distractor to aid in en bloc removal of the spondylolytic fragment is a novel modification of the currently described decompression technique in adult isthmic spondylolisthesis. The proposed benefits of this modification include ease of identification of the tissue plane between the ligamentum flavum and dura, the plane of intralesional resection at the pars defect, identification of soft tissue or osseous tethers to the posterior arch fragment, and increased speed and efficiency of posterior arch fragment excision. The risks of this modification include the potential for the device to slip and cause neural injury if not properly secured, iatrogenic durotomy if dural adhesions are not identified and released prior to complete removal of the fragment, and traction radiculitis if the exiting nerve roots are not thoroughly decompressed and mobilized prior to the final release of the posterior arch fragment.

The authors' preference is to reduce the slip using a standard pedicle screw and rod construct followed by interbody as well as posterolateral fusion. However, there is much debate over the Gill technique of decompression alone versus instrumentation and interbody fusion or posterolateral fusion with recent trends toward stabilization and fusion. Factors influencing risk of secondary instrumented surgery include preoperative instability, discectomy at the affected level and neuroforaminal nerve root compression between pedicle and slipped

disc [1]. The purpose of this work is not to discuss the merits of these techniques, rather to simply present a novel modification of the decompression technique using a parallel lumbar rod distractor as an interspinous distraction device. The authors prefer using the parallel lumbar rod distractor because the footprint of the rod distractor is smaller than a lamina spreader. However, a lamina spreader may be used if the distractor (Medtronic, Minneapolis MN) is unavailable. A PubMed literature search yielded no results with the search terms "adult isthmic spondylolisthesis" and "technique" and "distraction" or "interspinous distraction" or "distractor."

The optimal management of adult isthmic spondylolisthesis remains a controversial topic. A recent systematic review by Schulte et al. focused on four pertinent questions: Is surgery more successful in terms of pain and function than conservative treatment for either isthmic or degenerative spondylolisthesis? Is decompression alone more successful than decompression and fusion? Is decompression and fusion with reduction of listhesis more successful than *in situ* decompression and fusion? Their systematic review concluded that surgery is more successful than conservative management with poor quality evidence for isthmic spondylolisthesis, good quality evidence for degenerative spondylolisthesis. Instrumented fusion is more successful than decompression alone but quality of evidence is poor. Reduction of listhesis and fusion is no more successful than instrumented fusion without reduction in isthmic and degenerative spondylolisthesis

with moderate quality of evidence. The NASS 2014 guidelines for the management of adult isthmic spondylolisthesis concluded that there is insufficient evidence to make a recommendation regarding decompression alone versus decompression and fusion. The workgroup gave a Grade B recommendation to the addition of instrumentation when performing a fusion however. Regarding interbody with concurrent posterolateral fusion, Grade A recommendation was given with the benefit of higher radiographic fusion rates and better clinical outcomes [8].

Recent advances in surgical technique also include minimally invasive percutaneous instrumentation with indirect decompression via anterior interbody fusion which has shown promising results with 98% fusion rates at 6 months however complications include transient anterior thigh numbness and foot drop [5]. The currently accepted standard at this time remains wide direct decompression, interbody fusion, and posterior instrumentation [6].

## Conclusion

Interspinous distraction can be a useful tool to aid safe and efficient removal of the “rattler” fragment en-bloc. The possible risks of this technique include traction radiculitis, dural injury, and iatrogenic spinous process fracture. These risks can be mitigated using careful technique, gentle distraction, and being mindful of secure and stable distraction device placement. The possible benefits of this technique include greater efficiency and shorter surgical time, better visualization of the defect, and a mechanical confirmation of the correct level which conceivably could reduce the likelihood of wrong level surgery. Follow up cohort studies comparing this technique of decompression with the assistance of a distraction device to the standard open posterior technique would be beneficial in evaluating these potential risks and benefits.

## References

1. Gill GG, Manning JG, White HL (1955) Surgical treatment of spondylolisthesis without spine fusion; excision of the loose lamina with decompression of the nerve roots. *J Bone Joint Surg Am* 37: 493-520.
2. Cloward RB (1985) Posterior lumbar interbody fusion updated. *Clin Orthop Relat Res* 193: 16-19.
3. Arts MP, Verstegen MJ, Brand R, Koes BW, Akker ME, et al. (2008) Cost-effectiveness of decompression according to Gill versus instrumented spondylodesis in the treatment of sciatica due to low grade spondylolytic spondylolisthesis: A prospective randomised controlled trial [NTR1300]. *BMC Musculoskeletal Disord* 9: 128.
4. Chandra V, Singh RK (2016) Anterior lumbar inter-body fusion with instrumentation compared with posterolateral fusion for low grade isthmic-spondylolisthesis. *Acta Orthop Belg* 82: 23-30.
5. Fleege C, Arabmottagh M, Rother W, Rauschmann M, Rickert M (2016) ALIF and PLIF interposition in low-grade isthmic spondylolisthesis L5/S1: Long-term-comparison of interbody fusion techniques (ALIF - PLIF). *Der Orthopade* 45: 760-769.
6. Hegde D, Mehra S, Babu S, Ballal A (2017) A study to assess the functional outcome of decompression and posterior lumbar interbody fusion of low grade spondylolisthesis of lumbar vertebra. *J Clin Diagn Res* 11: RC01-RC03.
7. Januszewski J, Beckman JM, Bach K, Vivas AC, Uribe JS (2017) Indirect decompression and reduction of lumbar spondylolisthesis does not result in higher rates of immediate and long term complications. *J Clin Neurosci* 45:218-222.
8. Schulte TL, Ringel F, Quante M, Eicker SO, Mueche-Borowski C, et al. (2016) Surgery for adult spondylolisthesis: a systematic review of the evidence *Eur Spine J* 25: 2359-2367.
9. Yilmaz T, Dalbayrak S, Yaman O, Yilmaz M, Ayten M, et al. (2015) A modified technique for the treatment of isthmic spondylolisthesis. *Turk Neurosurg* 25: 394-403.
10. Scott KD, Jamie B, Daniel M, Rakesh P, Bess RS, et al. (2014) North American Spine Society Evidence-Based Clinical Guidelines for Multidisciplinary Spine Care. Diagnosis and Treatment of Adult Isthmic Spondylolisthesis. North American Spine Society. USA.
11. Burton MR, Mesfin FB (2018) Isthmic spondylolisthesis. In: *StatPearls Treasure Island (FL): StatPearls Publishing.*