

## A Rare Case of a Complex System of Fistulas in Crohn's Disease

Gloor S<sup>1</sup>, Jensen KO<sup>2</sup>, Gingert C<sup>2,3</sup>, Junker T<sup>2</sup>, Hetzer FH<sup>4</sup> and Angst E<sup>2,5\*</sup>

<sup>1</sup>Department of Visceral and Thoracic Surgery, Cantonal Hospital Winterthur, Winterthur, Switzerland

<sup>2</sup>Department of Surgery and Orthopedics, Cantonal Hospital Schaffhausen, Schaffhausen, Switzerland

<sup>3</sup>Faculty of Health, Department of Medicine, University of Witten/Herdecke, Witten, Germany

<sup>4</sup>Department of Surgery, Spital Linth, Uznach, Switzerland

<sup>5</sup>Department of Visceral Surgery and Medicine, Inselspital, University of Bern, Bern, Switzerland

\*Corresponding author: Angst Eliane, Department of Surgery and Orthopedics, Cantonal Hospital Schaffhausen, Geissbergstrasse 81, Schaffhausen 8208, Switzerland; Tel: 0041 52 634 27 15; Fax: 0041 52 634 27 11; E-mail: [eliane.angst@dkf.unibe.ch](mailto:eliane.angst@dkf.unibe.ch)

Received date: February 27, 2016; Accepted date: March 9, 2016; Published date: March 16, 2016

Copyright: © 2016 Gloor S, et al. This is an open-access article distributed under the terms of the Creative Commons Attribution License, which permits unrestricted use, distribution, and reproduction in any medium, provided the original author and source are credited.

### Abstract

Fistulas in Crohn's disease are a common problem in treatment of the disease. Especially perianal fistulas may cause a loss in patient's quality of life. They are coincident with an unfavourable development of Crohn's disease. Because of the frequent young patient's age, they come along with a long life of suffering and high cost for treatment. Therefore a good clinical diagnostic and a balance between drug therapy and surgery is needed. In this report, we present the case of a 28-year old male patient with a complex system of fistula in Crohn's disease. Based on clinical and radiological findings we performed operative treatment in combination to immunosuppressive therapy as an interdisciplinary collaboration.

**Keywords:** Crohn's disease; Complex system of fistulas; Operative treatment

### Background

Crohn's disease has an incidence of 6.6 per 100,000 in southern Germany and is the most common form of inflammatory bowel disease beside ulcerative colitis [1]. The prevalence can be set at 100-200 per 100,000 [2]. Crohn's disease is diagnosed mostly during early adulthood. Accordingly the highest age-specific incidence is during the third decade of life [3]. This causes yearly expenses due to direct and indirect costs. Based on the patient's young age indirect costs e.g. for non-productive time or pensions are generated. It is expected, that the indirect costs represent approximately two third (64%) of the overall cost, whereas the daily drug therapy costs amount to 69% of the direct costs of 3500 to 6000 euro per patient and year [4]. Therefore early and correct diagnosis, as well as an optimized and interdisciplinary therapy is essential for a successful treatment.

The diagnosis of Crohn's disease is made by clinical history, examination, progression of disease and the combination of endoscopic, radiologic and blood tests. The initial blood tests should include leucocytes and C-reactive protein, the amount of iron, renal function and hepatic function as well. Genetic testing is not necessary. To exclude a non-inflammatory disease, it is recommended to perform a testing of faecal inflammatory markers as Calprotectin or Lactoferrin. These may also be used for follow-up. If there is high suspicion of an inflammatory bowel disease, an ileocolonoscopy with biopsies should be made. It should be complemented by esophagogastroduodenoscopy, if colonoscopy suggested that Crohn's disease is the probable underlying disease. A transabdominal and endoanal sonography or a MRI is made to detect extramural complications as abscesses or fistulas. To reduce radiation exposure, Computer Tomography (CT) should be performed in emergency settings solely [5].

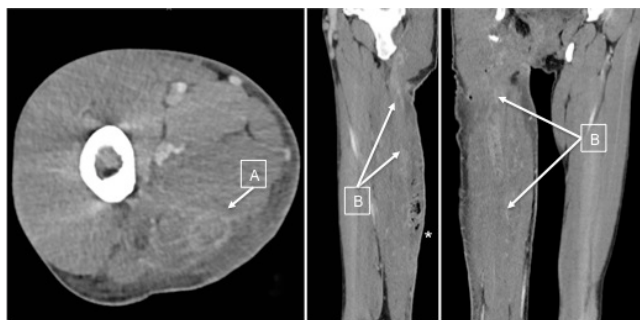
To reach an optimal monitoring of disease, the detection of CRP level or faecal inflammatory markers is useful. This should serve as a complement to the clinical condition of the patient. Transabdominal sonography is used as radiological control. In selected cases with unclear diagnostic findings or suspected complications, MRI, endosonography or endoscopy may be helpful [5].

### Case Presentation

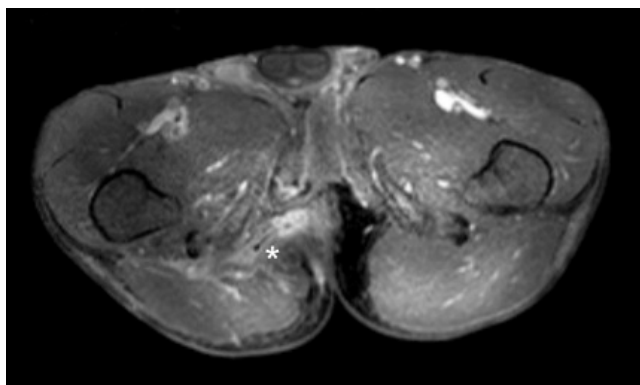
A 28-year old man was diagnosed with Crohn's disease at the age of seventeen. Prior to the diagnosis there were multiple surgical excisions of perianal abscesses and fistulas. Since the age of seventeen, the patient's drug therapy consisted of immunosuppressive azathioprine and 5-aminosalicylic acid and intermittent steroids. In 2011 the first complex fistula emerging at the right thigh was treated surgically at our institution. A laparoscopic sigmoidostomy was performed at the same time to allow the healing of the fistula. Three months later, after healing of the fistula, the stoma was closed. In the postoperative course the patient developed a leak of the anastomosis with a colo-cutaneous fistula. In the emergency CT-scan the left colon showed thickening consistent with Crohn's lesions. Therefore we performed revisional surgery with left colectomy and direct anastomosis. Treatment with anti-TNF antibodies was recommended after complete healing. This treatment was never installed.

After an uneventful period of three years, the patient presented to our emergency department and complained of a progressing reddened and swollen dorsal right thigh. Despite the absence of fever, the inflammatory markers were increased with Leucocytes (LC) of  $16.7 \cdot 10^9/l$  and C-Reactive Protein (CRP) of 182 mg/l. We diagnosed a recurrent abscess at the right thigh. The abscess perforated the skin dorsally and evacuated spontaneously. An antibiotic therapy with cefuroxime and metronidazole was installed after surgical incision and drainage of the abscess. In search for a recurrent fistula we performed a

CT with intravenous contrast medium. It showed a perianal fistula, with abscess, heading along the semimembranosus muscle (Figure 1). We decided to perform a Magnetic Resonance Imaging (MRI) of the right thigh and the pelvis (Figure 2) to explore the dimension of the fistula. The examination showed a complex system of fistulas along the ischiocrural muscles with a perforation at the dorsal thigh 10 cm above the knee, and a submucosal part towards the anus.



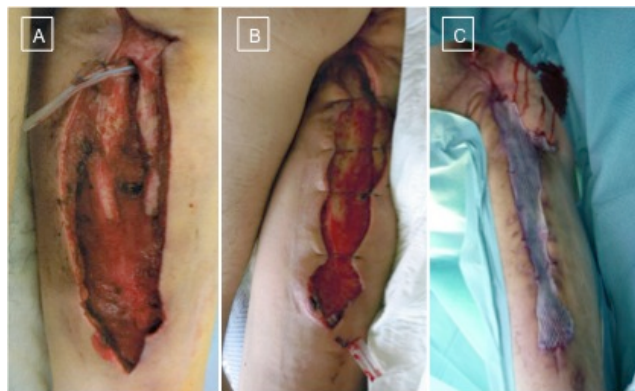**Figure 1:** Computed Tomography (CT) with axial, sagittal and coronal plane of the right thigh. (A) The posterior muscle compartment shows the marginal contrasted abscess and (B) the fistula heading along the posterior compartment. The perforation is marked by a star.



**Figure 2:** Magnetic Resonance Imaging (MRI) of the perianal region. Axial image showing the fistula at 9 o'clock in lithotomy position before drainage marked by star.

The patient refused another stoma, for the fear of losing work. We performed a fistulotomy from the ischial tuberosity to the popliteal fossa as well as for the submucosal perianal part (Figure 3A). After radical excision of the affected tissue and splitting of the muscle compartment, we induced healing of the wound with regular dressing, until the surface of the wound could be minimized. The perianal part healed successfully (Figure 3B). The remaining wound was covered with a split-skin graft taken from the left thigh (Figure 3C). The skin-transplant healed. Colonoscopy and histology showed changes consistent with Crohn's disease. Therefore the antibody therapy with adalimumab was initiated and the patient was dismissed from the hospital. Nine month later he presented with a recurrent perianal abscess in the old wound, which was treated surgically and healed. One

year later the patient was meanwhile treated with adalimumab and azathioprine. He presented with two new fistulas and ten days later with a recurrent abscess at the right thigh, all treated surgically. The follow-up after the last surgery is now five months.



**Figure 3:** Right posterior thigh after surgical splitting of the fistula. (A) Proximal is the perianal drainage visible. (B) Wound after conditioning. (C) Wound after covering with split-skin graft.

## Discussion

This patient is challenging, because of the high complexity of his fistulas. Thereby it is important to diagnose correctly and promptly. To offer the optimal therapy to the patient it is necessary to act as an interdisciplinary team during the hospitalisation and afterwards.

The first-line therapy of Crohn's disease is an immunosuppressive therapy (azathioprine, methotrexate, TNF-alpha inhibitors). To avoid a long-term steroidal therapy, it is important to install an immunosuppressive therapy with other drugs in all patients. Especially in patients with predictors of an unfavourable development e.g. smoking, extensive affection of small intestines, young age (<40 years), perianal affection and use of steroidal drugs at diagnosis, it is essential to discuss an early installation of immunosuppressive drugs [6]. In conjunction with surgery an immunosuppressive therapy causes increased morbidity. It is therefore recommended to discuss perioperatively an interruption of the therapy, to decrease the rate of surgical complications like insufficiencies of the anastomosis or sepsis [7].

A special aspect of Crohn's disease is the appearance of perianal fistulas. The appearance of fistulas is combined with a complicated progress of disease and seriously limits quality of life. However, it is important to choose an interdisciplinary approach for the treatment [8]. A fistula should only be treated surgically, when it is symptomatic, as defined e.g. by pain or secretion. In this case, it is suggested to perform a seton placement or a fistulotomy [9]. Nevertheless the operative therapy is limited in complex fistulas. In these rare cases fistulotomy is not recommended, because of high risk of anal incontinence [10]. Additionally to the surgery an immunosuppressive therapy with anti-TNF-alpha antibody should be installed. This increases the healing of fistulas significantly [11]. Nevertheless the patients need continuous follow-up with inspection of the fistula and rectal palpation.

In the presence of a persistent problem with perianal fistulas with failure of healing, further surgical procedures may help to control the perianal situation. The patient may profit from the exclusion of the fistulas by a surgical stoma [12]. Thereby the extent of the underlying disease determines the position of the stoma. A relevant part of patients (10-40%) need a proctectomy, seldom a proctocolectomy as definitive treatment [13]. Absolute indications for surgery are the existence of fistulas with short bowel syndrome, fistulas to the vesicle, high-output fistulas or blind-ending retroperitoneal fistulas [14].

Summarized, it is essential to control patients with Crohn's disease regularly and interdisciplinary. Before surgery an exact diagnosis should be made to offer the best individual treatment for each patient.

## Conclusion

With this case report we aim to emphasize the importance of the diagnostic process in inflammatory bowel disease. Even if immunosuppressive therapy is the first line therapy for Crohn's disease, surgery is needed to control and treat severe complications like abscesses or fistulas.

## References

1. Ott C, Obermeier F, Thieler S, Kemptner D, Bauer A, et al. (2008) The incidence of inflammatory bowel disease in a rural region of Southern Germany: a prospective population-based study. *Eur J Gastroenterol Hepatol* 20: 917-923.
2. Molodecky NA, Soon IS, Rabi DM, Ghali WA, Ferris M, et al. (2012) Increasing incidence and prevalence of the inflammatory bowel diseases with time, based on systematic review. *Gastroenterology* 142: 46-54.
3. Loftus CG, Loftus EV, Harmsen WS, Zinsmeister AR, Tremaine WJ, et al. (2007) Update on the incidence and prevalence of Crohn's disease and ulcerative colitis in Olmsted County, Minnesota, 1940-2000. *Inflamm Bowel Dis* 13: 254-261.
4. Stark R, Konig HH, Leidl R (2006) Costs of inflammatory bowel disease in Germany. *Pharmacoeconomics* 24: 797-814.
5. Preiss JC, Bokemeyer B, Buhr HJ, Dignass A, Hauser W, et al. (2014) Updated German clinical practice guideline on "Diagnosis and treatment of Crohn's disease" 2014. *Z Gastroenterol* 52: 1431-1484.
6. Summers RW, Switz DM, Sessions JT, Becketl JM, Best WR, et al. (1979) National Cooperative Crohn's Disease Study: results of drug treatment. *Gastroenterology* 77: 847-869.
7. Myrelid P, Olaison G, Sjobahl R, Nystrom PO, Almer S, et al. (2009) Thiopurine therapy is associated with postoperative intra-abdominal septic complications in abdominal surgery for Crohn's disease. *Dis Colon Rectum* 52: 1387-1394.
8. O'Donoghue DP, Hyland JM (1997) Perianal Crohn's disease. *Eur J Gastroenterol Hepatol* 9: 235-236.
9. Buchanan GN, Owen HA, Torkington J, Lunniss PJ, Nicholls RJ, et al. (2004) Long-term outcome following loose-seton technique for external sphincter preservation in complex anal fistula. *Br J Surg* 91: 476-480.
10. Steele SR, Kumar R, Feingold DL, Rafferty JL, Buie WD (2011) Practice parameters for the management of perianal abscess and fistula-in-ano. *Dis Colon Rectum* 54: 1465-1474.
11. Present DH, Rutgeerts P, Targan S, Hanauer SB, Mayer L, et al. (1999) Infliximab for the treatment of fistulas in patients with Crohn's disease. *N Engl J Med* 340: 1398-1405.
12. Kasperek MS, Glatzle J, Temeltcheva T, Mueller MH, Koenigsrainer A, et al. (2007) Long-term quality of life in patients with Crohn's disease and perianal fistulas: influence of fecal diversion. *Dis Colon Rectum* 50: 2067-2074.
13. Galandiuk S, Kimberling J, Al-Mishlab TG, Stromberg AJ (2005) Perianal Crohn disease: predictors of need for permanent diversion. *Ann Surg* 241: 796-801
14. Buhr HJ, Kroesen AJ, Herfarth C (1995) Surgical therapy of recurrent Crohn disease. *Zuckschwerdt* 66: 764-773.