

## A Rare Complication of Gastrojejunostomy: Jejunogastric Intussusceptions

Kellil T\*, Rebai W, Rhaïem R and Ben Safta Z

Service of General Surgery, La Rabta Hospital, Tunisia

### Abstract

Jejunogastric intussusception (JGI) is a rare life-threatening complication of gastrectomy or gastrojejunostomy. Diagnosis of this condition has been reported to be difficult in most of the cases. An early diagnosis and urgent surgical intervention are essential to avoid mortality. We present a case of the characteristic US and CT findings of this entity.

**Keywords:** Gastrojejunostomy; Complication; Jejunogastric intussusceptions

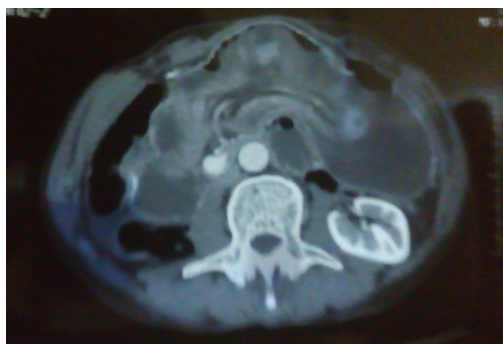
### Introduction

Jejunogastric intussusception (JGI) is a rare life-threatening complication of gastrectomy or gastrojejunostomy. Diagnosis of this condition has been reported to be difficult in most of the cases. An early diagnosis and urgent surgical intervention are essential to avoid mortality. We present a case of the characteristic US and CT findings of this entity.

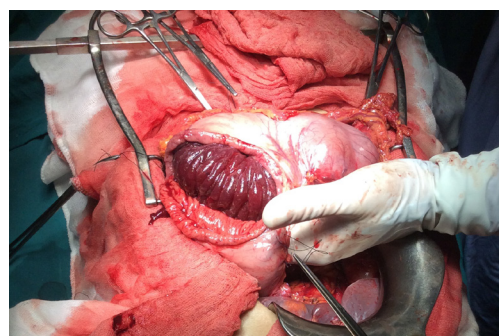
### Case Report

A 60-year-old man was referred for a surgical consultation for investigation of an acute, severe continuous abdominal pain and hematemesis. He had a prior midline laparotomy performed overseas 16 years ago for gastroduodenal ulcer complicated by stenosis. He would have a truncular vagotomy with gastrojejunostomy.

Physical examination found an agitated patient, suffering from abdominal pain. The patient was haemodynamically normal. He had a mild epigastric tenderness and a soft non-distended abdomen. Laboratory tests showed no anemia. However, leukocytosis and a functional renal failure were noted. Enhanced CT showed a distended stomach with an intragastric filling by bowel loop (Figure 1). A jejunogastric intussusception was selected as diagnosis. Emergent surgery confirmed that a simple gastrojejunostomy had previously been constructed with no gastric resection and revealed a severely dilated stomach stump and an efferent intestinal loop which had intussuscepted in a retrograde direction into the remnant gastric lumen, passing over the gastrojejunostomy (Figure 2). The reduce of the intussusception was impossible because of intestinal necrosis. The decision was to make a degastrogastroectomy carrying the anastomosis and the invaginated jejunal loops.



**Figure 1:** CT showing a distended stomach with an intragastric filling by bowel loop.



**Figure 2:** A dilated stomach stump and an efferent intestinal loop which had intussuscepted in a retrograde direction into the remnant gastric lumen, passing over the gastrojejunostomy.

### Discussion

First described by Bozzi, jejunogastric intussusception is an uncommon complication of gastrojejunostomy [1,2]. Occurrence is estimated at less than 0.1% [3]. Intussusception can occur many years following initial surgery, in our case it was 16 years.

The etiology of JGI is unclear. Two major theories are functional and mechanical [2]. The most widely accepted is the disordered motility with functional hyperperistalsis triggered by spasm or hyperacidity. Mechanical factors include adhesions, a long mesentery, gastric derangements, and sudden increase in abdominal pressure [3-6]. Depending on the involved loop, jejunogastric intussusception can be classified into three subtypes: type I contains the afferent loop, type II contains the efferent loop, and type III represents a combined form. It has been stated that type II is the most common (80%) [1-3]. Our case also fits into type II.

In the acute setting the patient typically presents as a surgical emergency with colicky epigastric pain, vomiting or hematemesis [3,4]. An epigastric or left upper quadrant mass may be palpated in less than 50% of patients.

Computed tomography (CT) scan shows intragastric

\*Corresponding author: Tarek Kellil, Service of General Surgery, La Rabta Hospital, Tunisia, Tel: +21671562083; E-mail: [kellilitarek10@gmail.com](mailto:kellilitarek10@gmail.com)

Received April 03, 2017; Accepted May 22, 2017; Published May 27, 2017

**Citation:** Kellil T, Rebai W, Rhaïem R, Ben Safta Z (2017) A Rare Complication of Gastrojejunostomy: Jejunogastric Intussusceptions. J Clin Case Rep 7: 968. doi: 10.4172/2165-7920.1000968

**Copyright:** © 2017 Kellil T, et al. This is an open-access article distributed under the terms of the Creative Commons Attribution License, which permits unrestricted use, distribution, and reproduction in any medium, provided the original author and source are credited.

intussusception and evaluate for the suspected strangulation [2]. Upper GI endoscopy helps in the diagnosis and can be therapeutic in reducing the intussusception [3].

Although spontaneous reduction was reported, in most cases surgical management should be performed as soon as possible to avoid the additional risk of severe complications [7]. This can range from simple reduction of the intussusception to resection and re-fashioning the gastroenterostomy [1]. Our case highlights how this unusual presentation needs to be considered even years after gastrojejunostomies.

## Conclusion

Jejunogastric intussusception is a recognized complication of gastroenterostomy formation. The diagnosis of Jejunogastric intussusception should be considered in all patients with a history of previous upper gastrointestinal operation presenting with unexplained severe abdominal pain, vomiting, or hematemesis. Early diagnosis and prompt surgical intervention are mandatory to avoid mortality.

## References

1. Fahy AS, Nickerson TP, Schiller HJ (2016) Retrograde jejuno gastric intussusception due to suture concretion. *Ann R Coll Surg Engl* 98: e45-e46.
2. Sharma OP, Saurabh G (2013) Imaging depiction of retrograde jejuno gastric intussusception. *Indian J Surg* 75: S269-S271.
3. Chao-Man L, Shu YH, Ying DC, Shian DC, Jiann MW, et al. (2014) Retrograde jejuno gastric intussusception: A case report and review of the literature. *Asian J Surg* 1-4.
4. Raj G, Thirthar PE, Sunny H, Rajakannu M, Vikram K (2014) Retrograde jejuno gastric intussusception following Braun's Jejunoejunostomy. *World J Clin Cases* 2: 24-26.
5. Shackman R (1940) Jejunogastric intussusception. *Br J Surg* 27: 475-480.
6. Tkue H, Tsushima Y, Arai Y, Endo K (1986) Jejunogastric intussusception: Life threatening complication occurring 55 years after gastrojejunostomy. *Inter Med* 48: 1657-1660.
7. Chowdhury SD, Dutta AK, Pal S, Leena RV, Chacko A (2011) Jejunogastric intussusception causing gastrointestinal bleeding. *Endoscopy* 43: E247.

**Citation:** Kellil T, Rebai W, Rhaïem R, Ben Safta Z (2017) A Rare Complication of Gastrojejunostomy: Jejunogastric Intussusceptions. J Clin Case Rep 7: 968. doi: [10.4172/2165-7920.1000968](https://doi.org/10.4172/2165-7920.1000968)

## OMICS International: Open Access Publication Benefits & Features

### Unique features:

- Increased global visibility of articles through worldwide distribution and indexing
- Showcasing recent research output in a timely and updated manner
- Special issues on the current trends of scientific research

### Special features:

- 700+ Open Access Journals
- 50,000+ editorial team
- Indexing at major indexing services
- Rapid review process
- Quality and quick editorial, review and publication processing
- Indexing at major indexing services
- Sharing Option: Social Networking Enabled
- Authors, Reviewers and Editors rewarded with online Scientific Credits
- Better discount for your subsequent articles

Submit your manuscript at: <http://www.omicsonline.org/submission//>