

A Rare Complication Related with Oral Anticoagulant (Warfarin) Use: Diffuse Alveolar Hemorrhage (above 65 Years 4 Case Reports)

Serap Duru*, Bahar Kurt, Merve Yumrukuz and Esra Erdemir

Dışkapı Yıldırım Beyazıt Training and Research Hospital, Chest Diseases Clinic, Ankara, Turkey

Abstract

Diffuse alveolar hemorrhage (DAH) caused by immune and non-immune etiological factors, characterized by diffuse alveolar consolidation often presents with the clinical triad of dyspnea, hemoptysis, anemia, as a result of the disruption of the alveolocapillary membrane of the lung. We aimed to present above 65 years 4 cases followed in our clinic with diffuse alveolar hemorrhage as a rare complication of uncontrolled use of anticoagulant (warfarin) therapy. The cases were diagnosed as diffuse alveolar hemorrhage based on clinical, radiological and bronchoscopic data. After warfarin treatment was withdrawn, clinical and radiological signs recovered rapidly and the existent situation was thought to be DAH related with warfarin use after excluding other reasons. We think that the current cases are a rare disease of warfarin therapy leading to DAH.

Introduction

According to World Health Organization data, elderly population in the world, which constantly increases, is expected to reach 1.2 billion by 2025 [1]. Due to chronic diseases occurring in this age group, the amount of drug used increases, hence they should be regularly monitored. Diffuse alveolar hemorrhage, is a disorder developing due to immune and non-immune etiological factors and characterized by shortness of breath, hemoptysis, anemia, and diffuse alveolar consolidation as a consequence of alveolocapillary membrane damage in lungs. Its most common causes are collagen tissue diseases, infectious or toxic exposures, neoplastic diseases, and pulmonary thromboembolism [2]. In the elderly population, oral anticoagulants are the most commonly used drugs in order to prevent thromboembolic complications. During treatment with oral anticoagulants, various bleeding complications may occur during treatment with oral anticoagulants but the development of DAH is quite rare [3,4]. The aim of the present report was to present four cases over the age of 65 who presented to emergency service consecutively due to DAH, which is a rare complication among warfarin associated hemorrhage.

Case Report

It was learned that 4 cases (2 females) over the age of 65 presenting to emergency service with the complaints of shortness of breath, cough and hemoptysis have used warfarin at an uncontrolled dose for the last three years. One used it for previous coronary bypass and atrial fibrillation while the other three for heart valve replacement. In physical examination, in one case with hypoxemic respiratory failure, blood pressure was found to be 100/70 mmHg, pulse 110/min, respiration rate 30/min and body temperature 37 degree. In the examination of cardiovascular system, tachycardia was seen and in respiratory system examination end inspiratory rales were present especially in infrascapular regions. In artery blood gas analysis, pH was found to be 7.40, PaCO₂ 32.6 mmHg, PaO₂ 55 mmHg and oxygen saturation 88%. Upper respiratory tract examination carried out by ear nose throat consultant yielded normal results. In the other three cases, vital findings were as follows: increase in respiratory rate (≥ 20 /min), tachycardia, body temperature 36 degree and in physical examination inspiratory rales in bilateral infrascapular regions. In all of the four cases, decrease in hemoglobin (<10 gr/dl), prolongation of prothrombin time (>10-14 second) and increase in INR levels (>3) were observed. **Coagulation parameters were shown Table 1.**

Other biochemical investigations were normal other than increase in serum creatinin level in one case. (>1.1 mg/d) two cases who had

respiratory failure and compliance problems could not undergo carbon monoxide diffusion test (DLCO). In two cases, increase in DLCO was established. Investigations for differential diagnosis of DAH. That is, cytoplasmic and perinuclear cytoplasmic antibody, antiglomerular basement membrane antibodies, antinuclear antibody, anti-dsDNA antibodies, complement level, rheumatoid factor, TORCH panel, serum D-dimer level, urinalysis and genetic examinations were found to be normal. When the history of being exposed to a toxic agent via inhalation, drugs used and smoking and drug habits were questioned, it was learned that two male patients had a smoking history of 15-20 pack-year, but did not have any clinical symptom of chronic airway disease. In order to rule out lung infections that can lead to the same clinical picture, in sputum ARB. And gram positive staining was made with detection of no pathogens. In echocardiographic examination, it was established that left ventricle functions were adequate (EF 60%) and one case had right atrial enlargement and minimal deficiency in tricuspid valve.

In posteroanterior chest radiographs, bilateral widespread alveolar opacities were detected, which were more pronounced in pericardiac and central areas (Figure 1). In thorax CT, patchy ground glass infiltration areas accompanied by scattered nodular-acinar densities were seen in both lungs (Figure 2). Although normal bronchial system was observed in fiberoptic bronchoscopy (FOB), hemorrhagic foci were observed on mucosa (Figure 3) and hemosiderin-laden macrophages were proven in the pathological examination of the bronchoalveolar lavage (BAL).

In hemorrhagic lavage fluid obtained, hemosiderin laden macrophages were observed in addition to erythrocytes. In lavage fluid, ARB was negative and there was no growth in culture. In cytological examination, no malignant cells were observed. Following supportive treatment including oxygen administration, vitamin K replacement,

*Corresponding author: Serap Duru, Dışkapı Yıldırım Beyazıt Research and Education Hospital, Ankara, Turkey, Tel: +90 505 3124191; E-mail: akcalis@hotmail.com

Received October 21, 2014; Accepted July 02, 2015; Published July 07, 2015

Citation: Duru S, Kurt B, Yumrukuz M, Erdemir E (2015) A Rare Complication Related with Oral Anticoagulant (Warfarin) Use: Diffuse Alveolar Hemorrhage (above 65 Years 4 Case Reports). J Pulm Respir Med 5: 268. doi:10.4172/2161-105X.1000268

Copyright: © 2015 Duru S, et al. This is an open-access article distributed under the terms of the Creative Commons Attribution License, which permits unrestricted use, distribution, and reproduction in any medium, provided the original author and source are credited.

Variables	Case 1	Case 2	Case 3	Case 4
White blood cell (/ul)	11,800	10,200	9,700	8,300
Hemoglobin (mg/dl)	8.4	8.9	9.4	7.9
Hematocrit (%)	28	29	30	31
Platelet count (/ul)	224,000	211,000	167,000	191,000
PT; second (INR)	65 (6.5)	51 (4.4)	46 (5.1)	73 (6.9)

PT: Prothrombin Time, INR: International Normalized Ratio.

Table 1: Coagulation parameters for diffuse alveolar hemorrhage cases.

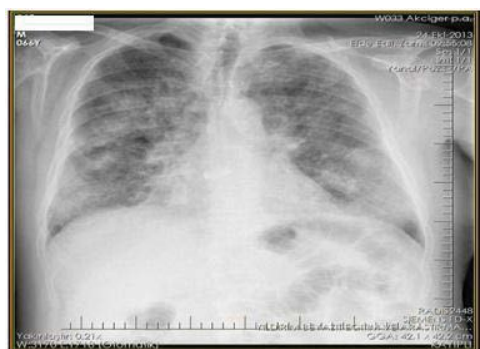


Figure 1: Posteroanterior lung graphy, widespread patched ground glass infiltrations in both lungs (Case 1).

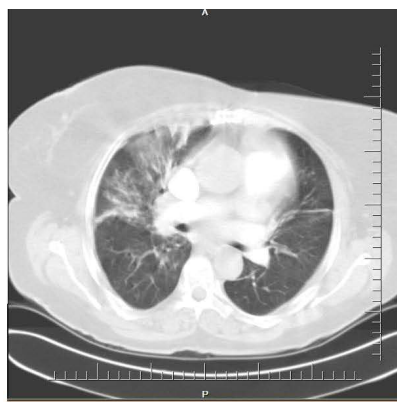


Figure 2: Widespread increase in alveolar density in the computerized tomography section (Case 2).

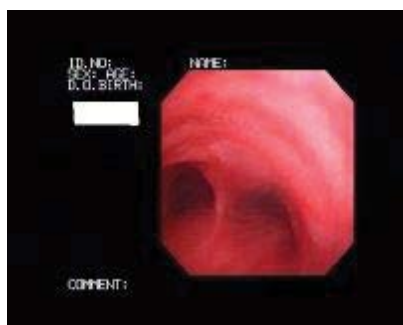


Figure 3: Fiberoptic bronchoscopy image. All mucous with edema and hemorrhagic foci in the mucosa of entrance to upper lobe of lung (Case 2).

and erythrocyte suspension and discontinuation of warfarin, clinical and radiological findings rapidly improved and our cases were discharged uneventfully.

Discussion

Diffuse alveolar hemorrhage complicating warfarin therapy may be a high mortality rate. Diffuse alveolar hemorrhage, which does not have a specific laboratory and clinic diagnosis method, leads to a clinical picture ranging from cough, hemoptysis, shortness of breath to respiratory failure particularly in elderly patients. When this clinical picture is observed in patients on warfarin and infiltrations are detected in direct lung graphy. Diffuse alveolar hemorrhage should be among infiltrative lung diseases that should be kept in mind in differential diagnosis [5]. Of our cases, consistent with this clinical spectrum, cough, hemoptysis and breathlessness was found in three, while in one additionally respiratory failure was seen.

In DAH, definitive diagnosis is made by lung tissue biopsy guided by fiberoptic bronchoscopy. Bronchoscopic biopsy may have risk of fatality due to excessive mucosal hemorrhagia and severe respiratory failure [6]. Our purpose of bronchoscopy is primarily to see the intra-alveolar blood, exclude endobronchial lesion and infection. In this case, the detection of hemosiderin laden alveolar macrophages in BAL with hemorrhagic appearance supports the diagnosis. Actually, the appearance of hemosiderin laden alveolar macrophages in our cases in BAL suggested the diagnosis of DAH.

There are many reasons in DAH etiology. Among collagen tissue diseases, Wegener granulomatosis [7,8], systemic lupus erythematosus [9,10] and Goodpasture syndrome [11], give rise to DAH owing to immun deposits in alveolar interstitium and intra-alveolar blood vessels. In addition, drugs such as cocaine, difenylhydantoin and leflunomid may lead to DAH [12]. We investigated other etiologic factors and serum levels of collagen tissue marker (C-ANCA, P-ANCA, ANA and anti ds-DNA) were analyzed. We did not find any problem for DAH in our cases. It is determined that the clinical picture in our cases is that of DAH which occurs rarely without any systematic involvement other than pulmonary involvement.

Warfarin is a commonly prescribed anticoagulant all over the world. Diffuse alveolar hemorrhage associated with warfarin was first described by Brown et al. [13]. Subsequently, limited number of cases have been presented [4,14]. Therefore, we believed that our series of four cases may contribute the literature regarding this subject. In a previous study, it was reported that of all cases followed in hospital with side effects of drugs, 10% was associated with warfarin [15,16]. Care should be exercised in the follow up patients on warfarin and it should be borne in mind that, it may lead to DAH, albeit rarely, which has high mortality unless diagnosed and treated early.

Conclusion

Diffuse alveolar hemorrhage is a life threatening complication which may develop due to many etiologic factors. World population is getting older and the elderly living alone is increasing in all over the world. So it is difficult to track medication use in the elderly. In warfarin associated DAH cases, especially elderly cases who regularly used the drug should be warned against the risk of hemorrhage and should be regularly monitored by clinicians. Early diagnosis is very important in DAH. The diagnosis must be clinically and radiologically and bronchoscopy.

References

1. World Health Organization (WHO). Elder maltreatment.

2. Ioachimescu OC, Stoller JK (2008) Diffuse alveolar hemorrhage: diagnosing it and finding the cause. *Cleve Clin J Med* 75: 258, 260, 264-265 passim.
3. Lee JH, Kim SW (2013) Successful management of warfarin-exacerbated diffuse alveolar hemorrhage using an extracorporeal membrane oxygenation. *Multidisciplinary Respiratory Medicine* 8: 16.
4. Erdogan D, Kocaman O, Oflaz H, Goren T (2004) Alveolar hemorrhage associated with warfarin therapy: a case report and literature review. *Int J Cardiovasc Imaging* 20: 155-159.
5. Schwarz MI, Cherniack RM, Talmadge E, King JR (2000) Diffuse Alveolar hemorrhage and other rare infiltrative disorders. In: Murray JF, Nadel JA (eds) *Textbook of Respiratory Medicine*. 3rd ed. W.B. Saunders Company 733-751.
6. Thomas JK, Jayaprakash K, Misiriya KJ, Khadar SA, Pappachan JM (2008) Catastrophic pulmonary alveolar hemorrhage complicating warfarin therapy. *J Assoc Physicians India* 56: 34.
7. Macri A, Stoica R, Ion I, Dănilă E, Tănăseanu S (2007) [Wegener granulomatosis with severe alveolar hemorrhagic syndrome]. *Pneumologia* 56: 137-141.
8. Cordier JF, Cottin V (2011) Alveolar hemorrhage in vasculitis: primary and secondary. *Semin Respir Crit Care Med* 32: 310-321.
9. Santos BH, Santos RR, Santos CF, Kakehasi AM, Von Tiesenhausen HA (2004) Pulmonary hemorrhage as a manifestation of systemic lupus erythematosus. *Rev Hosp Clin Fac Med Sao Paulo* 59: 47-50.
10. Lara AR, Schwarz MI (2010) Diffuse alveolar hemorrhage. *Chest* 137: 1164-1171.
11. Panek A, Walatek B, Sułowicz W (2013) [Goodpasture's syndrome--disease of many faces]. *Przegl Lek* 70: 218-223.
12. Waness A, Aldabbagh T, Harakati M (2009) Diffuse alveolar haemorrhage secondary to warfarin therapy for atrial fibrillation: a case report and literature review. *BMJ Case Rep* 2009.
13. Brown OL, Garvey JM, Stern CA (1965) Roentgenogram of the month. *Dis Chest* 48: 525-526.
14. Finley TN, Aronow A, Cosentino AM, Golde DW (1975) Occult pulmonary hemorrhage in anticoagulated patients. *Am Rev Respir Dis* 112: 23-29.
15. Pirmohamed M, James S, Meakin S, Green C, Scott AK, et al. (2004) Adverse drug reactions as cause of admission to hospital: prospective analysis of 18 820 patients. *BMJ* 329: 15-19.
16. Burmester JK, Berg RL, Glurich I, Yale SH, Schmelzer JR, et al. (2011) Absence of novel CYP4F2 and VKORC1 coding region DNA variants in patients requiring high warfarin doses. *Clin Med Res* 9: 119-124.

Citation: Duru S, Kurt B, Yumrukuz M, Erdemir E (2015) A Rare Complication Related with Oral Anticoagulant (Warfarin) Use: Diffuse Alveolar Hemorrhage (above 65 Years 4 Case Reports). *J Pulm Respir Med* 5: 268. doi:[10.4172/2161-105X.1000268](https://doi.org/10.4172/2161-105X.1000268)

Submit your next manuscript and get advantages of OMICS Group submissions

Unique features:

- User friendly/feasible website-translation of your paper to 50 world's leading languages
- Audio Version of published paper
- Digital articles to share and explore

Special features:

- 400 Open Access Journals
- 30,000 editorial team
- 21 days rapid review process
- Quality and quick editorial, review and publication processing
- Indexing at PubMed (partial), Scopus, EBSCO, Index Copernicus and Google Scholar etc
- Sharing Option: Social Networking Enabled
- Authors, Reviewers and Editors rewarded with online Scientific Credits
- Better discount for your subsequent articles

Submit your manuscript at: <http://www.omicsonline.org/submit/>