

Abdominal Scar Endometriosis and Hemothorax in a Nigerian Woman: A Case Report

Abayomi Ajayi¹, Victor Ajayi¹, Ifeoluwa Oyetunji¹, Oluwafunmilola Biobaku¹, Happiness Aikhuele¹ and Bamgboye M Afolabi^{2*}

¹Nordica Fertility Centre, 106 Norman Williams Street, Ikoyi, Lagos, Nigeria

²Health, Environment and Development Foundation, 34 Montgomery Road, Yaba, Lagos, Nigeria

*Corresponding author: Dr. Bamgboye M Afolabi, Health, Environment and Development Foundation, 34 Montgomery Road, Yaba, Lagos, Nigeria, Tel: +234(0) 803 049 0729; E-mail: bmafolabi@gmail.com

Received date: January 28, 2017; Accepted date: February 28, 2017; Published date: February 28, 2017

Copyright: © 2017 Ajayi A, et al. This is an open-access article distributed under the terms of the Creative Commons Attribution License, which permits unrestricted use, distribution, and reproduction in any medium, provided the original author and source are credited.

Abstract

We report here the unusual presentation of a 35-year-old nulliparous Nigerian teacher who presented with a 5-year history of primary infertility, painful menses and cyclical umbilical bleeding. Evaluation revealed a clinically stable woman with a midline, infra-umbilical surgical abdominal scar near the site of bleeding, a large right hemothorax on Chest X-ray, kissing ovaries on pelvic scan and abdominal mass on CT scan. Prior to presentation she had been histologically diagnosed with endometriosis in 2014 by laparoscopy and biopsy after several tests to rule out other conditions like tuberculosis. She had chest tube drainage of 800 ml of brownish, chocolatecolored fluid, 2 doses of GnRH agonist injection and eventually occlusion of the pleural space due to recurrence of hemothorax.

Keywords: Abdominal scar endometriosis; Cyclical umbilical Bleeding; Hemothorax

Introduction

Endometriosis, first pronounced as such by Rokitansky in 1860 [1], is defined as the existence of dynamic and functioning endometrial tissues, glands and stroma external to the uterine cavity. It has also been described as the masquerade of diseases because of its varied and sometimes disguised ways of presentation necessitating a high index of suspicion among medical practitioners in order not to miss it. When the fallopian tubes, ovaries and other organs in the pelvic peritoneum are involved, the lesion is labeled as pelvic endometriosis (PE) which occurs in 5-15% of women in child-bearing age group. When the lesion goes beyond the pelvis, to other parts of the body such as the abdomen, lungs, and the gastro-intestinal tract it becomes extra-pelvic endometriosis (EPE) a rare condition that occurs in 10-12% of cases of endometriosis. Ling and Lefebvre observed that, apart from the spleen, endometriosis implants have been reported in almost every organ [2]. They also observed that the occurrence of EPE decreases with increasing distance from the uterus, indicating that the highest concentration of EPE is in close proximity to the organs close to the uterus such as the lower gastro-intestinal tract, lower urinary tract such as ureter and urethra. The lungs are distant from the uterus but somehow, they are one of the common extra-pelvic sites of EPE [2] while the umbilicus and inguinal canals as well as the nervous system are proximal to the uterus, yet endometriosis rarely occurs in these locations [2]. This may be because of the direct hematological route of endometrial metastasis.

Case Report

A 35-year old married Nigerian woman, BP 116/60 mmHg and BMI of 21 kg/m², presented for the first time at our clinic in May 2016 with a 5-year history of primary infertility, inadequate coital frequency due

to severe (superficial and deep) dyspareunia, severe dysmenorrhea, vaginal discharge and galactorrhea. Her menstrual history indicated menarche at 13 years, 3-day duration of menses which were regular with moderate flow. She was not a known hypertensive, diabetic or asthmatic patient. She had an appendectomy in 2005 and myomectomy in 2013. A hystero-salpingography (HSG) done in 2013 confirm right tubal blockage prior to open myomectomy. In May 2014, she noticed a swelling with bleeding from the umbilicus during her menses which had occurred cyclically since onset. She also had painful heavy menstrual bleeding which led to her being admitted into a hospital. An abdomino-pelvic CT-scan was requested. She was histologically diagnosed with endometriosis by laparoscopy and biopsy. She was then put on Danazol treatment for 6 months. Family history showed that she was married in monogamy with no children to a 39-year-old teacher. She had no family history of similar painful menses or a prior diagnosis of endometriosis.

On examination, she was afebrile, not pale, not jaundiced and not dehydrated. Her chest was clinically clear with good air entry globally. There was no swelling in the neck.

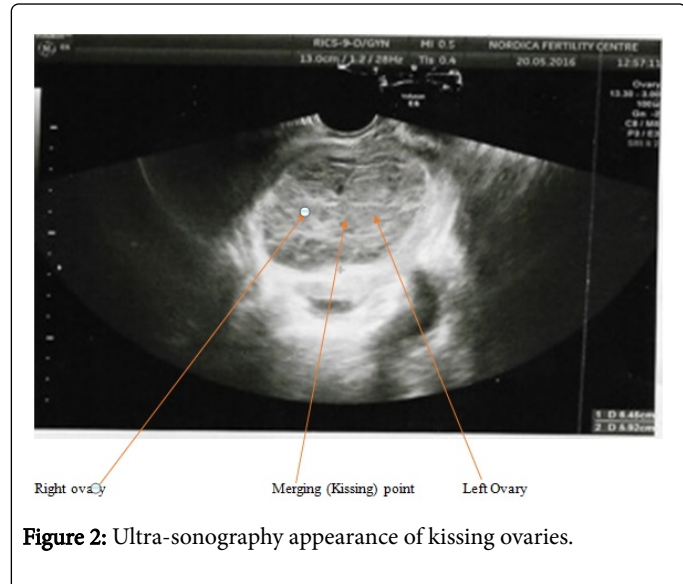
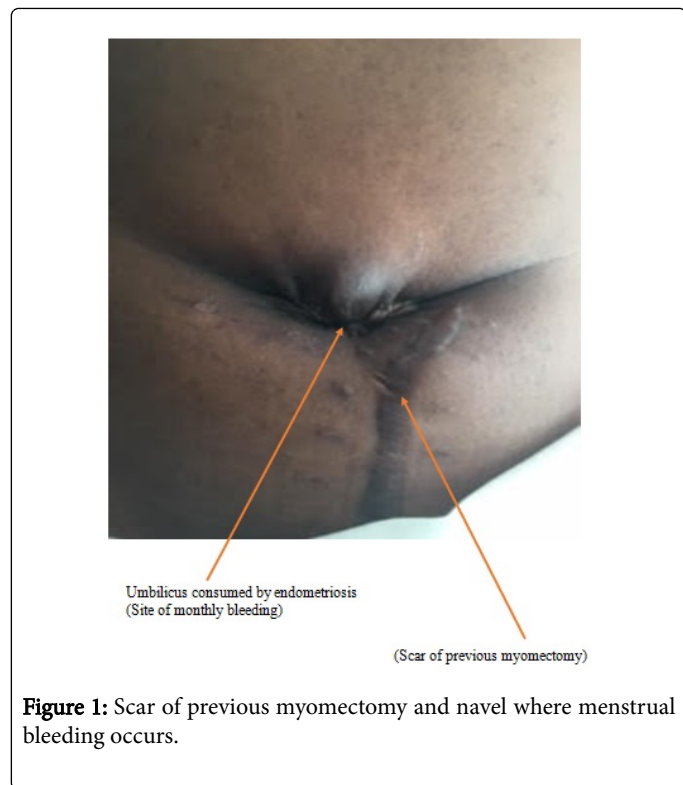
Abdominal examination

There was a hypertrophic scar of a midline vertical incision deviating to the left at its upper end as it approaches the umbilicus. Her abdomen was slightly tender to soft touch with inverted and puckered umbilicus which was the site of monthly bleeding and in fact appeared consumed (Figure 1). There was a non-tender swelling around the right midline surgical scar. The liver, spleen and kidneys were not enlarged.

Vaginal examination showed normal vulva and vagina with a healthy cervix.

On ultrasonography, her uterus was bulky in size (87.9 × 61.2 mm) with irregular endometrial plate echo. The endometrial thickness was 6.25 mm. There were three areas of circumscribed small-sized

hyperechoic areas in the uterine wall (intramural) which led to the suspicion of fibroid and/or adenomyosis. The ovaries were observed to be merged together (kissing) with a measurement of 64.5 mm across both ovaries (Figure 2).



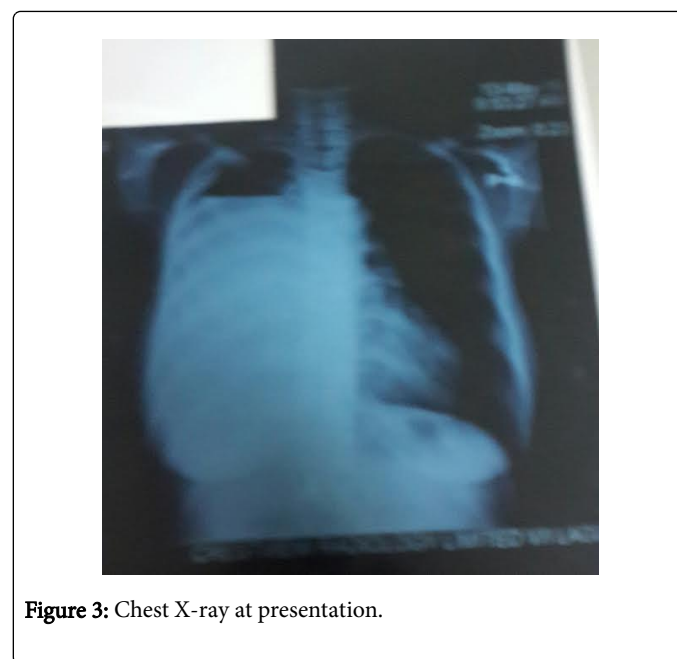
Our plan was to conduct an infertility work up as well as ovarian assay (follicle stimulating hormone and luteinizing hormone levels), serology (Human Immuno-deficiency Virus, Hepatitis C Virus, Hepatitis B surface Antigen, Venereal Disease Research Laboratory test) and perform a chest x-ray. There was also a plan for barium meal and follow through to rule out entero-cutaneous fistula.

Result of pelvic CT-scan Investigation

An abdomino-pelvic CT-Scan was done in May of 2014 for an indication of a firm fixed abdominal mass. Following intravenous injection and oral ingestion of water soluble contrast agent, axial images were acquired from the level of the hemi-diaphragm to the public symphysis and images were documented in soft tissue windows. The demonstrated scannogram appear preserved. Axial images showed both ovaries enlarged and composed of hypodense cystic areas with interspersed solid areas both appear matted together and measured 8.6 cm (long) × 3.6 cm (AP). The uterus was seen splayed anteriorly by the enlarged ovaries. It was normal in size with preserved myometrial density and no residual fibroid seen. No free fluid was seen in the Pouch of Douglas (POD). There were matted umbilical lymphnode seen within the subcutaneous plane. There was a large well circumscribed cystic mass with hypodense fluid attenuation of its content. It is anterior to the pancreas and posterior to the stomach. It measured about 6.5 cm (long) × 5.6 cm (AP) showing ground glass internal content. The spleen, pancreas and the left kidney were preserved. The right kidney was normal sonographically. The liver was of normal size with preserve density. No secondary deposits were seen. There was a massive right-sided hemothorax but the left was preserved. The impressions were ovarian tumor with secondary deposits to the umbilicus and anterior abdominal wall; endometriotic cyst, omental cyst or pancreatic pseudocyst; and right-sided hemothorax. A provisional diagnosis of endometriosis was made at that time.

Chest X-ray

Based on the CT-scan report which indicated some fluid collection in the lungs, a Chest X-ray was ordered for (Figure 3). Large pleural effusion was observed in the right hemithorax extending to the apex. However, no significant displacement of the midline was noted. The costo-phrenic angles were preserved. The left lung field was clear and normal cardiac size and shape was apparent. The bony thorax was intact.



Drainage of the right pleural effusion was requested after which 800 ml of brownish chocolate colored fluid was drained and histological reports suggested reactive effusion.

About 2 months post-drainage and after receiving two doses of GnRH agonist, the patient complained of difficulty in breathing and a repeat chest X-ray (Figures 4 and 5) showed that there was right lung collapse with hemothorax, right mediastinal mass and right costophrenic sulcus.

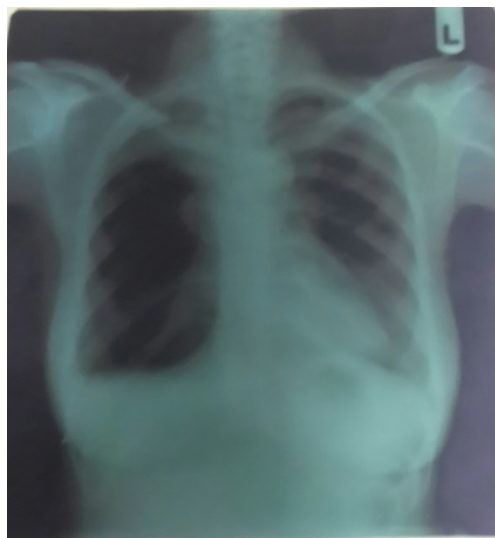

Figure 4: Postero-anterior view of Chest X-ray after drainage.

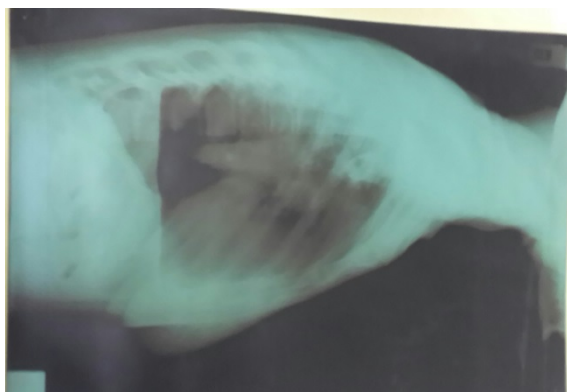


Figure 5: Lateral view of Chest X-ray after drainage.

Barium meal and follow-up

There was a persistent narrowing with an extrinsic impression at the lower third of the greater curvature. There was no indication that the umbilical bleeding was connected to the gastro-intestinal tract (Figure 6).

Treatment

On account of recurrent hemothorax she had occlusion of the pleural space (pluerodesis) done and was then planned for In-Vitro Fertilization to treat her infertility.

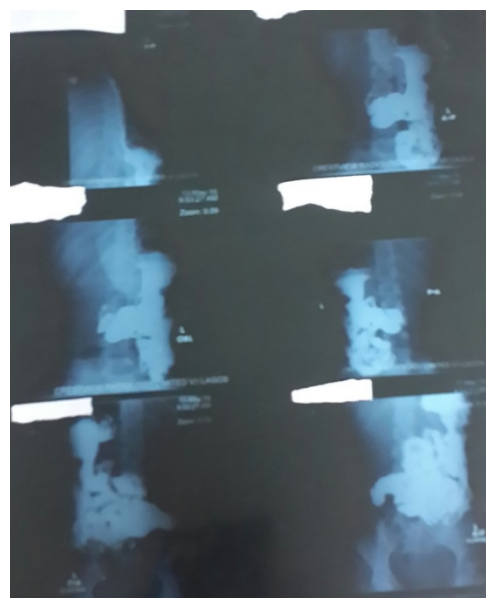

Figure 6: Barium meal and follow through.

Discussion

We present a case of a 38-year old Nigerian woman who presented with cyclical bleeding at the umbilicus close to the site of a previous gynecological incision. The presentation of focal incisional pain at the time of menses was similar to what Seydel et al. had described as the most frequent presentation of scar endometriosis, presence of bluish or black mass, cyclical bleeding and differential diagnosis of hernia, lipoma, granuloma and carcinoma [3].

Earlier, Steck and Helwig noted that the abdominal wall, umbilicus, labia and perineum are often involved in cutaneous endometriosis [4]. In the present case, there was a trio of (i) painful monthly cyclic bleeding associated with menstruation, (ii) a palpable abdominal mass suspected to be endometrial tissue around the surgical incision mark and (iii) history of previous gynecological or obstetric surgery myomectomy. This is similar to what Miccini et al. had documented [5]. In fact, her first surgical operation was an appendectomy which may or may not have any association with the diagnosis of umbilical endometriosis. Endometriosis located at a surgical scar is probably a result of iatrogenic transplantation of endometrial cells from probably the pelvis into the incision. Ling and Lefebvre observed that, after Caesarean Section (CS), the incidence of scar endometriosis is said to be 0.5% which increases to 1.0% after hysterectomy [2]. The incidence of scar endometriosis after open myomectomy is not yet conclusive.

Thoracic endometriosis is rare. More than 100 cases have been reported and lesions may affect the lung parenchyma or pleura and in up to 50-80% of cases there will be coexistent pelvic endometriosis which is often times severe [6]. Spread to the lungs have been theorized to occur via lymphatic or haematogenous spread or

transport of circulating peritoneal endometrial cells across the diaphragmatic fenestrations [2]. This may give more credence to the observation that right sided thoracic involvement is more common due to clockwise intraperitoneal circulation. The case we reported had affectation of the right side of the lung. Even though the most common thorax involvement is pneumothorax [7] other manifestations include haemothorax as seen in our patient. Others are hemoptysis and chest pain.

The place of CT scan in the diagnosis of extra-pelvic endometriosis has been explained as physical examination alone and Chest X-ray may not be diagnostic. CT scan was done in this patient and it was through this that the large hemothorax was picked as the client was otherwise clinically stable following history and chest examination.

A high recurrence rate after using medical treatment like OCPs, GnRH agonist as used in this case as well as Danazol has been observed [8]. Pleurodesis or excision of the lesion may be necessary in recurrent cases [9]. The former was done in the reported case on account of recurrent hemothorax despite GnRh agonist treatment. Pleurodesis shows lower recurrence rates compared with hormonal treatment [6].

Abdominal scar endometriosis is an uncommon clinical event. It is the presence of functional endometrial tissue near or inside an abdominal surgical incision [5] as seen in the reported case. This diagnosis can be made preoperatively as there is usually a triad of underlying mass as reported in this case, cyclical menstrual scar pain (in this reported case it was more of a case of dysmenorrhea and cyclical umbilical bleeding near the scar) and history of previous gynaecological or obstetric surgery. Our client had an open myomectomy with a midline scar extending to near the umbilicus and noticed symptoms shortly after.

Conclusion

This is an uncommon presentation of endometriosis. Physicians must look beyond the usual pelvic manifestations of endometriosis and must look out for the rare extra pelvic ones like hemothorax and abdominal surgical scar endometriosis such as have been presented in this case report even in otherwise clinically stable patients. Kissing ovaries which are almost pathognomonic of endometriosis may also be seen on scan. The umbilical manifestation may have spread following the open myomectomy.

References

1. Melgaard CA, Golbeck AL, Gresham L (1985) Current concepts in endometriosis. *West J Med* 143: 42-46.
2. Ling CM, Lefebvre G (2000) Extrapelvic Endometriosis: A case report and Review of the Literature. *J Soc Obstet Gynaecol Can* 22: 97-100.
3. Seydel AS, Sickel JZ, Warner ED, Sax HC (1996) Extrapelvic endometriosis: diagnosis and treatment. *Am J Surg* 171: 239-241.
4. Steck WD, Helwig EB (1965) Cutaneous endometriosis. *JAMA* 191: 101-104.
5. Miccini M, Gregori M, Ferraro D, Ciardi A, Cassibba S, et al. (2016) Abdominal scar endometriosis: case report. *Clin Exp Obstet Gynecol* 43: 431-433.
6. Joseph J, Sahn SA (1996) Thoracic endometriosis syndrome: new observations from an analysis of 110 cases. *Am J Med* 100: 164-170.
7. Carter EJ, Etensohn DB (1990) Catamenial pneumothorax. *Chest* 98: 713-716.
8. Espauella J, Armengol J, Bella F, Lain JM, Calaf J (1991) Pulmonary endometriosis: conservative treatment with GnRH agonists. *Obstet Gynaecol* 78: 535-537.
9. Joseph J, Reed C, Sahn SA (1994) Thoracic endometriosis: recurrence following hysterectomy with bilateral salpingo-oophorectomy and successful treatment with talc plurodesis. *Chest* 106: 1894-1896.