

Accident Vasculaire Cerebral Ischemique Post-Chimiotherapie Pour Cancer De La Langue Ischemic Stroke Induced by Chemotherapy for Tongue Cancer

Loum B*, Lame CA, Mboup C, Thierno B Diallo, Cheikhna Ba Ndiaye and Malick Ndiaye

Universite Cheikh Anta Diop De Dakar, Senegal

Abstract

Introduction: Cancer chemotherapy is a provider of a wide spectrum of neurological complications. Such complication ischemic strokes are an unusual event with an incidence of 0.14%.

Objective: Report and comment on the observation of a patient who presented an ischemic stroke in the aftermath of chemotherapy for tongue cancer.

Observation: 47 years old patient without cardiovascular risk factor is followed for tongue cancer. She presented the waning of chemotherapy ischemic stroke confirmed by brain scan. Heart explorations are normal, and the etiologic biological assessment.

Discussion: The diagnosis of stroke after chemotherapy has been retained in our patient on the basis of the absence of vascular risk factor and negativity of etiological assessment, and the use of cisplatin and 5-fluorouracil, which have been implicated in the occurrence ischemic stroke. The occurrence of this complication depends on the type of drugs, and certain drug combinations and fall of several mechanisms that can be entangled.

Keywords: Stroke; Tongue cancer; Chemotherapy; Toxicity; 5-Fluorouracil

Introduction

Cerebral ischemic stroke is an unusual complication of chemotherapy, with an estimated frequency of 0.14% [1]. This is a serious event that changes the prognosis and quality of life of patients, and poses a real problem of care. We report the case of a patient who had an ischemic attack on chemotherapy.

Observation

Ms N.M., 47 years old, without cardiovascular risk factor, was followed for squamous cell carcinoma of the evolved tongue, beyond our surgical resources (Figures 1 and 2). An indication of radio-chemotherapy was then proposed. The patient was treated with chemotherapy based on 5-fluorouracil and cisplatin according to the following protocol: Cisplatin; 100 mg/m² of body surface area in 1 hour at day 1 and 5-fluorouracil; 1000 mg/m² of body surface area on days 1 to 5. Twenty four hours after the first cure of chemotherapy, she presented a paralysis of the left half body of brutal installation. The neurological examination found a left hemiplegia predominantly brachio-facial, with language disorder and left facial paralysis. A cerebral tomodensitometry (CT) without injection of contrast medium was performed and showed a range of hypodensity of the right sylvian territory (Figures 3 and 4). The etiologic assessment was negative. It included cardiovascular exploration (electrocardiogram, transthoracic heart ultrasound and doppler ultrasound of the neck vessels), a lipid assessment (LDL cholesterol, HDL, triglycerides) and inflammatory assessment. The diagnosis retained at the end of this review was the vascular accident on chemotherapy. Anticoagulant treatment has been established. The evolution was marked by a death 72 hours after the installation of the stroke.

Discussion

Ischemic strokes are common in cancer pathology, but ischemic stroke on chemotherapy remain a complication rarely reported in the literature [2-4]. To our knowledge, only 19 cases were published between 1987 and 2015, 15 of these cases were men and 4 women, with an average age of 47.5 years [2]. In a retrospective study by Li et al. Of

10,963 patients treated for various cancers, the incidence of stroke due to chemotherapy is less than 0.14%, and the frequency of complicated chemotherapy cycles by stroke is 0.035% [1]. It is a difficult diagnosis to be made, which can only be carried out in the absence of another cause of stroke, especially cardiac, and on chronological arguments: succession of events, interval with the administration drugs, and pharmacological arguments: known drug toxicity, possible drug combinations, and their biological effects. Studies in the literature show that the risk of ischemic stroke in chemotherapy does not appear to be related to the type of cancer but to the type of drug used [3,4]. Thus, in the cases reported the most incriminated drugs were cisplatin [5-8] which comes in 1st position and 5-Fluorouracil (5FU). Both were used in our patient. Cisplatin and 5FU may cause stroke, alone or in combination with other antimitotics [9]. The imputability of the patient's stroke to these drugs would therefore be the most likely. On the other hand, it was difficult, if not impossible, to specify which of the two drugs was responsible the more so because the accident occurred at the end of the cure and the two drugs involved were already administered. In the study by Li et al. [1], 62.5% of strokes occurred after cycle "1", suggesting a direct effect of chemotherapy. The free interval suggests an immunoallergic mechanism with a sensitization phase, whereas its absence suggests a direct toxic effect of drugs [6]. We think this was the case with our patient. Hemispheric infarcts are the most frequent: 13/16 in the study of Li et al. [1].

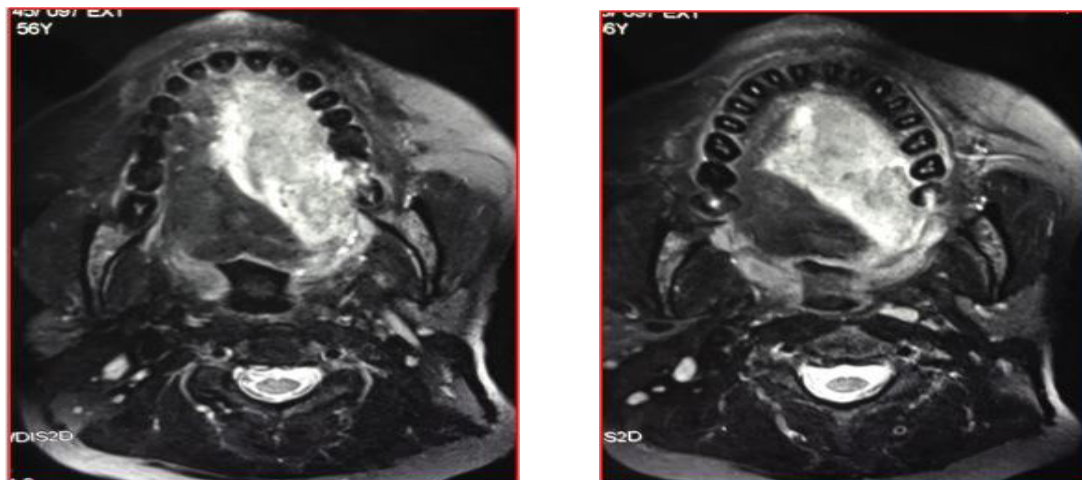
The physiopathology [6,3] of this complication is poorly elucidated,

*Corresponding author: Birame Loum, Universite Cheikh Anta Diop De Dakar, Senegal, Tel: +221338250530; E-mail: birameloumorl@yahoo.com

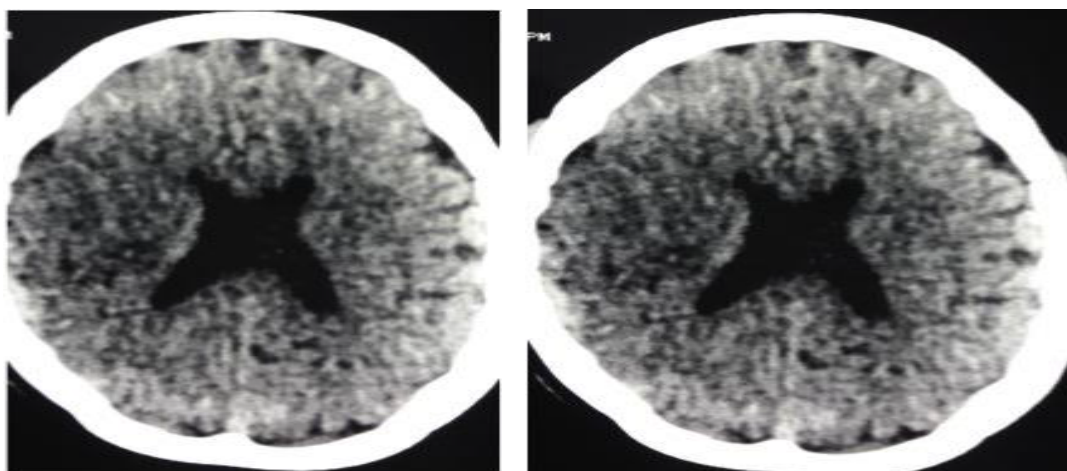
Received January 18, 2017; Accepted March 20, 2017; Published March 25, 2017

Citation: Loum B, Lame CA, Mboup C, Diallo TB, Ndiaye CB, et al. (2017) Accident Vasculaire Cerebral Ischemique Post-Chimiotherapie Pour Cancer De La Langue Ischemic Stroke Induced by Chemotherapy for Tongue Cancer. J Clin Case Rep 7: 944. doi: 10.4172/2165-7920.1000944

Copyright: © 2017 Loum B, et al. This is an open-access article distributed under the terms of the Creative Commons Attribution License, which permits unrestricted use, distribution, and reproduction in any medium, provided the original author and source are credited.



Figures 1 and 2: Facial MRI, evolved tumor process of the tongue.



Figures 3 and 4: Ischemic stroke; Hypodensity range of the right sylvian territory.

it could be:

- Direct toxicity on the vascular endothelium of anticancer agents (Methotrexate, 5FU, Cisplatin)
- A state of induced hypercoagulability (Asparaginase, 5FU)
- Through cardiac involvement (5FU, alkylating agents)
- Arterial vasospasm (5FU)
- Metabolic disorders (hypomagnesemia with cisplatin, hyperhomocysteinemia with methotrexate)
- Immuno-allergic reactions

Therapeutic attitudes vary according to the presence of associated risk factors, and the evolution of neoplasia, some authors have stopped chemotherapy [10] but most advocate the continuation of the same treatment. Preventive anticoagulant therapy has even been proposed with chemotherapy most at risk but has not been unanimous [6]. The prognosis seems to be darker, with only 3 cases of favorable changes (recovery of the neurological deficit) and a death rate of 5 cases out of

the 19 cases reported in the literature [2]. In the study of Li et al. [1], the average survival time is 4 weeks, but it remains essentially determined by the cancer disease. In our patient, the vascular accident resulted in death.

Conclusion

The causal link between chemotherapy and stroke, as well as the therapeutic attitude, is difficult to establish in the absence of a better understanding of pathophysiological mechanisms. Strict clinical and biological monitoring of patients during chemotherapy, especially with Cisplatin and 5FU, remains the only way to prevent this dreadful complication.

References

1. Li SH, Chen WH, Tang Y, Rau KM, Chen YY. 2006. Incidence of ischemic stroke post-chemotherapy: a retrospective review of 10,963 patients. *Clin Neurol Neurosurg* 108: 150-156.
2. Lytms S, Elmesnaoui L, Ait BH, Regragui EW, Benomar A (2013) Accident

- vasculaire cérébral ischémique post-chimiothérapie pour cancer du sein. AJNS.
3. Lebrun C, Frenay M (2010) Neurological complications of chemotherapy. J Inter Med 31: 295-304.
 4. Orbach D, Brisse H, Doz F (2003) Central neurological toxicity of chemotherapies: Current state of knowledge. Arch pédiatr 10 : 533-539
 5. Azak A, Oksüzöğlü B, Deren T, Oneç Bm, Zengin N (2008) Cerebrovascular accident during cisplatin-based combination chemotherapy of testicules germ cell tumor: An unusual case report. Anticancer Drugs. 19: 97-98.
 6. El Amrani M, Aidi S, Amarenco P (2003) Cerebral ischemic attacks and chemotherapy for cancer. Rev Neurol 159: 4371-4381.
 7. Etgen T, Weidenhöfer G, Kubin T (2009) Cisplatin-associated occlusion of the internal carotid artery. Oncology 754-757.
 8. Gamble TP (1998) Acute stroke following Cisplatin chemotherapy. Clin Oncol 10: 274-275
 9. Atkins JN, Muss HB (1991) High-dose 24 hour infusion of high dose 5-fluorouracil in metastatic prostate cancer. A phase II trial of the piedmont oncology association. Am J Clin oncol 14: 526-529.
 10. Ohashi S, Yazumi S, Nishio A, Fukui T (2006) Acute cerebral infarction during combination chemotherapy with s-1 and cisplatin for a young patient with a mucin-producing adenocarcinoma of the stomach. Inter Med 45(18): 1049-1053.

Citation: Loum B, Lame CA, Mboup C, Diallo TB, Ndiaye CB, et al. (2017) Accident Vasculaire Cerebral Ischemique Post-Chimiotherapie Pour Cancer De La Langue Ischemic Stroke Induced by Chemotherapy for Tongue Cancer. J Clin Case Rep 7: 944. doi: [10.4172/2165-7920.1000944](https://doi.org/10.4172/2165-7920.1000944)

OMICS International: Open Access Publication Benefits & Features

Unique features:

- Increased global visibility of articles through worldwide distribution and indexing
- Showcasing recent research output in a timely and updated manner
- Special issues on the current trends of scientific research

Special features:

- 700+ Open Access Journals
- 50,000+ editorial team
- Indexing at major indexing services
- Rapid review process
- Quality and quick editorial, review and publication processing
- Indexing at major indexing services
- Sharing Option: Social Networking Enabled
- Authors, Reviewers and Editors rewarded with online Scientific Credits
- Better discount for your subsequent articles

Submit your manuscript at: <http://www.omicsonline.org/submission/>