

Acting Out of the Ordinary: A Case of Sudden Death after Abnormal Behavior Due to a Craniopharyngioma

Amal Nishantha Vadysinghe¹, Paneetha Senavirathna², Achini Samaranayake¹ and Medhani Hasanthika Priyadarshi Wickramasinghe^{1*}

¹Department of Forensic Medicine, Faculty of Medicine, University of Peradeniya, Peradeniya, Sri Lanka

²District General Hospital, Polonnaruwa, Sri Lanka

Abstract

Introduction: We report a patient who initially presented with behavioral changes for a short period and then succumbed to unexpected death while on psychiatric treatment. The cause of death was found to be a craniopharyngioma at medico-legal autopsy.

Case report: A previously apparently healthy, 52-year old female, started showing disinhibited behavior such as removing clothes in public and was consequently treated with antipsychotics for two weeks. Behavioral symptoms improved gradually but she complained of intermittent difficulty in maintaining balance. A week later she was found dead at home in her bed. Medico-legal autopsy and subsequent investigations revealed severe cerebral edema resulting from a well formed craniopharyngioma with surrounding cystic degeneration at pituitary gland. The optic chiasma was partially displaced by the tumor. Moderate pulmonary edema was seen. Examination of other systems, toxicology and microbiological investigations were unremarkable. The cause of death was given as cerebral edema due to craniopharyngioma.

Discussion: The patient was initially treated as having a mental illness. This reflects the importance of excluding organic causes early and considering neurological assessment in previously well patients who suddenly presented with psychiatric symptoms. Autopsy findings are consistent with acute hydrocephalus due to growing brain tumor. The enlarged gland had encroached on the basal cisterna, obstructing the cerebral spinal fluid pathway, and causing acute hydrocephalus. This was speculated to have resulted in sudden death.

Conclusion: This case exemplifies the medico-legal autopsy role in determining causes of death.

Keywords: Craniopharyngioma; Sudden Death; Behavior; Autopsy

Introduction

The phenomenon of sudden, unexpected death is defined by the WHO as “a death within 24 hours from the onset of symptoms”. The causes of sudden unexpected deaths are numerous, the commonest cause of sudden death in Western nations being ischemic heart disease [1]. Sudden deaths related to the nervous system can be caused by meningitis, rupture of cerebral aneurysm or arterio-venous malformation, mycotic aneurysms [2], epilepsy [3] after a short period of abnormal behavior and few neurological symptoms.

Case Report

A 52-year-old mother of one child was found dead on her bed in her house. She had been on treatment for what had been presumed was a psychiatric illness for a period of two weeks. The death was reported to the office of the inquirer into sudden deaths (ISD) and an investigation was commenced with a scene visit by police and ISD. According to history given by family and information obtained through medical records, over the period of two weeks before death, the family has had noticed numerous behavioral changes in the deceased such as signs of disinhibition, including removal of clothes in the presence of others and an attempt to run away from home. She had been referred to a psychiatrist for this abnormal behavior and had been prescribed Olanzapine 5 mg bd. On further first line investigations it was found that she had no other apparent medical or surgical problems.

However, over the next one week period she had complained of some difficulty in maintaining her balance, which had occurred intermittently while attending to normal work. During follow up, she had been referred to a neurologist after disclosure of this complaint yet the family had not followed through with the referral. One week later after the referral was done, the patient had succumbed to death at home. After the routine medico-legal procedures, an inquiry to

perform a medico-legal autopsy had been issued to the forensic unit of district hospital Polonnaruwa, Sri Lanka as there had been no apparent cause of death.

On autopsy examination, the clothing and external examination was unremarkable except for a sublethal haemorrhage which was 2 × 2 cm in size situated over the right frontal upper forehead without evidence of skull fractures. The body weight of the deceased was 55 kg. In cranial dissection, the entire brain showed severe edema and cerebrospinal fluid was filled under tension in cerebral ventricles (Figure 1). The weight of the brain was 1.475 kg. The total brain surface and internal structures were free of bleeding or injury. The basal brain surface showed a well-formed mass measuring 1 × 1 cm with surrounding cystic degeneration of the pituitary gland. The optic chiasma was partially displaced (Figure 2). The enlarged gland had encroached into the basal cisterna and obstructing the CSF pathway and showing enlarged ventricular system. Moderate pulmonary edema was seen on both lungs. Gastrointestinal, genitourinary and cardiovascular systems were unremarkable. Histology examination revealed cerebral edema, and moderate pulmonary edema. The tissue sample from the mass was revealed as a craniopharyngioma on histology (Figure 3). There was

***Corresponding author:** Hasanthika Priyadarshi Wickramasinghe, Department of Forensic Medicine, Faculty of Medicine, University of Peradeniya, Peradeniya, Sri Lanka, Tel: +94767424567; E-mail: medhaniwickramasinghe89@gmail.com

Received July 23, 2016; **Accepted** November 24, 2016; **Published** November 30, 2016

Citation: Vadysinghe AN, Senavirathna P, Samaranayake A, Wickramasinghe MHP (2016) Acting Out of the Ordinary: A Case of Sudden Death after Abnormal Behavior Due to a Craniopharyngioma. J Clin Case Rep 6: 891. doi: [10.4172/2165-7920.1000891](https://doi.org/10.4172/2165-7920.1000891)

Copyright: © 2016 Vadysinghe AN, et al. This is an open-access article distributed under the terms of the Creative Commons Attribution License, which permits unrestricted use, distribution, and reproduction in any medium, provided the original author and source are credited.

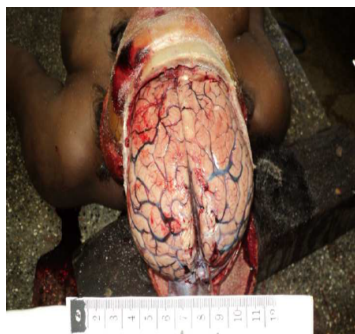

Figure 1: Cerebral edema.

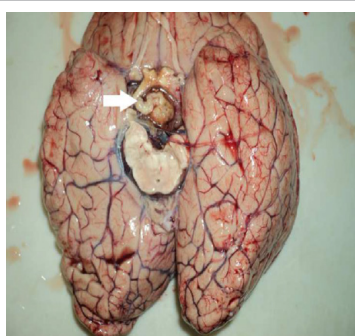


Figure 2: Mass measuring the 1 × 1 cm near the pituitary gland with cystic degeneration.

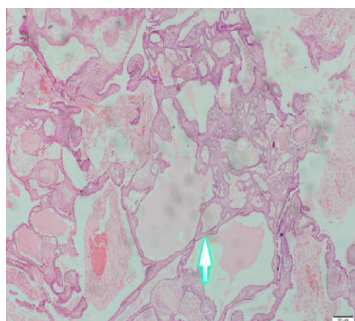


Figure 3: Craniopharyngioma composed of nests and trabeculae of epithelium in a fibro-collagenous stroma that has undergone cystic degeneration. Central cells are loose and termed 'stellate reticulum' (H&E X40).

no evidence of tumor infiltration to local areas. Toxicology of blood was negative for common poisons and drugs. All microbiological investigations were negative. Cause of death was given as cerebral edema due to craniopharyngioma, and circumstance of death was concluded as natural following an inquest.

Discussion

In the light of the autopsy findings, few queries needed to be answered. Firstly, whether the patient's initial disinhibited behavior, and the on- and-off loss of balance that was considered innocuous were, in fact manifestation of the brain tumor. Secondly, how the craniopharyngioma could have led to an unexpected death. Literature defines Craniopharyngioma as "benign tumours that develop in cell rests of Rathke's pouch, and may be located within the sella turcica, or commonly in the suprasellar space". Craniopharyngiomas are typically slow growing tumors. They can occur in patients of any age, but there

are two peaks in incidence, one in childhood (10-14 years), and one in young to middle-aged adults [4-6]. They arise from the pituitary stalk and project into the hypothalamus. Even though they have benign histology, the tumor can behave malignantly, extending into surrounding structures like the pituitary, hypothalamus, optic nerves, or the third ventricle [7]. They are often cystic with a solid component that may or may not be calcified [3].

They can present with a variety of symptoms such as pressure effects on adjacent structures, hypopituitarism, cranial diabetes insipidus and/or clinical features related to hypothalamus damage such as hyperphagia and obesity, loss of the sensation of thirst and disturbance of temperature regulation [3]. The pressure effects on the optic chiasma will cause visual disturbances and the pressure effects on the mass will cause headache. Endocrine abnormalities are especially pronounced in adult patients, where secretion of growth hormone, gonadotrophins, ACTH and TSH are affected [8].

If the symptoms and signs are not severe or if there were misinterpreted, tumors can go undiagnosed and progressively grow in resulting in sudden death [9]. The most intriguing aspect of this case is that this patient initial presentation of behavioral changes. She had shown unusual behavior such as taking her clothes off while in the company of others, and had been difficult to control. In retrospect, this could be interpreted as disinhibited behavior. In psychology, disinhibition defined as "a lack of restraint manifested in disregard for social conventions, impulsivity, and poor risk assessment. Disinhibition affects motor, instinctual, emotional, cognitive, and perceptual aspects with signs and symptoms similar to the diagnostic criteria for mania. Hypersexuality, hyperphagia, and aggressive outbursts are indicative of disinhibited instinctual drives [10].

Disinhibition is frequently due to non-organic causes such as mania [11] which is the obvious reason this patient was referred to a psychiatrist. It can also be seen in cases organic causes such as frontal lobe damage [12], fronto-temporal dementia [13], brain lesions such as closed head injuries, brain tumors, stroke lesions, focal epilepsy [14]. This had been a critical oversight in the management of this patient.

Behavioral changes have been reported in craniopharyngioma patients, especially in adults [7]. This is probably due to extension of tumor into frontal and temporal areas. The presentation of craniopharyngioma patients with symptoms of mania is very rare, but there have been few cases reported [15].

In this patient, the initial presentation had been recognized as a psychiatric illness, and promptly treated as such. Later on, when the other neurological symptoms and signs such as instability and loss of balance had had developed and become pronounced, a referral to a neurologist was done. This reflects on the importance of excluding organic causes in patients who present with psychiatric symptoms.

Cerebral tumors, commonly have often been reported to culminate in sudden unexpected death. The incident of estimated by literature is at 0.16% of all autopsy cases in a medical officer's office [9]. As the author states, majority of it (50%) consists of astrocytoma-glioblastoma category. The first author reports a case of sudden death due to a colloid cyst of the third ventricle [16]. However, the authors could not find any reports of unexpected deaths due to Craniopharyngiomas in the literature.

There was no macroscopic or microscopic evidence to suggest any other possible causes of death. Furthermore, there was no evidence of poisoning or viral infection. Therefore, the second query is how the

tumor could've caused a sudden death. Post-mortem examination revealed severe cerebral edema. This was consistent with acute hydrocephalus due to growing brain tumor. The enlarged gland had encroached into the basal cisterna, probably obstructing the cerebrospinal fluid pathway, and causing acute internal hydrocephalus. Edema like change is frequently reported to have been caused by craniopharyngiomas in the literature [17]. This was speculated to have resulted in sudden death.

Conclusion

Craniopharyngioma can present as behavioral changes and can cause sudden death in individuals. It is important to perform medico-legal death investigations including autopsy in unexpected deaths. It reemphasizes the importance of excluding the organic diseases in patients presenting with abnormal behavior, especially in previously healthy middle aged individuals.

References

1. Knight B, Saukko P (2004) Knight's forensic pathology (3rd edn.) CRC Press.
2. Spitz WU (2005) Spitz and Fisher's Medicolegal investigation of death: Guidelines for the application of pathology to crime investigation (4th edn.) Charles C Thomas Pub Ltd.
3. Nouri S, Balish M (2015) Sudden unexpected death in Epilepsy: Overview autopsy.
4. Chin LS (2015) Colloid cysts: Treatment and management.
5. Colledge NR, Walker BR, Ralston SH (2010) Davidson's principles and practice of medicine (21st edn.) Churchill Livingstone.
6. Stanislavsky A, Gaillard F (2015) Craniopharyngioma. Radipeadia.org.
7. Zoicas F, Schoff C (2012) Craniopharyngioma in Adults. Front Endocrinol (Lausanne).
8. Shalet SM, Toogood A, Rahin A, Brennan BMD (1998) The diagnosis of growth hormone deficiency in children and adults. Endocrine rev. 19: 203-223.
9. Di Maio VJM, Dana SE (1999) Natural Disease. Handbook of Forensic Pathology. Viva book private Ltd. 50.
10. Grafman J, Boller F, Berndt RS, Robertson IH, Rizzolatti G (2013) Handbook of Neuropsychology. Oxford University Press. 103.
11. WHO. The ICD-10 classification of mental and behavioural disorders: Clinical descriptions and diagnostic guidelines.
12. Baird AD, Wilson SJ, Baldin PF (2007) Neurological control of human sexual behavior: Insight from lesion studies. J Neurol Neurosurg Psychiatry 78: 1042-1049.
13. Zamboni G (2008) Apathy and disinhibition in frontotemporal dementia insights into their neural correlates. Neurology 71: 736-742.
14. Starkstein SE, Robinson RG (1997) Mechanism of disinhibition after brain lesions. J Nerv Ment Dis 185: 108-114.
15. Prusty GK, Subramanya, Hemalatha V, Narayanan HS (1982) Craniopharyngioma presenting as Mania-Case Report. Indian J Psychiatry 24: 305-306.
16. Vadysinghe AN, Wickramasinghe CD (2011) Sudden death due to a colloid cyst of the third ventricle: Case report. Medico-legal J Sri Lanka 1: 42-45.
17. Saeki N, Uchino Y, Murai H (2004) MR Imaging study of edema-like change along the optic tract in patients with pituitary region tumours. Am J Neuroradiol 24: 336-342.