

Acute Cholecystitis in Two Patients Carrying a Situs Inversus: A Diagnostic and Therapeutic Challenge

Anis Haddad*, Amine Sebai, Souhaib Atri, Amine Daghfous and Zoubeir Ben Safta

Department of Surgery, La Rabta Hospital, Tunis, Tunisia

Abstract

The situs inversus is a rare anatomical condition which is characterized by the transposition of organs towards the opposite side. The left position of the gall-bladder makes the diagnosis of acute cholecystitis difficult because of an unusual symptomatology. It is also associated with a difficulty of laparoscopic dissection of the stone-block triangle especially for the right-handed surgeons. We report the cases of 2 patients whose different explorations confirmed the diagnosis of acute cholecystitis and total situs inversus and benefited from a laparoscopic cholecystectomy. Laparoscopic cholecystectomy, in these two cases, is an original intervention because of the mirrored vision of the intraperitoneal organs and can even be difficult leading to iatrogenic complications. However, the laparoscopic approach remains the gold standard even in the presence of this mirrored anatomy.

Keywords: Gallbladder; Cholecystitis; Cholecystectomy

Introduction

The situs inversus is a rare anatomical condition which is characterized by the transposition of organs towards the opposite side. Its incidence is estimated from 1/10000 to 1/20000. The left position of the gall-bladder makes the diagnosis of acute cholecystitis difficult because of an unusual symptomatology. It is also associated with a difficulty of laparoscopic dissection of the stone-block triangle especially for the right-handed surgeons. We report the cases of 2 patients carrying a totalsitus inversus who benefited from a laparoscopic cholecystectomy for acute cholecystitis.

Case Report

Case 1

Sir. B, 58-year-old, male was hospitalized for a painful and feverish syndrome of the left hypochondrium. The physical examination found an anicteric patient with fever at 38.5°C and a defense of the left hypochondrium.

The chest X-ray of the thorax (Figure 1) showed a dextrocardia suggesting the diagnosis of situs inversus. Pre, per and post-operative findings are summarized in (Table 1). Abdominal ultrasound confirmed the diagnosis of acute cholecystitis and total situs inversus. The patient was operated on under laparoscopy with a standard installation: surgeon between the patient's legs, the first aid at the right of the patient. The trocars were then introduced: The first trocar of 10 mm at the level of the umbilicus (for the camera), the second trocar of 10 mm at the level of the right side, then two other trocars of 5 mm respectively into the left iliac pit and into the epigastrium. Thus, the disposal of the trocars was the symmetric of the usual provision (Figures 2 and 3). The exploration intraoperative confirmed the diagnosis of acute cholecystitis and the situs inversus (Figure 4). First, we proceeded to the liberation of the

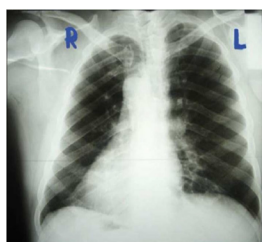

Figure 1: Chest X-ray showing dextrocardia.

Variables	Case 1	Case 2	Cholecystectomy for acute cholecystectomy with a right sided gallbladder
Fever	38.5°C	38.1°C	38.2°C
Abdominal pain	Left hypochondrium	Left hypochondrium	Right hypochondrium
Wall defense	Yes	Yes	Yes
WBC (/mm ³)	16740	12000	13500
CRP (mg/l)	140	70	90
Operative time (min)	60	75	45
Drainage	No	No	No
Postoperative temperature	37.2°C	37.4°C	37.5°C
Time of first bowel movement	24 hours after surgery	24 hours after surgery	24 hours after surgery
Mobilization of the patient	12 hours after surgery	12 hours after surgery	12 hours after surgery
Antibiotics	C3G+Metronidazole *15 days	C3G+Metronidazole *15 days	C3G+Metronidazole *15 days
LMWH	Enoxaparine 4000 UI, one injection/day, for 5 days	Enoxaparine 4000 UI, one injection/day, for 5 days	Enoxaparine 4000 UI, one injection/day, for 5 days
Pain killer	Paracetamol	Paracetamol	Paracetamol
Wound healing	One week	One week	One week
Hospital staying	3 days after surgery	3 days after surgery	3 days after surgery

Table 1: Pre, per and post operative findings of the patients.

epiploon of the gallbladder. After puncture draining of the gallbladder (hydrocholecystis), a dissection of the canal and the cystic artery in hook with the left hand was made (Figure 4). After clipping and section of the

*Corresponding author: Anis Haddad, Department of Surgery, La Rabta Hospital, Tunis, Tunisia, Tel: +216 71 562 083; E-mail: anis.haddad2015@icloud.com

Received March 30, 2017; Accepted July 22, 2017; Published July 27, 2017

Citation: Haddad A, Sebai A, Atri S, Daghfous A, Safta ZB (2017) Acute Cholecystitis in Two Patients Carrying a Situs Inversus: A Diagnostic and Therapeutic Challenge. J Clin Case Rep 7: 1000. doi: 10.4172/2165-7920.10001000

Copyright: © 2017 Haddad A, et al. This is an open-access article distributed under the terms of the Creative Commons Attribution License, which permits unrestricted use, distribution, and reproduction in any medium, provided the original author and source are credited.

canal and the Cystic artery (Figures 5 and 6), retrograde cholecystectomy was performed. Finally, the gallbladder was extracted in a bag.

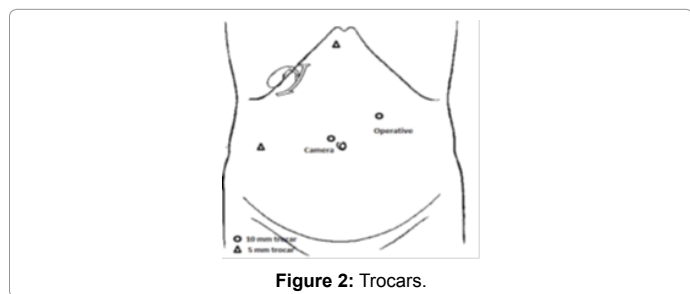


Figure 2: Trocars.

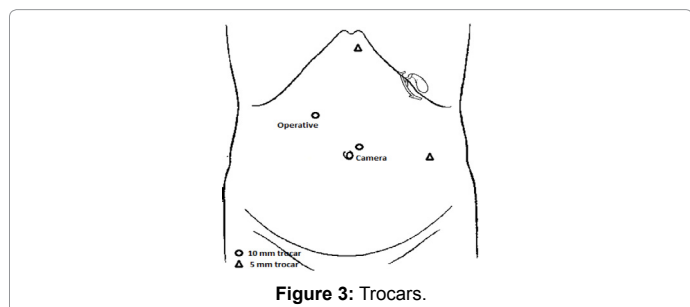


Figure 3: Trocars.

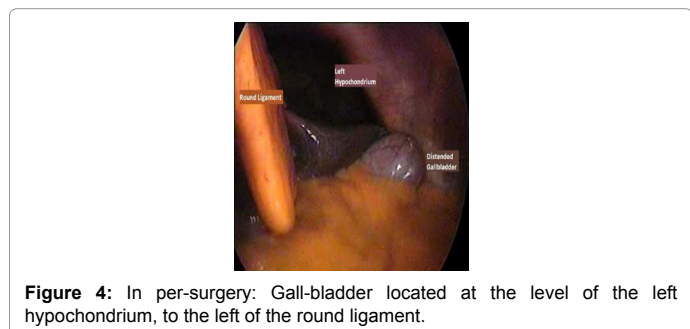


Figure 4: In per-surgery: Gall-bladder located at the level of the left hypochondrium, to the left of the round ligament.

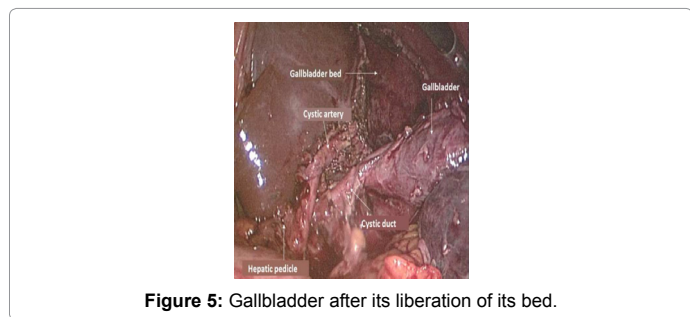


Figure 5: Gallbladder after its liberation of its bed.

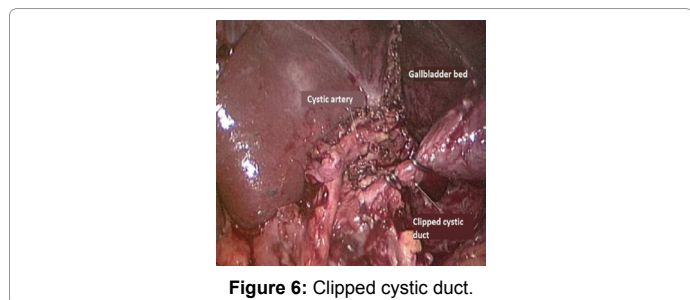


Figure 6: Clipped cystic duct.

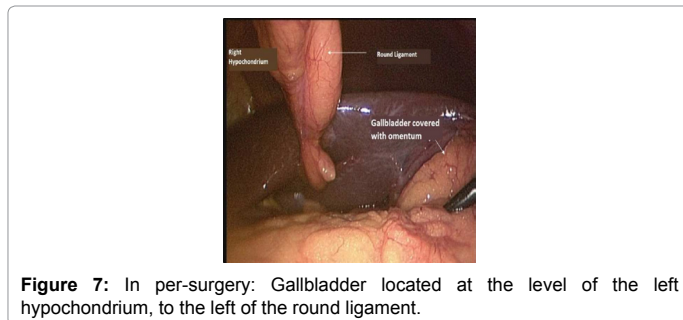


Figure 7: In per-surgery: Gallbladder located at the level of the left hypochondrium, to the left of the round ligament.

Case 2

Mr. SN, 54-year-old, male was hospitalized for fever and pain of the left hypochondrium. This patient was known carrier of a situs inversus complete. The radiological and biological explorations confirmed the diagnosis of acute cholecystitis on total situs inversus. The patient was operated then under laparoscopy with the same installation and provision of the trocars as in the first observation. Intraoperative exploration confirmed the diagnosis of cholecystitis (Figure 7). Pre, per and post-operative findings are summarized in Table 1.

Discussion

The situs inversus is a rare anatomical condition which is characterized by the transposition of organs towards the opposite side. Its incidence is estimated from 1/10000 to 1/20000 [1]. Two types are described: the partial situs inversus in which either the intrathoracic organs or those intra-abdominal are transposed and the complete situs inversus in which all the organs are transposed. It can join certain anomalies such as bronchiectasis, sinusitis and a deficit of the tracheobronchial lashes entering then within the framework of a syndrome of Kartagener. In such patients, acute cholecystitis usually manifests as a painful and feverish syndrome of the left hypochondrium. However, in 30% of cases, there are isolated epigastric distress and in 10% of cases a painful and feverish syndrome of the right hypochondrium [2]. This is explained by the fact that the central system may not be converted [3]. Diagnosis is difficult in this atypical presentation, especially if the patient is not known carrier of a situs inversus. However, it should be mentioned if the chest X-ray found a dextrocardia or if a right axis is highlighted by the ECG of the patient. Other explorations, and in particular the abdominal ultrasound, will allow to make the diagnosis of acute cholecystitis and situs inversus.

Only 67 cases of laparoscopic cholecystectomy with situs inversus were listed in the literature until now [4]. The laparoscopic access of the gall bladder, in case of a situs inversus, is difficult especially for the right-handed surgeons, and this may lead to lesions of the principal bile duct while dissecting the stone-block triangle especially that the anatomical alternatives of the bile ducts are more frequent in the event of a situs inversus. Several adaptations of the surgical technique were described [2,5-10]. For our two patients, the symmetry of the usual disposition of the trocars was carried out. The cholecystectomy was more laborious than for a subject with "a right gallbladder" but not especially difficult.

Conclusion

Situs inversus is a rare anatomical situation that makes the diagnosis of acute cholecystitis difficult due to a left symptomatology. Laparoscopic cholecystectomy, in this case, is an original intervention because of the mirrored vision of the intraperitoneal organs and can even be difficult leading to iatrogenic complications. However, the laparoscopic approach remains the gold standard even in the presence of this mirrored anatomy.

References

1. Reddy A, Paramasivam S, Alexander N, Abhilash, Ravisankar V, et al. (2014), Management of a patient with situs inversus totalis with acute cholecystitis and common bile duct stones: A case report. *Int J Surg Case Rep* 5:821-823.
2. Phothong N (2015) Simplified technique of laparoscopic cholecystectomy in a patient with situs inversus: A case report and review of techniques. *BMC Surg* 15: 23.
3. Raghuvveer MN (2014) Laparoscopic cholecystectomy in situs inversus totalis. *J Clin Diagn Res* Jul 8: ND03-ND05.
4. Alsabek MB, Alsabek B, Arafat S, Aldirani A (2016) A case report of laparoscopic cholecystectomy in situs inversus totalis: Technique and anatomical variation. *Int J Surg Case Rep* 28: 124-126.
5. Eisenberg D (2009) Cholecystectomy in situs inversus totalis: A laparoscopic approach. *Int Med Case Rep J* 2: 27-29.
6. Fernandes MN, Neiva I, Camacho F, Meguins L, Fernandes M, et al (2008) Three-port laparoscopic cholecystectomy in a Brazilian Amazon woman with situs inversus totalis: Surgical approach. *Case Rep Gastroenterol* 2: 170-174.
7. Patle NM, Tantia O, Sasmal PK, Khanna S, Sen B (2010) Laparoscopic cholecystectomy in situs inversus our experience of 6 cases. *Indian J Surg* 72: 391-394.
8. Hall TC, Barandiaran J, Perry EP (2010) Laparoscopic cholecystectomy in situs inversus totalis: Is it safe? *Ann R Coll Surg Engl* 92: W30-W32.
9. Arya SV, Das A, Singh S, Thukral BB (2013) Technical difficulties and its remedies in laparoscopic cholecystectomy in situs inversus totalis: A rare case report. *Int J Surg Case Rep* 4: 727-730.
10. Ali MS, Attash SM (2013): Laparoscopic cholecystectomy in a patient with situs inversus totalis: Case report with review of literature. *BMJ Case Rep* 2013.

Citation: Haddad A, Sebai A, Atri S, Daghfous A, Safta ZB (2017) Acute Cholecystitis in Two Patients Carrying a Situs Inversus: A Diagnostic and Therapeutic Challenge. J Clin Case Rep 7: 1000. doi: [10.4172/2165-7920.10001000](https://doi.org/10.4172/2165-7920.10001000)

OMICS International: Open Access Publication Benefits & Features

Unique features:

- Increased global visibility of articles through worldwide distribution and indexing
- Showcasing recent research output in a timely and updated manner
- Special issues on the current trends of scientific research

Special features:

- 700+ Open Access Journals
- 50,000+ editorial team
- Indexing at major indexing services
- Rapid review process
- Quality and quick editorial, review and publication processing
- Indexing at major indexing services
- Sharing Option: Social Networking Enabled
- Authors, Reviewers and Editors rewarded with online Scientific Credits
- Better discount for your subsequent articles

Submit your manuscript at: <http://www.omicsonline.org/submission/>