

## Acute Myocarditis Induced by Phenylenediamine

Salmi A\*, Métali A, Ameer A, Slimani M and Messaif D

Department of Medical and Surgical Emergencies, University Hospital Center Mustapha (Pr.M. Guerinik), Algiers, Algeria

\*Corresponding author: Amine Salmi, Department of Medical and Surgical Emergencies, University Hospital Center Mustapha, Algiers, Algeria, Tel: 0663503399; E-mail: salmi\_amine@yahoo.fr

Received date: September 02, 2016; Accepted date: October 05, 2016; Published date: October 07, 2016

Copyright: © 2016 Salmi A, et al. This is an open-access article distributed under the terms of the Creative Commons Attribution License, which permits unrestricted use, distribution, and reproduction in any medium, provided the original author and source are credited.

### Abstract

Paraphenylene diamine (PPD) is used as a hair dye. Poisoning causes this very often in the hours following acute respiratory distress, which can be life-threatening, and acute renal failure in the early days, requiring very often extra renal purification sessions. Past the Cape of asphyxiation and that of acute renal failure, the prognosis can be put into play by the installation of myocarditis, rare complication of PPD, as evidenced by our observation, whose outcome was favourable.

**Keywords:** Paraphenylene diamine; Myocarditis; Rhabdomyolysis

### Introduction

The intoxication paraphenylène- diamine (PPD) is formidable even at very low doses, since it causes a high mortality [1]. The initial

clinical features were dominated by respiratory distress and the installation of acute renal failure by rhabdomyolysis, and rarely by myocarditis, which remains a serious complication, since it can put into life-threatening. This is the case of our patient who presented, in addition to acute renal insufficiency and acute respiratory distress, myocarditis.



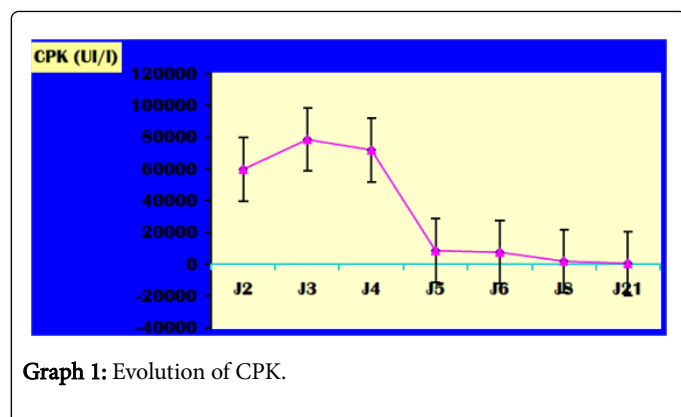
**Figure 1:** Blackish coloration of urine, J2 after ingestion of the diamine paraphenylène. note the normal appearance of urine (J4 after ingestion).

### Case Presentation

A 28-year old woman, married with two children, hospitalized two hours after deliberate ingestion of PPD for care of acute respiratory distress with head and neck edema, having justified an emergency tracheotomy, given the impossibility of endotracheal intubation. Laboratory work found high creatine phosphokinase (CPK) [59850 UI/l]. The urinary pH was lower than 6. The rest of the biological assessment was without anomalies.

The téléthorax and ECG were no anomalies. The change was mainly marked by the appearance of acute renal failure, oliguric, with dark colored urine (Figure 1), having justified symptomatic treatment, based on abundant rehydration, on average 12l/J, alkaline. The objective was to obtain a urine pH sup. 6.5.

While the patient was asymptomatic, ECG done at J6 of hospitalization was without defects, with dosage troponin Tc, which were 50 times normal. The diagnosis of a toxic myocarditis was strongly suspected, confirmed by echocardiography, which objectified hypokinesia with a lower dyskinesia anteroseptal without impaired left ventricular function (ejection fraction =60%) with pericardial separation, and confirmed by cardiac MRI, done three weeks later. The development, clinical and biological (Graph 1) was favorable, and the patient was in décanulée 10ème jour successfully.



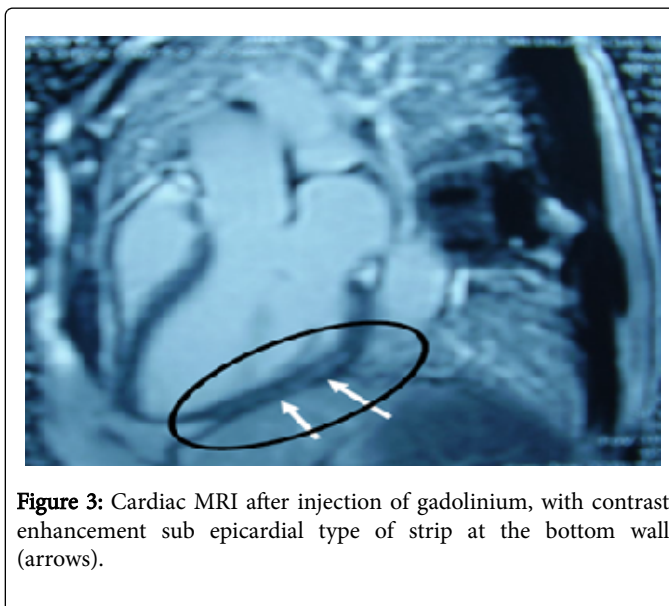
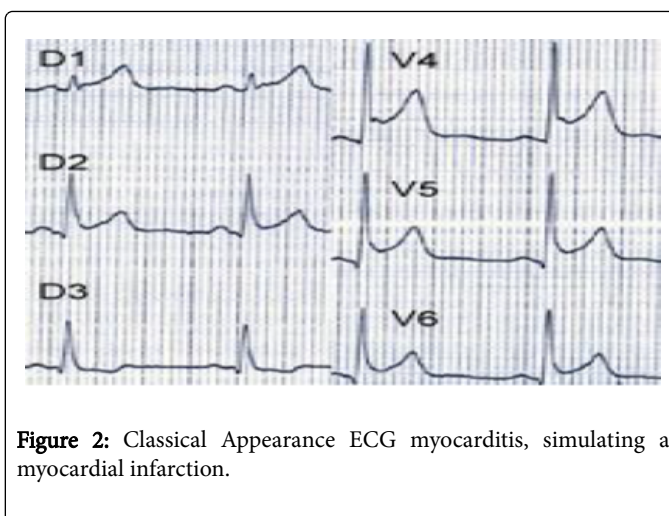
## Discussion

The clinical picture of ingestion to PPD, the lethal dose in humans is estimated at 10 g, is initially dominated by respiratory signs, type of acute respiratory distress accompanied often with head and neck edema, one of the mechanisms would be an allergic component, which settled a few hours, 15-20 minutes to 2-6 hours (2 hours for our patient) after ingestion. This respiratory distress often arises indicating a rescue tracheotomy [2,3], explained by the difficulty, see the impossibility of endotracheal intubation, which was the case in our patient. The respiratory impairment further comprises, rhabdomyolysis respiratory muscles, including the diaphragm, causing a superimposed respiratory exhaustion. Finally, acute respiratory distress syndrome (ARDS) remains possible with late onset, to the 4-5th day [4].

Cardiac involvement documented for the first time in 1995 in connection with myocarditis, which remains underestimated and poorly documented, was the subject of recent publications that have an update on a new clinical aspect of these poisonings, and appears to be dose-related PPD ingested. It could be a direct attack of myocardial fiber membrane lipid peroxidation and calcium storage of inhibition by the sarcoplasmic reticulum to the origin of a calcium overload [5].

It should be suspected in electrical signs: diffuse ischemia injury, tachycardia and ventricular fibrillation, ST elevation mimicking a wave Pardee (Figure 2), premature ventricular preceding ventricular tachycardia and ventricular fibrillation, biological perturbation (increased troponin I, severe rhabdomyolysis) or before the appearance of a shock.

This myocarditis often results in an overall collapse of hypokinesia with ejection fraction (EF) on echocardiography, which was not the case for our patient: EF=60%. Cardiac MRI (Figure 3), baseline examination confirmed the diagnosis of myocarditis by late contrast enhancement in intra myocardial or epicardial under which is a different specific element of ischemic pathology [6-8].



**Figure 2:** Classical Appearance ECG myocarditis, simulating a myocardial infarction.

**Figure 3:** Cardiac MRI after injection of gadolinium, with contrast enhancement sub epicardial type of strip at the bottom wall (arrows).

In the short term, myocarditis can compromise the prognosis for heart failure, refractory cardiogenic shock, ventricular arrhythmias see sudden death. Moreover, it can become chronic causing dilated cardiomyopathy [9,10]. The evolution is favourable in most cases, with healing without sequelae, but the risk of dilated cardiomyopathy or sudden death should alert the clinician by early diagnosis and, consequently, a specialized care.

The patient was put under antiplatelet agent and an ACE inhibitor, after consulting specializing in cardiology.

## Conclusion

If respiratory distress represents the classical clinical form of intoxication to PPD, the search for a cardiac complication, myocarditis, must be systematic, by performing an ECG and its repetition, the cardiac enzymes, completed at least by echocardiography, this will reduce the short-term morbidity and mortality, and specialized long term follow up, given the unpredictable evolution of the cardiac complication.

---

## References

1. Moutaouakil S, Elmouknia M, Benslama A, Chara M, Menbhi L, et al. (1999) Intoxication à la paraphénylène diamine. *Les cahiers du médecin* 22: 10-13.
2. Squali J, Drissi R (1991) Toxicité systémique au PPD. À propos d'un cas. *Cah Anesthesiol* 39:559-560.
3. l'intoxication à la paraphénylène -diamine au Maroc p.769 , urgences 2008,SFMU.
4. Yabe K (1992) The effect of a p-phenylenediamine containing hair dye on the Ca<sup>2+</sup> mobilization in the chemically skinned skeletal muscle of the rat. *Nippon Hoigaku Zasshi* 46: 132-140.
5. Abdel-Aty H, Boyé P, Zagrosek A, Wassmuth R, Kumar A, et al. (2005) Diagnostic Performance of Cardiovascular Magnetic Resonance in Patients With Suspected Acute Myocarditis. *JACC* 45: 1815-1822.
6. Hunold P, Schlosser T, Vogt FM, Eggebrecht H, Schmermund A, et al. (2005) Myocardial Late Enhancement in Contrast-Enhanced Cardiac MRI: Distinction Between Infarction Scar and Non-Infarction-Related Disease. *AJR* 184: 1420-1426.
7. Mahrholdt H, Goedecke C, Wagner A, Meinhardt G, Athanasiadis A (2004) Cardiovascular magnetic resonance assessment of human myocarditis: a comparison to histology and molecular pathology. *Circulation* 109: 1250-1258.
8. Doolan A (2004) Causes of sudden cardiac death in young Australians. *Med J Aust* 180: 110-112.
9. Phillips M (1986) Sudden Cardiac Death in Air Force Recruits. A 20-Year Review. *JAMA* 256: 2696-2699.
10. Eckart RE (2004) Sudden death in young adults: a 25-year review of autopsies in military recruits. *Ann Intern Med* 141: 829-834.