

## Amyloidosis: Laboratory and Clinical Perspectives

Esma Evrim Dogan, Fahri Şahin and Guray Saydam\*

Division of Hematology, Department of Internal Medicine, Ege University, Izmir, Turkey

### Abstract

Amyloidosis is a general name for a group of rare diseases, which may end up with progressive organ damage and death as a result of the accumulation of the low-molecular-weight subgroups of normal serum proteins, after their precipitation in the extracellular tissues in the form of cross- $\beta$ -folded fibrillar aggregates, which are resistant to proteolysis. More than 30,000 different proteins are produced in human cells. The first product of the protein synthesis is a linear amino acid chain (primary structure). AL amyloidosis, which is also called primary amyloidosis, is the most common and most aggressive type of systemic amyloidosis with an annual incidence of 8.9/1,000,000 in Western countries. The common signs and symptoms of AL amyloidosis are fatigue, weight loss, syncope, peripheral edema, dyspnea, diarrhea or constipation. The clinical suspicion is the first and the most important step for the diagnosis of amyloidosis. All patients with a visceral amyloid syndrome need therapy in AL amyloidosis. The goals of the current treatment approach of systemic AL amyloidosis includes rapidly reduction in the supply of the monoclonal amyloidogenic light chain by eradicating the plasma cell or B cell clone to prevent the new amyloid formation and facilitate the clearance of the existing amyloid deposits and, also supportive care to sustain the function of the organ involved and maintaining the quality of life.

**Keywords:** Amyloidosis; Amyloid proteins; Immunoglobulin light chains; Precursor proteins

### Introduction

Amyloidosis is a general name for a group of rare diseases, which may end up with progressive organ damage and death as a result of the accumulation of the low-molecular-weight subgroups of normal serum proteins, after their precipitation in the extracellular tissues in the form of cross- $\beta$ -folded fibrillar aggregates, which are resistant to proteolysis.

The term “amyloid” was used by Rudolph Virchow for the first time in 1854 [1]. More than 60 amyloid proteins were identified so far and 27 of them are human fibrillar proteins [2,3].

Although, amyloidosis was classified as primary, secondary and hereditary amyloidosis in the past, today the classification is based on the amyloid protein content. Amyloidosis, which proceeds with the accumulation of immunoglobulin light chains or fragments, is called AL amyloidosis (primary) and which proceeds with the accumulation of the acute phase reactant serum amyloid A secondary to inflammation, infection or malignancy, is called AA amyloidosis (secondary). Amyloidosis, which proceeds with the accumulation of  $\beta$ 2-microglobulins, is called dialysis-related amyloidosis and which proceeds with the accumulation of mutant transthyretin, is called ATTR (hereditary). Another type of amyloidosis, which emerges due to the accumulation of mutant lysozymes, is called as ALys amyloidosis (hereditary) and which proceeds with the accumulation of mutant fibrinogen A alpha, is called as Fib A amyloidosis (hereditary) etc. [1,4,5].

Furthermore, amyloidosis might be classified as systemic or local amyloidosis according to the distribution of the amyloid proteins [6]. In the systemic amyloidosis, precursor proteins are expressed in one or more tissues, which could spread through blood vessels to accumulate in other organs, from where they are secreted. In localized amyloidosis, precursor proteins may accumulate in the intracellular and extracellular space in the tissue or organ, where they are secreted. While, in Parkinson's disease and Huntington's disease, which are related to localized amyloidosis, the accumulation occurs in the intercellular space; in Alzheimer's disease, which is another neurodegenerative disease, intracellular Tau protein fibrils are found concomitantly with the extracellular  $\beta$ -amyloid fibrils [7].

Although, AL light chain amyloidosis, systemic senile amyloidosis,

ATTR amyloidosis, AA amyloidosis, dialysis-related amyloidosis proceed with systemic amyloidosis, the most common type of amyloidosis is AL light chain amyloidosis. The second most common systemic amyloidosis is transthyretin type amyloidosis [8]. In this review, the pathogenesis and the clinical presentation of the systemic AL amyloidosis will be discussed with the current approaches to diagnosis and treatment.

### Pathogenesis

More than 30,000 different proteins are produced in human cells. The first product of the protein synthesis is a linear amino acid chain (primary structure). The synthesized amino acid chain is pleated in the endoplasmic reticulum under the cellular quality control mechanism, first to an alpha helix, beta sheet or randomly to a secondary structure, which may be in spiral form, then to a tertiary structure in order to become a functional protein. The mutations in the amino acid sequences, low pH, increased temperature, oxidative stress, abundant protein synthesis and recombinant protein production may cause incorrect folding of the proteins. Under normal conditions, incorrectly pleated proteins are degraded by the ubiquitin-related proteolysis in the endoplasmic reticulum-associated ribosome [9].

Amyloidogenic precursor proteins (monomers) are incorrectly pleated proteins. They continue their existence in different ways and constitute the first step of abnormally pleated amyloid fibrils, which have lost their capacity to form more than one conformation and consequently have lost their solubility [10,11]. In AL amyloidosis, monomers are synthesized as a result of the instability in the immunoglobulin light chains caused by a proteolytic process or by a mutation in an amino acid sequence through a thermodynamic

**\*Corresponding author:** Guray Saydam, Ege Universitesi Hastanesi İç Hastalıkları AD, Hematoloji BD, Bornova, Izmir, Turkey, Tel: +902323903530; E-mail: [guray.saydam@ege.edu.tr](mailto:guray.saydam@ege.edu.tr)

Received March 28, 2016; Accepted April 18, 2016; Published April 25, 2016

**Citation:** Dogan EE, Şahin F, Saydam G (2016) Amyloidosis: Laboratory and Clinical Perspectives. Med chem (Los Angeles) 6: 270-279. doi:10.4172/2161-0444.1000357

**Copyright:** © 2016 Dogan EE, et al. This is an open-access article distributed under the terms of the Creative Commons Attribution License, which permits unrestricted use, distribution, and reproduction in any medium, provided the original author and source are credited.

reaction [6]. Amyloid fibril formation from monomers is considered as a consecutive multi-step process, demonstrated only under *in vitro* conditions.

Monomers undertake the amyloidogenic conformation only *ad interim*. At the beginning, they do not tend to aggregate, which correspond to the lag phase of the fibril formation [10].

Although, the role of the genetic and environmental factors in the conversion of the amyloidogenic precursor proteins to the amyloid fibrils is not fully elucidated yet, it is believed that the circulating protein level, which comes up to high levels as a result of abundant production of the amyloidogenic proteins during the transition of the amyloidogenic protein precursors to fibril formation and exceeds the capacity of the extracellular protein quality control and degradation system, plays a key role in AL amyloidosis [7,10].

The sustaining high serum concentrations (SAA,  $\beta$ 2-microglobulin) of the amyloidogenic proteins and the presence of the amyloidogenic proteins, which are genetically unstable and tend toward incorrect folding and aggregation (hereditary amyloidosis) are the triggering factors for the reconstruction of one protein with proteolysis and for the transition from advanced age (senile amyloidosis and hereditary apolipoprotein amyloidosis) monomers to amyloid fibril formation [12].

Monomers secreted to the extracellular space form the “seed” of amyloid fibrils in the interstitial site, after the slow oligomerization of the monomers as a result of the interaction of the monomers with proteolysis, metals, extracellular chaperones, matrix components and glycose aminoglycan. After the fibril core gets at the critical concentration, the reaction switches from the lag phase to the elongation phase. With the addition of the normal or amyloidogenic proteins to the amyloid fibril core, polymerization proceeds to the plateau phase, which is the saturation point [7,13]. In the end, the emerging cross- $\beta$ -pleated protofilaments, which tend to aggregate spontaneously, form the basic structure of the rigid, debranching amyloid fibrils with a diameter of 7.5-10 nm [6,10,12]. Each amyloid fibril contains 4-6 protofilaments [14]. The cylindrical and sometimes twisted protofilaments have to twist around each other in order to form the ropelike mature fibrils [15]. However, isolated filaments may be observed [16].

Glycosaminoglycan and SAP (serum amyloid protein), which constitute a part of proteoglycans in all types of amyloidosis, contribute to the fibrillogenesis and the stabilization of the amyloid fibrils in the target tissue, as they protect the amyloid fibrils from proteolysis [11]. In addition to amyloid fibrils, amyloid deposits contain besides amyloid fibrils, SAP and GAG, as well as laminin, entactin, type IV collagen and apolipoprotein E and chaperone proteins like clusterin [12].

Although, the mechanism of the organ damage caused by amyloid fibrils are not fully clarified, it is known that this mechanism displays interindividual changes and also changes according to the amyloid types. Mechanical damage, oxidative stress and increased ion channels formation are among the mechanisms, which cause organ dysfunction [17]. While soluble oligomers present toxic effects as a result of the triggering of apoptosis, amyloid deposits cause damage due to the deterioration of the organ structure [10]. Particularly in AL amyloidosis, organ damage emerges most commonly due to the idiosyncratic reaction [12]. In addition, it was shown that the light chains deteriorate the cardiac contractility and the utilization of calcium, as they change the cellular redox state in the cardiomyocytes [18].

Even if the organ tropism in amyloidosis is not elucidated yet, it is believed that local protein concentrations, interaction with collagens, tissue-specific glycosaminoglycan, pH, specific proteolytic enzymes

and cellular receptors might have a role in the basis of the organ tropism [12].

It was shown that in the AL amyloidosis, the plasma cell load and germline gene utilization affect the organ tropism. E.g., as in patients with a clone originating from 6a  $\lambda$ VI germline gene, kidneys are primarily involved; in clones originating from 1c, 2a2 and 3r  $\lambda$  genes there is mainly cardiac involvement and the possibility of multisystemic disease. On the other hand, involvement of liver is more common in patients with  $\nu$ k clone. In the amyloidosis seen with myeloma, cardiac involvement is dominant independent from germline gene utilization [19].

## AL Amyloidosis

AL amyloidosis, which is also called primary amyloidosis, is the most common and most aggressive type of systemic amyloidosis with an annual incidence of 8.9/1,000,000 in Western countries [20,21]. The average age is around 62-65 years [20,22]. While uncommon, involvement of the larynx, mouth, lung (pulmonary nodules), lymph node, GIS, skin and urinary system may be seen in the primary amyloidosis [13,23,24]. Although, the reported survival rate was between 12 and 18 months in different studies regarding the amyloidosis patients, it demonstrates high deviation as a result of the diffuseness, severity and quantity of the involved organ damage, especially in the case of cardiac involvement [25,26]. In a study conducted by the Mayo Clinic with 474 patients, the mean survival rate in patients with congestive heart failure was only 4 months [25].

In AL amyloidosis, amyloidogenic proteins consist of Ig light chains produced in clonal plasma cells in the bone marrow and more rarely in the clonal B-cells, commonly of the light chain fragments, which contain the residues of N-terminal amino acids in the variable regions of the light chains and of the heavy-chain fragments, though very rarely [6,27,28]. Free light chains might be synthesized in patients with multiple myeloma, MGUS, non-secretory myeloma, Waldenström's macroglobulinemia or B-cell lymphoproliferative disorder. However, only a fraction loses its solubility and transforms to amyloid deposits [29,30]. Regarding this topic, the studies were focused on the characteristics of the light chains, which form amyloid and particularly in the variable region of the light chain. There are 3 reasons for this focus. First reason: The variable region (V region) is the amino terminal region of the immunoglobulin light chain related with the antigen binding, and at the same time it is responsible for several variations through somatic re-organization and with many  $\nu$ L germline gene segments of one of the few joint (J) segments in the Ig light chain. Second, amyloid deposits consist of V region and light chain fragments containing the parts of the fixed region. Third, in AL amyloidosis, unlike usual, the  $\lambda$  isotype has a dominance rate of 3:1-4:1 over the  $\kappa$  isotype, which points at the genetic disposition in the  $\nu$ L segments (29,31). IGLV2-14( $\lambda$ II), IGLV6-57( $\lambda$ VI) and IGLV3-1( $\lambda$ III), which are 3  $\nu$ L genes, contributes almost to 60% of amyloidogenic  $\lambda$  light chains [31].

Amyloidosis develop in approximately 2% of the monoclonal B-cell dyscrasias [12]. The reported incidence of AL amyloidosis with concomitant multiple myeloma was about 10-15%. Plasma cell load is usually low in amyloidosis and is approximately 5-10% [6]. However, amyloidosis may sometimes be with increased plasma load in the bone marrow. It was discovered that the increased plasma cell load in the bone marrow is related to the cardiac amyloidosis and poor prognosis [19].

Amyloidosis should be suspected if a patient has nephrotic range proteinuria, restrictive cardiomyopathy, peripheral or autonomic

neuropathy (impotence, persistent diarrhea or constipation) neuropathy, hepatomegaly with alkaline phosphatase elevation unexplained weight loss and fatigue.

## Symptoms and Clinical Presentation

The common signs and symptoms of AL amyloidosis are fatigue, weight loss, syncope, peripheral edema, dyspnea, diarrhea or constipation [32]. The macroglossia, periorbital purpura, and easy bruising are also the characteristic symptoms of Amyloidosis.

In AL amyloidosis, all organs can be involved except the brain. The commonly involved organs are kidneys and heart and they are followed by nerves, liver, gastrointestinal system, skin, lung and acquired hemostasis disorders respectively [6,22]. The kidney is affected in up to 80% of individuals in AL amyloidosis. The Amyloid can be found anywhere in the kidney, but glomerular deposition with 97% of cases in a study typically predominates and present with proteinuria that ranges from subnephrotic to massive with urinary protein excretion rates as high as 20 to 30 g/d [11,33]. The urinary protein is composed mostly of albumin.

The localization of the amyloid affects the clinical presentation [33]. When amyloid is confined to the tubulointerstitium or vasculature, proteinuria is minimal and reduced GFR is the principal clinical manifestation. Vascular involvement often is accompanied by hypertension. Patients with AL- $\lambda$  tend to present with lower serum creatinine, and higher degrees of proteinuria than those with AL- $\kappa$ . Renal insufficiency is common with 47% of patients in AL amyloidosis [33]. Another extraglomerular manifestation of renal amyloidosis is Fanconi's syndrome, reflecting injury to proximal tubular cells by filtered light chains [34].

Half of patients with amyloidosis suffer from cardiac involvement and it is the most common cause of the early mortality [35]. Cardiac amyloid accumulation causes secondary asymmetric interventricular septal thickening and restrictive cardiomyopathy. In the related electrocardiography, there are low-voltage findings, especially in the chest leads [36]. Low voltage on the ECG (defined as all limb leads <5 mm in height) is found in a high proportion of patients and is often associated with extreme left- or right-axis deviation [37]. In a study; if in the echocardiography with concomitant low voltage in ECG, the ventricular wall thickness was 1.98 cm, in respect of the amyloidosis diagnosis, the determined sensitivity and the specificity were 72% and 98% respectively [38]. NT-proBNP and troponins, which are cardiac indicators used for the staging of the cardiac damage, are also useful for the prediction of the survival [39].

As a result of progressive diastolic and afterward systolic biventricular dysfunction related to restrictive cardiomyopathy, congestive heart failure and arrhythmias are encountered in the patients. Electromechanical dissociation, less often ventricular arrhythmias and related sudden deaths may be seen. Patients may present angina due to the involvement of the small vessels, progressive dyspnea due to the heart failure, weakness, fatigue, pitting edema, ascites [35,37]. 1-2% of the cardiac involvement constitutes the type of amyloidosis, which proceed with only cardiac small vessel involvement without the thickening of the walls [37]. The rate of the isolated cardiac involvement in AL amyloidosis may be 5% [38].

Syncope is a common symptom and indicates a poor prognosis. In amyloidosis, syncope may have different reasons. Its relation to exercise or to being postprandial may show that it is secondary to cardiomyopathy. Arrhythmias related to atrioventricular or sinoatrial node involvement, autonomous neuropathies, hypoalbuminemia or

intravascular volume decrease due to the usage of the loop diuretics or less often ventricular arrhythmias are among the causes of the syncope [35].

Peripheral neuropathy and autonomic neuropathy are common presenting manifestations of Primary Amyloidosis [40]. Autonomic nervous system involvement by AL amyloidosis can lead to orthostatic hypotension, early satiety as a result of delayed gastric emptying because of the gastroparesis, erectile dysfunction, and intestinal motility issues, especially diarrhea [6]. Deposition of amyloid fibrils occurs in peripheral nerves in 20% of the cases in Primary Amyloidosis, is characterized by painful, bilateral, symmetric, distal sensory neuropathy that progresses to motor neuropathy [6,20,40]. Carpal tunnel syndrome is also common [20].

70-80% of the patients with primary systemic amyloidosis had liver involvement usually asymptomatic but have poor prognoses. If symptomatic, common symptoms are weight loss or hepatomegaly. Clues of the hepatic involvement include an unexplained elevated serum alkaline phosphatase level, proteinuria, and evidence for hyposplenism [41].

Splenic involvement is relatively common (5%–10%) in primary amyloidosis and usually asymptomatic. In patients with massive deposits, hyposplenism, interfering with splenic phagocytic function and reresulting in the formation of Howell-Jolly. In addition, in the spleen with loss of splenic phagocytic function, thrombocytosis can occur. Spontaneous splenic rupture may develop [20,41,42]. The common symptoms of pulmonary involvement are cough (74%), audible wheezing (70%), dyspnea (60%), hemoptysis (50%). Five forms of primary pulmonary amyloidosis have been described: tracheobronchial, nodular (solitary or multiple), senile pulmonary, mediastinal-hilar and diffuse interstitial. Tracheobronchial amyloidosis is the most common presentation [43].

Soft tissue involvement is characterized macroglossia with submandibular swelling, hoarseness of voice, periorbital purpura, skin nodules, sign nail dystrophy, amyloid lymphadenopathy, recurrent vascular amyloid manifested by claudication of the limbs or jaw, involvement of the muscles manifested by skeletal muscle pseudohypertrophy, carpal tunnel syndrome, painful periarticular amyloid deposition, and the shoulder pad [6,44]. GI involvement is common, as shown in over 80% of biopsies taken from the rectum or stomach in AL amyloidosis. GIS amyloidosis may cause malabsorption, haemorrhia, protein losing diarrhea or constipation, pseudo-obstruction and perforation [45,46].

Finally, acquired hemostatic abnormalities, including coagulation factor deficiencies, hyperfibrinolysis, and platelet dysfunction are associated with a risk of potentially serious hemorrhagic complications in AL amyloidosis [20,47]. The bleeding may results from vascular infiltration, sometimes combined with deficit in coagulation factors (mainly in factor X, less commonly in factors V or IX) or with increased fibrinolysis [20]. The acquired factor X deficiency is the most common coagulation factor deficiency is postulated to occur via the adsorption of factor X to amyloid fibrils that has been identified in patients with amyloid light-chain (AL) amyloidosis [14].

## Diagnosis

The clinical suspicion is the first and the most important step for the diagnosis of amyloidosis. Although serum and urine PEP/IFE tests are useful and frequently used as screening tools, they are insufficient alone [48]. The sensitivity of the nephelometric serum FLC measurements is particularly useful in patients with negative immunofixation results



for serum, urine, or both [49]. A kappa-to-lambda ratio  $<0.26$  strongly suggests the presence of a population of plasma cells producing clonal lambda free light chains, whereas a ratio  $>1.65$  suggests production of clonal kappa free light chains [37]. Using serum and urine PEP/IFE in combination to nephelometric serum FLC assay as a screening test have a high sensitivity up to 99% [50]. If serum and urine PEP/IFE tests are negative and serum FLC ratio are normal ( $\kappa/\lambda$ : 0.26-1.65), amyloidosis is unlikely, but if the clinical suspicion is high further evaluation may undertaken [51]. Serum Amyloid P (SAP) scintigraphy, if available, safe and noninvasive method provides unique information on the diagnosis, distribution, and extent of amyloid deposits throughout the body [52].

NT-proBNP and evaluation urine for albuminuria are useful screening tests for the patients with light chain MGUS and Myeloma. However, Amyloid deposition should be demonstrated to conformation of diagnosis. Apple green birefringence by Congo red staining using crossed polarized light on biopsy sections is pathognomonic for amyloidosis [53]. First of all, we should prefer abdominal fat aspirate, small salivary gland, rectum or bone marrow biopsy because of the increased risk of hemorrhage. A bone marrow biopsy is mandatory to assess the percentage of plasma cells, and immunoperoxidase staining will determine whether the abnormal plasma cells are producing kappa or lambda light chains also required to diagnose of Amyloidosis associated Myeloma, Waldenström's macroglobulinemia and B cell lymphoproliferative disease [37]. The sensitivity of bone marrow biopsy is 56% alone but in combination with abdominal fat aspiration is 85% [51]. If the clinical suspicion is high, and the prior biopsies are non-diagnostic we should consider the biopsy of the affected organs [50].

The next step is fibril typing. The importance of this step is that because we make the therapy decision according to this process. For typing of an amyloid deposit, using immunohistochemistry is frequently unreliable and inaccurate, or an immunogold electron microscopy is reliable but limited by serologic dependence [8]. If a patient has a visceral amyloid syndrome, even if we detect the light chain origin with immunochemistry, it is insufficient because of the possibility of the secondary or familial form of Amyloidosis with incidental MGUS. Laser microdissection with mass spectrometry (LMD/MS) can confirm the amyloid protein composition in over 98% of cases, and it is considered the standard for typing the protein subunit in amyloid deposition [8,51]. DNA sequencing analysis of genes is useful for diagnosing of hereditary variants and, also mandatory in all patients with systemic amyloidosis whose fibril type cannot be confirmed by the other methods [12] (Figure 1).

## Extending of Disease, Staging and Prognosis

Clinical history, physical examination—examining for macroglossia, periorbital purpura, ecchymosis and, postural hypotension, assessment of performance status and performing 6 min walk test are comprise the first step for determining of the organ involvement. Hematologic and biochemical blood profiles (Alkaline phosphatase, bilirubin, creatinine, albumin, uric acid), cardiac markers (Troponin and N-terminal brain natriuretic peptide), PT, aPTT, serum factor X level (if indicated), EKG, Echocardiography (plus straining imaging) 24 hours urine collection for creatinine clearance, SAP scintigraphy, if indicated nerve conduction studies and cardiac MRI imaging are also useful tools for assessment of the extending of the disease [52].

The most important prognostic determinant in AL amyloidosis is heart dysfunction because of the cardiac involvement predicts poor prognosis [54,55]. The presence of delayed gadolinium enhancement, especially at subendocardial region seen on T1-weighted images of cardiac MRI is quite sensitive for cardiac amyloid involvement [48].

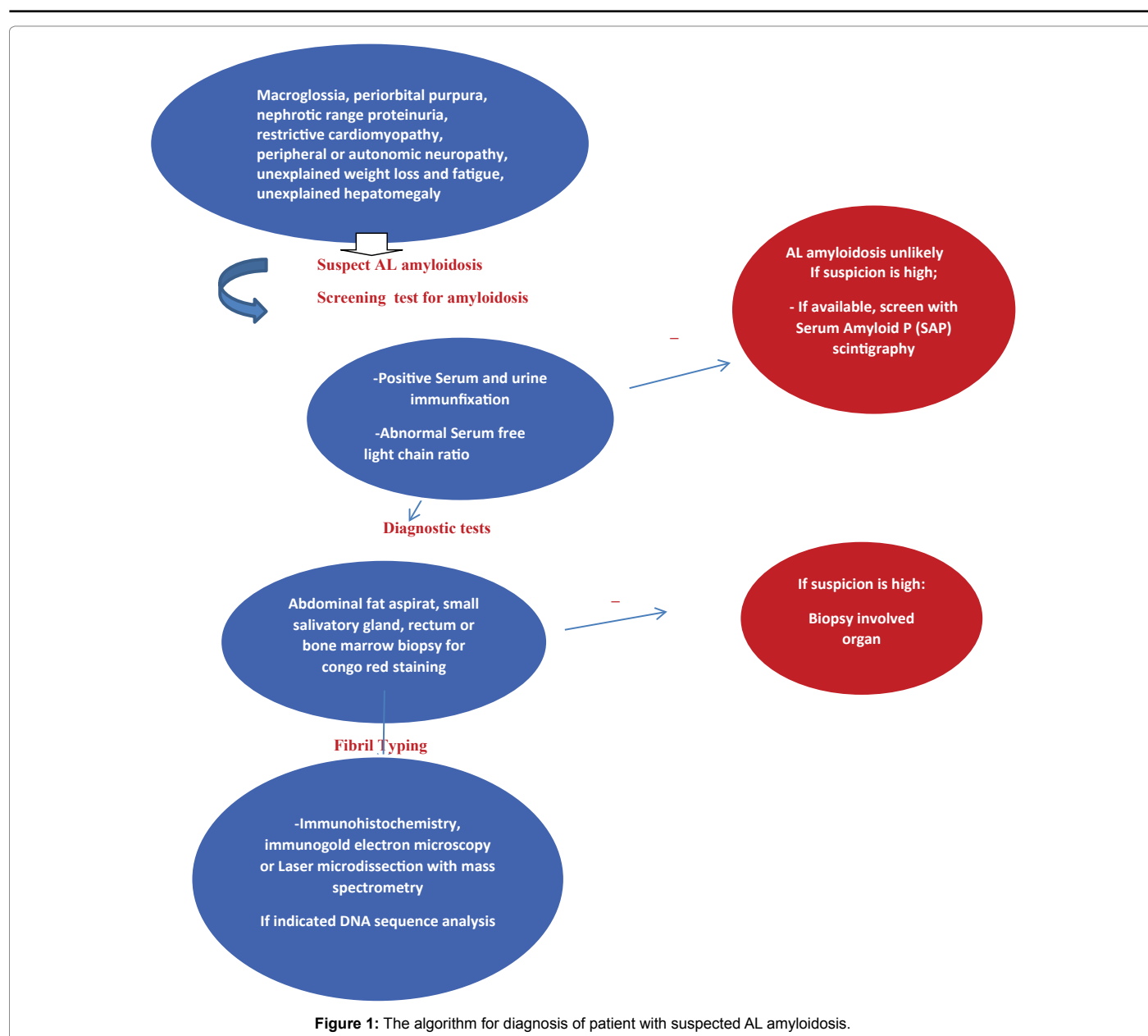
The best way to assess the severity of heart dysfunction is cardiac biomarkers; N-terminal natriuretic peptide B-type (NT-proBNP) and cardiac troponins (cTnI, cTnT) [54]. Cardiac muscle injury results in release of the troponin, that provides a specific marker of cardiac injury. NT-ProBNP is also released from myocardial cells in response to increased wall stress, and levels increased with left ventricular dysfunction, making it a useful tool in the diagnosis of cardiac failure and a strong prognostic factor in congestive heart failure [55]. Recently, in an Italian study they show that high-sensitivity (hs) cTnT assay, NT-proBNP, and cardiac troponin I predicted survival, and also hs-cTnT is the best baseline prognostic marker in AL amyloidosis, The median survival 10.6 months for patients with hs-cTnT above the cut off, 77 ng/L [54]. Mayo clinic group found that a combination of cTnT greater than 0.01  $\mu\text{g/L}$ , NT-proBNP greater than 4200 ng/L, and uric acid greater than 8.0 mg/dL best predicted the risk of death within 1 year of diagnosis in a recent study [56]. Another study show that a 33% increased in cTnTA or cTnI was associated with poor prognosis. Changes in NT pro-BNP as the main criteria for defining cardiac response. NT-proBNP values can fall rapidly following effective chemotherapy; a 30% or 300 ng/L (if baseline is  $>650$  ng/L) reduction in NT-proBNP levels after 3 cycles of chemotherapy guides treatment adequacy and, associated with improved event-free survival (32,57). So it is a very useful tool especially early assessment of cardiac response except the patients in whom renal failure progresses [57].

A cardiac risk assessment incorporating these biomarkers is reported by Mayo Clinic Group in 2004, with patients assigned to stage I, II, or III based on the presence of 0, 1, or 2 of the biomarkers, respectively, exceeding threshold levels (NT-proBNP  $<332$  ng/L; troponin T  $<0.035$   $\mu\text{g/L}$ ) [8,58]. The median overall survival of patients were 26.4, 10.5, 3.5 months respectively [58]. After treatment, response and progression of NT-proBNP and a more than 75% increase of hs-cTnT were independent prognostic determinant [54]. A recent revision that incorporates the difference between involved and uninvolved serum FLC as a powerful independently prognostic factor in patients with AL amyloidosis [55,58]. In this revised prognostic staging system based on the combination of dFLC  $\geq 18$  mg/dL, cTnT  $\geq 0.025$  ng/mL, and NT-ProBNP  $\geq 1800$  pg/ml, creating stage I to IV with scores of 0 to 3 points, respectively. The median overall survival of patients from diagnosis is 94.1, 40.3, 14, and 5.8 months, respectively [55]. The patients with NT-pro-BNP  $>8500$  ng/L and systolic blood pressure  $<100$  mmHg identify a very high risk subgroup stage III disease according to Mayo clinic risk stratification with a median overall survival of only 3 months [58]. The Mayo staging system is predictive for OS but not useful for selecting transplant recipients [59].

Both studies and experiences show that isolated renal involvement is associated with favorable overall survival. In contrast, hyperbilirubinemia is unusual in patients with hepatic involvement but is associated with poor outcomes and median survival is only 4 months [12]. Other adverse predictors of survival include the involvement of 2 or more organs, BM plasmacytosis greater than 30%, circulating plasma cells in the peripheral blood, elevated BM plasma cell labeling index, increased  $\beta_2$ -microglobulin, pretransplant free light chain ratio and time to referral center [60,61]. dFLC is predicting long-term outcome so the patient who reached aCR (negative serum and urine immunofixation and normal FLC  $\kappa/\lambda$  ratio) has the best survival [55,57].

## Treatment

All patients with a visceral amyloid syndrome need therapy in AL amyloidosis [62]. The goals of the current treatment approach of systemic AL amyloidosis includes rapidly reduction in the supply of the



monoclonal amyloidogenic light chain by eradicating the plasma cell or B cell clone to prevent the new amyloid formation and facilitate the clearance of the existing amyloid deposits and, also supportive care to sustain the function of the organ involved and maintaining the quality of life [38,63]. And the critical step for treating AL patients has been treatment assessment.

The treatment assessment focuses on these three parameters; toxicity monitoring/management, hematologic response and organ response [48]. Stable declines in the FLC of >50% from baseline values and a 30% or 300 ng/L (if baseline is >650 ng/L) reduce in the NT-proBNP after 3 chemotherapy cycles are good tools for monitoring the treatment adequacy [17,32,57] (Table 1).

As recently as 15 years ago, melphalan plus prednisone was the standard therapy for systemic AL amyloidosis [63]. The treatment responses (>50% reductions) was 25% of patients with a median time to response of one year [17]. Since then, there has been a very

rapid progress in developing new therapy regimens for the systemic amyloidosis. Afterwards, melphalan plus prednisone became an option for poor risk patients [64].

Currently, there is no standard therapy for systemic AL amyloidosis [65]. Several chemotherapeutic regimens have been evaluated, and high-dose intravenous melphalan followed by autologous stem cell transplantation to support bone marrow recovery (HDM/ASCT) has emerged as the most effective therapy for selected patients to eliminate the clonal plasma cells [11]. The treatment of AL patients with a high percentage of bone marrow plasma cells the same as patients with AL and a lower percentage of plasma cells in the bone marrow. Because we haven't got any data to support a benefit from cytoreduction before ASCT until now. And also there is an evidence from a recently reported randomized prospective clinical trial indicates that the delay associated with pre-SCT cytoreduction is likely to allow disease progression [66]. A previous study show that high pre-transplantation levels of free light-chain protein predicted a higher risk of early death [67]. Another recent

Hematologic response	Criteria
Complete response	Negative serum and urine IFE normal $\kappa/\lambda$ free Light chain (FLC) ratio, normal plasma cell ratio in the bone marrow
Very good partial response	dFLC <40 mg/L
Partial response	dFLC decrease $\geq 50\%$
Organ response	Criteria
Kidney response	50% decrease in 24-hour urinary protein excretion in the absence of decreasing of creatinine clearance $\geq 25\%$ or an increase in serum creatinine $\geq 0.5$ mg/dL
Cardiac response	Mean interventricular septal thickness decreased by 2 mm, 20% improvement in ejection fraction, improvement by two New York Heart Association classes (if baseline NYHA class 3 or 4) without an increase in diuretic use, and no increase in wall thickness and/or a decrease in NT-proBNP of $\geq 30\%$ or 300 ng/L decrease if baseline NT-proBNP 650 ng/L) in patients in with a creatinine clearance of $\geq 45$ mL/min/1.73 m <sup>2</sup>

**Abbreviations:** IFE: Immunofixation electrophoresis; dFLC: Difference in concentration between involved and uninvolved free light chains; Adopted from NCCN Guidelines Version 2.2014 [62] and study of Palladini et al. New Criteria for Response to Treatment in Immunoglobulin Light Chain Amyloidosis Based on Free Light Chain Measurement and Cardiac Biomarkers: Impact on Survival Outcomes [55].

**Table 1:** Hematologic and Organ Response Criteria.

report showed that there is no benefit of giving induction chemotherapy before ASCT, with no detrimental effect [68].

Oral melphalan and dexamethasone (MDex) is also a standard frontline therapy because of the median survival of patients treated with MDex was 5.1 years who is not eligible for HDM with stem cell transplantation [8,69].

In a phase II study with 45 Patients, MDex inducing a hematologic response 67% of the time, with 33% CR and an organ-response rate of 48% [70]. The studies report that Mel/Dex treatment yielded rapid eradication of monoclonal light chain production and rapid reduction in N-terminal brain natriuretic peptide, a marker of amyloidosis-associated cardiac dysfunction [71]. A randomized multicenter trial with 100 patient show that the outcome of treatment of AL amyloidosis with high-dose melphalan plus autologous stem-cell transplantation was not superior to the outcome with standard-dose melphalan plus dexamethasone [72]. But there was no risk stratification except that Eastern Cooperative Oncology Group (ECOG) performance-status score of 2 or lower for the patients eligibility for the SCT in this study.

Physicians at Weill-Cornell School of Medicine reported the results of melphalan and dexamethasone based regimen with advanced cardiac involvement patients. The complete response rate was 13% with high treatment related mortality (TRM) rate (26%) and a very short median survival (10.5 months) in this study [73,74].

High dose melphalan (140 to 200 mg/m<sup>2</sup>) followed by ASCT has been applied as a front line therapy for eligible patients since the end of the 1990's [63,75]. The trials show HDM/ASCT is the most effective therapy with high hematologic responses and reversal of amyloid-related organ dysfunction for AL amyloidosis [63,75]. HDM/ASCT (Melphalan 200 mg/m<sup>2</sup>) was reported to induce 76% hematologic response rate, and additionally a CR in 33% of patients [69]. In another study, the hematologic and cardiac response rates were 66 and 41%, respectively in HDM/ASCT(61). In a study from Mayo Clinic renal response was achieved in 60.3% of evaluated patient after HDM/ASCT. Proteinuria was reduced by greater than 90% in 37.9% and returned to normal in 15.5%. Median response time was 12 months. Renal response was associated with a greater increase in serum albumin level (P=0.001), maintenance of renal function (P<0.001) [76].

Despite a prospective randomized study did not demonstrate a survival advantage versus Mel/Dex for patients treated with SCT until now, achieving a hematologic CR indicates that treatment response plays an critical role in long-term survival in HDM/ASCT [62,77]. A long-term results in a series of 421 patients show that median EFS and OS were 8.3 and 13.2 years for CR patients [78]. And also a retrospective analysis show that the median survival exceeds 10 years

for patients achieving a CR after HDM/SCT, compared with 50 months for those not achieving a CR [77]. Subsequent studies show that the survival benefit of high-dose melphalan has been attributed to the patient selection [3].

The other critical point is the minimizing the treatment related toxicity related to HDM/SCT. HDM with SCT had been a high treatment-related mortality with 5% to 39%, because of the patients with visceral organ dysfunction (specially cardiac failure) [8,66]. The peri- transplantation mortality rate in patients with cardiac amyloid and clinical congestive heart failure or a history of arrhythmias, syncope, or recurrent pleural effusions approaches 100% [66].

Refinement of risk adapted eligibility criteria for autologous transplantation since 2009 resulted in a marked decrease of TRM (10.5% vs. 1.1%) [69]. Patients with serum troponin T>0.06 ng/mL or NT-proBNP >5000 pg/mL (not on dialysis) should not be considered candidates for SCT because of early mortality [59]. And also risk-adapted SCT, which tailors the dose of melphalan according to the age and risk status of the patient, may improve early survival, with a treatment-related mortality of 4% in a recent phase II study.

In addition to serum troponin T>0.06 ng/mL or NT-proBNP >5000 pg/mL the candidates should also consider for these criteria; <3 organ involvement, age< 70, and serum creatinine  $\leq 1.7$ , systolic blood pressure >90 mmHg, pulmonary diffusion capacity  $\geq 50\%$  for safe ASCT [51,66]. The tandem use of ASCT has also been reported, although in only 11 patients, of which three achieved a CR, and with no TRM [68]. Overall these promising results in well selected patients show that ASCT may still be an established first line modality in low-intermediate risk AL patients.

## Novel Agents in the Treatment of Systemic AL Amyloidosis

The introduction of thalidomide, lenalidomide and bortezomib over the last years have changed the treatment paradigm in AL amyloidosis. These agents have been suggested to improve patient outcome and overall survival including higher risk patients [69].

### Bortezomib

Bortezomib became a breakthrough for both newly diagnosed and relapsed/refractory AL amyloidosis especially with advanced cardiac involvement over the last few years [79]. In two independent retrospective studies, Mikhael et al. and Venner et al. report very high hematologic response rates, 94% and 81%, including complete response (CR) in 71% and 42%, respectively, to the combination of cyclophosphamide-bortezomib-dexamethasone in patients with either

naïve or relapsed light chain (AL) amyloidosis [79]. Kastritis et al. report an unprecedented hematologic response rate of 94%, including 44% CR, among evaluable patients, which translated into organ response in 28%, to the combination of bortezomib and dexamethasone (BD) in 18 naïve, relapse or refractory patients. The median time to hematologic response is 0.9 months, the median time for renal responses is 1 year. The authors suggest that bortezomib may contribute to improving renal function and amyloid nephropathy through the inhibition of NF- $\kappa$ B [80].

Several studies have shown rates of hematological response in excess of 80% with bortezomib in patients with relapsed or refractory disease [65]. In a pilot study addition of bortezomib to the conditioning regimen for HDM/SCT produced a high rate of hematologic and organ responses with no increase in adverse effect [81]. Combined modalities using adjuvant therapy with BDex has been attempted in subjects who obtained less than CR after ASCT (69% of newly diagnosed patients), substantially improving the quality of response. The overall response rate in patients with residual light chains post-transplant achieved 90% deeper response, with 74% achieving sCR [68]. Bortezomib-based regimens may become first-line therapy due to their superior efficacy, tolerability and rapidly response time compared to ASCT and M-Dex, in systemic AL amyloidosis [20].

### Thalidomide, Lenalidomide and Pomalidomide

Thalidomide was the first IMiD. Initial trials with thalidomide, as a single agent were associated with limited efficacy and significant toxicity [68,82]. The combination of thalidomide, cyclophosphamide and dexamethasone was effective with a hematologic response in 74%, including complete responses in 21% and partial responses in 53% in patients with advanced AL amyloidosis. Most common toxicities were fluid retention, tiredness, peripheral neuropathy and constipation and the treatment related mortality was 4% [83]. Lenalidomide and pomalidomide are good options for overcoming resistance to alkylators, bortezomib, and thalidomide.

Lenalidomide in combination with dexamethasone reported in 84 AL amyloidosis patients with relapsed/refractory diseases. 2-year OS and progression-free survival (PFS) was 84% and 73%, respectively [84]. A phase II prospective trial showed that the combination of cyclophosphamide, lenalidomide and dexamethasone induced the hematologic response rate in 62%, and the overall median survival was three years in previously treated patients [85]. Another phase 2 trial of lenalidomide, cyclophosphamide, and dexamethasone show that hematologic response (> partial response [PR]) rate was 60%, including 40% with very-good partial response or better with 29% organ responses [82]. Thalidomide can also cause neuropathy, and thalidomide and lenalidomide have been associated with thromboembolism and worsening of renal function, which should be monitored closely during treatment [13]. In recent study, when explored the pomalidomide/dexamethasone combination in patients with previously treated AL, the hematologic response rate was 48%, with a median time to response of 1.9 months. The most common grade 3-5 adverse events were neutropenia and fatigue [86-90] (Table 2).

### Investigational Therapies

Recently, alternative therapies are being explored, aimed at reducing the amyloidogenic propensity of the precursor and directly targeting the amyloid deposits such as R-1-[6- [R-2-carboxy-pyrrolidin-1-yl]-6-oxohexanoyl] pyrrolidine-2-carboxylic acid (CPHPC), Iododoxorubicin, and epigallocatechin-3-gallate (EGCG) [68]. CPHPC, is palindromic compound that binds and cross-links circulating serum amyloid P component, resulting in dimerization and

rapid clearance of human serum amyloid P (SAP) molecules by the liver and depleting SAP from the circulation [50,53,91].

A study with murine AA amyloidosis showed that a new anthracycline, 4-iodo-4-deoxydoxorubicin (I-DOX), bound with high affinity to amyloid fibrils and promotes their disaggregation. And also, in a small, uncontrolled series administration of IDOX to patients with AL amyloidosis showed promising results but its efficacy was unable to be demonstrated in a larger, multicenter trial.

A longitudinal observational study show that consumption of green tea polyphenol EGCG in patients with cardiac amyloidosis with AL amyloidosis causes a significant decrease in left ventricular wall thickness and mass, and as well as improvement in NYHA functional classification [92].

### Supportive Therapy

Supportive care is necessary and also an important part of the therapy with AL patients with especially cardiac and renal involvement. The edema generally requires salt and, fluid restriction and treatment with high-dose loop diuretics and if necessary thiazide and/or potassium-sparing diuretics [38]. Resistant, large, pleural effusions may necessitate recurrent pleural taps and sometimes require pleurodesis in patients with pleural amyloidosis [37]. The restrictive cardiac filling and autonomic neuropathy may lead to severe bradycardia and hypotension, thus limiting some of the drugs use [38]. Use of diuretics and salt restriction to manage intravascular volume overload, or of  $\beta$ - or calcium-channel blockers for atrial fibrillation (which did not occur in this case), may exacerbate orthostasis. In such instances, midodrine may be useful for blood pressure support and amiodarone for control of atrial fibrillation [5]. Vasoactive drugs, including angiotensin-converting enzyme inhibitors and angiotensin II inhibitors can promote hypotension in AL amyloidosis and should be used with caution or avoided [13,38]. Careful monitoring is needed to avoid significant drug interactions, for example,  $\beta$ -blockers with thalidomide used in chemotherapy of AL amyloidosis causing bradycardia [35]. In addition, both digoxin and certain calcium blockers bind to amyloid fibrils, and this interaction may account for the increased susceptibility to digoxin toxicity and to hemodynamic deterioration with calcium blockers [38]. Nephrotic syndrome may persist in patients with end-stage renal disease (ESRD) and require therapeutic intervention to stop diuresis. Chronic dialysis is indicated in patients with AL amyloidosis and ESRD. Kidney transplantation should also be offered to selected patient [20].

### Organ Transplantation and Allogeneic Stem Cell Transplantation

Organ transplant should be considered in patients who attain CR, with irreversible end-stage organ damage. Heart transplant followed by ASCT or other effective chemotherapy should be consider for young patients with isolated, severe cardiac involvement [68]. Twenty-four cases have been performed in the United Kingdom, Survival of the 10 AL patients who had no adjunctive chemotherapy was 50% at 1 year and 20% at 5 years [38].

It is reasonable to propose kidney transplantation in patients who have achieved complete hematological remission and extrarenal organ responses [93].

The first successful allogeneic bone marrow transplantation reported in 1997. In a retrospective study with 19 patients with AL amyloidosis who was underwent allogeneic stem cell transplantation was associated with 40% Treatment related mortality. However, given the risk of the procedure, evidence is require that, allo-BMT has



Therapy	CR	Hematologic Response Rate	Organ Response Rate
Melphalan-dexamethasone	33%	67%	48% [68]
Cyclophosphamide-thalidomide-dexamethasone	21%	74%	26.6% [81]
Cyclophosphamide-bortezomib-dexamethasone	41.90%	81.40%	46% [86]
Cyclophosphamide-bortezomib-dexamethasone	71%	94%	50% [87]
Lenalidomide-cyclophosphamide-dexamethasone	11%	60%	29% [80]
Bortezomib-dexamethasone	44%	94%	28% [88]

Abbreviations: CR: Complete Remission

**Table 2:** Conventional Systemic Chemotherapy Options for Treatment of AL Amyloidosis.

substantial long-term advantages over ASCT before it used more widely in the treatment of AL amyloidosis.

## Conclusion

Despite a rapid development of the treatment of AL amyloidosis in the last years, the therapy of systemic AL amyloidosis remains a challenge. There is no standard optimal care for newly diagnosed patients. Serum proBNP and troponin levels are the most important markers for the risk stratification. The other characteristics of patients, such as age, co-morbidities, the extend and the number of the organ involvement, and patient prefers are also important part of the therapy decision. The aim of the therapy to achieve of deep hematologic response especially CR to quality of life and improvement in survival. The stimulate the awareness with early diagnosis of AL amyloidosis especially with MGUS is important for improving survival. Recent therapeutic advances provide longer survival and develops the quality of life, but light-chain (AL) amyloidosis is still incurable. Intensive research is now focusing on the understanding the molecular basis of protein misfolding and fibril formation, the molecular mechanisms underlying the light chain targeting of specific tissues to make the disease curable.

## References

- Gorevich PD (2013) An overview of amyloidosis.
- Sipe JD, Benson MD, Buxbaum JN, Ikeda S, Merlini G, et al. (2010) Amyloid fibril protein nomenclature: 2010 recommendations from the nomenclature committee of the International Society of Amyloidosis. *Amyloid* 17: 101-104.
- Baker KR, Rice L (2012) The amyloidoses: clinical features, diagnosis and treatment. *Methodist Debakey Cardiovasc J* 8: 3-7.
- Leung N, Nasr SH, Sethi S (2012) How I treat amyloidosis: the importance of accurate diagnosis and amyloid typing. *Blood* 120: 3206-3213.
- Comenzo RL (2009) How I treat amyloidosis. *Blood* 114: 3147-3157.
- Sanchorawala V (2006) Light-chain (AL) amyloidosis: diagnosis and treatment. *Clin J Am Soc Nephrol* 1: 1331-1341.
- Blancas-Mejía LM, Ramirez-Alvarado M (2013) Systemic amyloidoses. *Annu Rev Biochem* 82: 745-774.
- Cohen AD, Comenzo RL (2010) Systemic Light-Chain Amyloidosis: Advances in Diagnosis, Prognosis, and Therapy. *Hematology Am Soc Hematol Educ Program* 287-294.
- Herczenik E, Gebbink MF (2008) Molecular and cellular aspects of protein misfolding and disease. *FASEB J* 22: 2115-2133.
- Merlini G, Bellotti V (2003) Molecular mechanisms of amyloidosis. *N Engl J Med* 349: 583-596.
- Dember LM (2006) Amyloidosis-associated kidney disease. *J Am Soc Nephrol* 17: 3458-3471.
- Gillmore JD, Hawkins PN (2013) Pathophysiology and treatment of systemic amyloidosis. *Nat Rev Nephrol* 9: 574-586.
- Merlini G, Seldin DC, Gertz MA (2011) Amyloidosis: pathogenesis and new therapeutic options. *J Clin Oncol* 29: 1924-1933.
- Westermarck P (1998) The pathogenesis of amyloidosis: understanding general principles. *Am J Pathol* 152: 1125-1127.
- Serpell LC, Sunde M, Benson MD, Tennent GA, Pepys MB, et al. (2000) The protofibril substructure of amyloid fibrils. *J Mol Biol* 300: 1033-1039.
- Lashuel HA, Wurth C, Woo L, Kelly JW (1999) The most pathogenic transthyretin variant, L55P, forms amyloid fibrils under acidic conditions and protofibrils under physiological conditions. *Biochemistry* 38: 13560-13573.
- Comenzo RL (2007) Current and emerging views and treatments of systemic immunoglobulin light-chain (AL) amyloidosis. *Contrib Nephrol* 153: 195-210.
- Brenner DA, Jain M, Pimentel DR, Wang B, Connors LH, et al. (2004) Human Amyloidogenic Light Chains Directly Impair Cardiomyocyte Function Through an Increase in Cellular Oxidant Stress. *Circ Res* 94: 1008-1010.
- Comenzo RL, Zhang Y, Martinez C, Osman K, Herrera GA (2001) The tropism of organ involvement in primary systemic amyloidosis: contributions of Ig V(L) germ line gene use and clonal plasma cell burden. *Blood* 98: 714-720.
- Desport E, Bridoux F, Sirac C, Delbes S, Bender S, et al. (2012) AL amyloidosis. *Orphanet J Rare Dis* 7: 54.
- Kyle RA, Linos A, Beard CM, Linke RP, Gertz MA, et al. (1992) Incidence and natural history of primary systemic amyloidosis in Olmsted County, Minnesota, 1950 through 1989. *Blood* 79: 1817-1822.
- Huang X, Wang Q, Jiang S, Chen W, Zeng C, et al. (2015) The clinical features and outcomes of systemic AL amyloidosis: a cohort of 231 Chinese patients. *Clin Kidney J* 8: 120-126.
- Yiotakis I, Georgiolis A, Charalabopoulos A, Hatzipantelis P, Golias C, et al. (2009) Primary localized laryngeal amyloidosis presenting with hoarseness and dysphagia: a case report. *J Med Case Rep* 3: 9049.
- Angiero F, Seramondi R, Magistro S, Crippa R, Benedicenti S, et al. (2010) Amyloid deposition in the tongue: clinical and histopathological profile. *Anticancer Res* 30: 3009-3014.
- Perfetti V, Colli Vignarelli M, Anesi E, Garini P, Quaglini S, et al. (1999) The degrees of plasma cell clonality and marrow infiltration adversely influence the prognosis of AL amyloidosis patients. *Haematologica* 84: 218-221.
- Kumar SK, Gertz MA, Lacy MQ, Dingli D, Hayman SR, et al. (2011) Recent improvements in survival in primary systemic amyloidosis and the importance of an early mortality risk score. *Mayo Clin Proc* 86: 12-18.
- Müller AM, Geibel A, Neumann HP, Kühnemund A, Schmitt-Gräff A, et al. (2006) Primary (AL) amyloidosis in plasma cell disorders. *Oncologist* 11: 824-830.
- Eulitz M, Weiss DT, Solomon A (1990) Immunoglobulin heavy-chain-associated amyloidosis. *Proc Natl Acad Sci U S A* 87: 6542-6546.
- Perfetti V, Palladini G, Casarini S, Navazza V, Rognoni P, et al. (2012) The repertoire of λ light chains causing predominant amyloid heart involvement and identification of a preferentially involved germline gene, IGLV1-44. *Blood* 119: 144-150.
- Benson MD (2001) Amyloidosis. *Encyclopedia of life sciences*.
- Merlini G, Palladini G (2012) Differential diagnosis of monoclonal gammopathy of undetermined significance. *Hematology Am Soc Hematol Educ Program* 595-603.
- Merlini G, Wechalekar AD, Palladini G (2013) Systemic light chain amyloidosis: an update for treating physicians. *Blood* 121: 5124-5130.
- Khalighi MA, Dean Wallace W, Palma-Diaz MF (2014) Amyloid nephropathy. *Clin Kidney J* 7: 97-106.
- Messiaen T, Deret S, Mougenot B, Bridoux F, Dequiedt P, et al. (2000) Adult Fanconi Syndrome Secondary to Light Chain Gammopathy. *Clinicopathologic Heterogeneity and Unusual Features in 11 Patients. Medicine (Baltimore)* 79: 135-154.



35. Banypersad SM, Moon JC, Whelan C, Hawkins PN, Wechalekar AD (2012) Updates in cardiac amyloidosis: a review. *J Am Heart Assoc* 1: e000364.
36. Dubrey SW, Cha K, Anderson J, Chamarthi B, Reisinger J, et al. (1998) The clinical features of immunoglobulin light-chain (AL) amyloidosis with heart involvement. *QJM* 91: 141-157.
37. Falk RH (2005) Diagnosis and management of the cardiac amyloidoses. *Circulation* 112: 2047-2060.
38. Selvanayagam JB, Hawkins PN, Paul B, Myerson SG, Neubauer S (2007) Evaluation and management of the cardiac amyloidosis. *J Am Coll Cardiol* 50: 2101-2110.
39. Merlini G, Palladini G (2013) Light chain amyloidosis: the heart of the problem. *Haematologica* 98: 1492-1495.
40. Pandit A, Gangurde S, Gupta SB (2008) Autonomic failure in primary amyloidosis. *J Assoc Physicians India* 56: 995-996.
41. Park MA, Mueller PS, Kyle RA, Larson DR, Plevak MF, et al. (2003) Primary (AL) hepatic amyloidosis: clinical features and natural history in 98 patients. *Medicine (Baltimore)* 82: 291-298.
42. Chan RS, Abdul Aziz YF, Chandran P, Ng EK (2011) Splenic amyloidosis: a rare cause of spontaneous splenic rupture. *Singapore Med J* 52: e232-235.
43. Berraondo J, Novella L, Sanz F, Lluch R, de Casimiro E, et al. (2013) Management of tracheobronchial amyloidosis with therapeutic bronchoscopic techniques. *Arch Bronconeumol* 49: 207-209.
44. Gertz MA, Comenzo R, Falk RH, Fermand JP, Hazenberg BP, et al. (2005) Definition of organ involvement and treatment response in immunoglobulin light chain amyloidosis (AL): a consensus opinion from the 10th International Symposium on Amyloid and Amyloidosis, Tours, France, 18-22 April 2004. *Am J Hematol* 79: 319-328.
45. Cowan AJ, Skinner M, Seldin DC, Berk JL, Lichtenstein DR, et al. (2013) Amyloidosis of the gastrointestinal tract: a 13-year, single-center, referral experience. *Haematologica* 98: 141-146.
46. Isomoto H, Kamo Y, Chen CC, Nakao K (2012) Clinical management of gastrointestinal amyloidosis. *Journal of Gastroenterology* 2: 155-162.
47. Sucker C, Hetzel GR, Grabensee B, Stocksclaeder M, Scharf RE (2006) Amyloidosis and bleeding: pathophysiology, diagnosis, and therapy. *Am J Kidney Dis* 47: 947-955.
48. Dispenzieri A, Gertz MA, Buadi F (2012) What do I need to know about immunoglobulin light chain (AL) amyloidosis? *Blood Rev* 26: 137-154.
49. Abraham RS, Katzmman JA, Clark RJ, Bradwell AR, Kyle RA, et al. (2003) Quantitative analysis of serum free light chains. A new marker for the diagnostic evaluation of primary systemic amyloidosis. *Am J Clin Pathol* 119: 274-278.
50. Gertz MA (2014) Immunoglobulin light chain amyloidosis: 2014 update on diagnosis, prognosis, and treatment. *Am J Hematol* 89: 1132-1140.
51. Mahmood S, Palladini G, Sanchowawala V, Wechalekar A (2014) Update on treatment of light chain amyloidosis. *Haematologica* 99: 209-221.
52. Palladini G, Barassi A, Klersy C, Pacciolla R, Milani P, et al. (2010) The combination of high-sensitivity cardiac troponin T (hs-cTnT) at presentation and changes in N-terminal natriuretic peptide type B (NT-proBNP) after chemotherapy best predicts survival in AL amyloidosis. *Blood* 116: 3426-3430.
53. Kumar S, Dispenzieri A, Lacy MQ, Hayman SR, Buadi FK, et al. (2012) Revised prognostic staging system for light chain amyloidosis incorporating cardiac biomarkers and serum free light chain measurements. *J Clin Oncol* 30: 989-995.
54. Kumar SK, Gertz MA, Lacy MQ, Dingli D, Hayman SR, et al. (2011) Recent improvements in survival in primary systemic amyloidosis and the importance of an early mortality risk score. *Mayo Clin Proc* 86: 12-18.
55. Palladini G, Dispenzieri A, Gertz MA, Kumar S, Wechalekar A, et al. (2012) New Criteria for Response to Treatment in Immunoglobulin Light Chain Amyloidosis Based on Free Light Chain Measurement and Cardiac Biomarkers: Impact on Survival Outcomes. *J Clin Oncol* 30: 4541-4549.
56. Wechalekar AD, Schonland SO, Kastiris E, Gillmore JD, Dimopoulos MA, et al. (2013) A European collaborative study of treatment outcomes in 346 patients with cardiac stage III AL amyloidosis. *Blood* 121: 3420-3427.
57. Gertz MA, Lacy MQ, Dispenzieri A, Kumar SK, Dingli D, et al. (2013) Refinement in patient selection to reduce treatment-related mortality from autologous stem cell transplantation in amyloidosis. *Bone Marrow Transplant* 48: 557-561.
58. Roy V (2012) Autologous stem cell transplant for AL amyloidosis. *Bone Marrow Res* 2012: 238961.
59. Madan S, Kumar SK, Dispenzieri A, Lacy MQ, Hayman SR, et al. (2012) High-dose melphalan and peripheral blood stem cell transplantation for light-chain amyloidosis with cardiac involvement. *Blood* 119: 1117-1122.
60. Gertz MA (2013) Immunoglobulin light chain amyloidosis: 2013 update on diagnosis, prognosis, and treatment. *Am J Hematol* 88: 416-425.
61. Palladini G, Perfetti V, Merlini G (2006) Therapy and management of systemic AL (primary) amyloidosis. *Swiss Med Wkly* 136: 715-720.
62. NCCN guideline Version 2.2014.
63. Wechalekar AD, Gillmore JD, Bird J, Cavenagh J, Hawkins S, et al. (2015) Guidelines on the management of AL amyloidosis. *Br J Haematol* 168: 186-206.
64. Comenzo RL, Gertz MA (2002) Autologous stem cell transplantation for primary systemic amyloidosis. *Blood* 99: 4276-4282.
65. Gertz MA, Lacy MQ, Dispenzieri A, Hayman SR, Kumar SK, et al. (2007) Effect of hematologic response on outcome of patients undergoing transplantation for primary amyloidosis: importance of achieving a complete response. *Haematologica* 92: 1415-1418.
66. Gatt ME, Palladini G (2013) Light chain amyloidosis 2012: a new era. *Br J Haematol* 160: 582-598.
67. Gatt ME (2014) Light Chain Amyloidosis 2014. *International Journal of Hematological Disorders* 1: 21-29.
68. Palladini G, Russo P, Nuvolone M, Lavatelli F, Perfetti V, et al. (2007) Treatment with oral melphalan plus dexamethasone produces long-term remissions in AL amyloidosis. *Blood* 110: 787-788.
69. Dember LM (2009) Modern treatment of amyloidosis: unresolved questions. *J Am Soc Nephrol* 20: 469-472.
70. Jaccard A, Moreau P, Leblond V, Leleu X, Benboubker L, et al. (2007) High-dose melphalan versus melphalan plus dexamethasone for AL amyloidosis. *N Engl J Med* 357: 1083-1093.
71. Gertz MA (2010) I don't know how to treat amyloidosis. *Blood* 116: 507-508.
72. Lebovic D, Hoffman J, Levine BM, Hassoun H, Landau H, et al. (2008) Predictors of survival in patients with systemic light-chain amyloidosis and cardiac involvement initially ineligible for stem cell transplantation and treated with oral melphalan and dexamethasone. *Br J Haematol* 143: 369-373.
73. Comenzo RL, Gertz MA (2002) Autologous stem cell transplantation for primary systemic amyloidosis. *Blood* 99: 4276-4282.
74. Leung N, Dispenzieri A, Fervenza FC, Lacy MQ, Villicana R, et al. (2005) Renal response after high-dose melphalan and stem cell transplantation is a favorable marker in patients with primary systemic amyloidosis. *Am J Kidney Dis* 46: 270-277.
75. Sanchowawala V, Skinner M, Quillen K, Finn KT, Doros G, et al. (2007) Long-term outcome of patients with AL amyloidosis treated with high-dose melphalan and stem-cell transplantation. *Blood* 110: 3561-3563.
76. Cibeira MT, Sanchowawala V, Seldin DC, Quillen K, Berk JL, et al. (2011) Outcome of AL amyloidosis after high-dose melphalan and autologous stem cell transplantation: long-term results in a series of 421 patients. *Blood* 118: 4346-4352.
77. Merlini G (2012) CyBorD: stellar response rates in AL amyloidosis. *Blood* 119: 4343-4345.
78. Sitia R, Palladini G, Merlini G (2007) Bortezomib in the treatment of AL amyloidosis: targeted therapy? *Haematologica* 92: 1302-1307.
79. Sanchowawala V, Quillen K, Sloan JM, Andrea NT, Seldin DC (2011) Bortezomib and high-dose melphalan conditioning for stem cell transplantation for AL amyloidosis: a pilot study. *Haematologica* 96: 1890-1892.
80. Kumar SK, Hayman SR, Buadi FK, Roy V, Lacy MQ, et al. (2012) Lenalidomide, cyclophosphamide, and dexamethasone (CRd) for light-chain amyloidosis: long-term results from a phase 2 trial. *Blood* 119: 4860-4867.
81. Wechalekar AD, Goodman HJ, Lachmann HJ, Offer M, Hawkins PN, et al. (2007) Safety and efficacy of risk-adapted cyclophosphamide, thalidomide, and dexamethasone in systemic AL amyloidosis. *Blood* 109: 457-464.
82. Mahmood S, Venner CP, Sachchithanatham S, Lane T, Rannigan L, et al. (2014) Lenalidomide and dexamethasone for systemic AL amyloidosis following prior treatment with thalidomide or bortezomib regimens. *Br J Haematol* 166: 842-848.

83. Palladini G, Russo P, Milani P, Folli A, Lavatelli F, et al. (2013) A phase II trial of cyclophosphamide, lenalidomide and dexamethasone in previously treated patients with AL amyloidosis. *Haematologica* 98: 433-436.
84. Dispenzieri A, Buadi F, Laumann K, LaPlant B, Hayman SR, et al. (2012) Activity of pomalidomide in patients with immunoglobulin light-chain amyloidosis. *Blood* 119: 5397-5404.
85. Palladini G, Russo P, Nuvolone M, Lavatelli F, Perfetti V, et al. (2007) Treatment with oral melphalan plus dexamethasone produces long-term remissions in AL amyloidosis. *Blood* 110: 787-788.
86. Venner CP, Lane T, Foard D, Rannigan L, Gibbs SD, et al. (2012) Cyclophosphamide, bortezomib, and dexamethasone therapy in AL amyloidosis is associated with high clonal response rates and prolonged progression-free survival. *Blood* 119: 4387-4390.
87. Mikhael JR, Schuster SR, Jimenez-Zepeda VH, Bello N, Spong J, et al. (2012) Cyclophosphamide-bortezomib-dexamethasone (CyBORd) produces rapid and complete hematologic response in patients with AL amyloidosis. *Blood* 119: 4391-4394.
88. Kastiris E, Wechalekar AD, Dimopoulos MA, Merlini G, Hawkins PN, et al. (2010) Bortezomib With or Without Dexamethasone in Primary Systemic (Light Chain) Amyloidosis. *J Clin Oncol* 28: 1031-1037.
89. Hirschfield GM (2004) Amyloidosis: a clinico-pathophysiological synopsis. *Semin Cell Dev Biol* 15: 39-44.
90. Mereles D, Buss SJ, Hardt SE, Hunstein W, Katus HA (2010) Effects of the main green tea polyphenol epigallocatechin-3-gallate on cardiac involvement in patients with AL amyloidosis. *Clin Res Cardiol* 99: 483-490.
91. Bridoux F, Ronco P, Gillmore J, Fervand JP (2011) Renal transplantation in light chain amyloidosis: coming out of the cupboard. *Nephrol Dial Transplant* 26: 1766-1768.
92. Gillmore JD, Davies J, Iqbal A, Madhoo S, Russell NH, et al. (1998) Allogeneic bone marrow transplantation for systemic AL amyloidosis. *Br J Haematol* 100: 226-228.
93. Schönland SO, Lokhorst H, Buzyn A, Leblond V, Hegenbart U, et al. (2006) Allogeneic and Syngeneic Hematopoietic Cell Transplantation in Patients with Amyloid Light Chain Amyloidosis: A Report from the European Group for Blood and Marrow Transplantation. *Blood* 107: 2578-2584.