

An Unusual Cause of a Not so Unusual Symptom

Acharyya BC^{1*}, Saha S², Chakrabarti H³ and Acharyya S⁴

¹Department of Paediatric Gastroenterology, AMRI Hospitals, Kolkata, West Bengal, India

²Department of Paediatric Surgery, AMRI Hospitals, Kolkata, West Bengal, India

³Department of Pathology, AMRI Hospitals, Kolkata, West Bengal, India

⁴Department of Paediatrics, AMRI Hospitals, Kolkata, West Bengal, India

*Corresponding author: Bhaswati C Acharyya, Department of Paediatric Gastroenterology, AMRI Hospitals, Kolkata, West Bengal India, E-mail: bukuli2@hotmail.com

Received date: March 21, 2016; Accepted date: April 13, 2016; Published date: April 20, 2016

Copyright: © 2016 Acharyya BC, et al. This is an open-access article distributed under the terms of the Creative Commons Attribution License, which permits unrestricted use, distribution, and reproduction in any medium, provided the original author and source are credited.

Abstract

Gastroduodenal polyp as a cause of upper gastrointestinal bleeding is a very rare entity especially in infancy. In infants hematemesis often is a manifestation of systemic illnesses like septicemia or coagulopathy. Here we present a 5 month old young girl who presented in emergency with hematemesis associated with a significant drop of Hemoglobin. On endoscopy a large gastric antral polyp was found to be the cause of bleeding. She was managed successfully with a laparoscopic polypectomy.

Keywords: Gastric; Polyp; Hematemesis; Infancy

Introduction

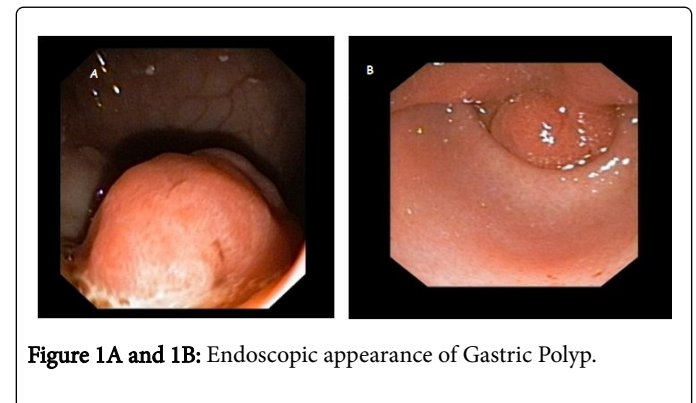
Haematemesis in infancy is an uncommon entity. Septicemia, coagulopathy, necrotising enterocolitis, mallow weiss tear are few causes which predominate. Haematemesis due to gastroduodenal polyp is a very rare aetiology to find in infants. Among the polyps hamartomatous polyp and hyperplastic polyp might be encountered in infancy [1]. Here we describe an infant who presented with hematemesis and a gastric antral hyperplastic polyp was found to be the cause of the haematemesis which is a rare diagnosis

Case Report

A 5 month old female baby was admitted from emergency with history of 3 bouts of large vomit of blood for one day with one episode of melena. History revealed that the child was born of non-consanguineous parents without any significant family history of any illness. She was born by normal delivery and was thriving. She had occasional vomiting which was regarded as GERD by her attending paediatrician. Her vomitus used to be milk and mucoid fluids without any blood or bile. Examination revealed a normally grown baby with weight of 5.5 kg. She looked pale. Abdominal examination was normal without any mass or visible peristalsis. Investigations revealed low Haemoglobin of 6.5 gm with normal total leucocytes and platelet count. Her Coagulation profile was normal. Blood gas showed normal pH and electrolytes. She was kept nil by mouth and was started on intravenous fluids and intravenous proton pump inhibitor, Omeprazole. An ultrasound of abdomen with doppler was done to exclude any duplication cyst or major vascular anomaly. Ultrasound revealed an echogenic mass at pylorus. She was transfused with 90 ml of packed red cells and an endoscopy was arranged after the transfusion was over.

On endoscopy esophagus was normal. After entering stomach there was blood in the lumen. As proceeded distally a large polypoid mass was noted with grooved, ulcerated and irregular surface (Figure 1A

and 1B). It was situated about 2 cm proximal to antrum and pylorus was crossed without any resistance. 1st and 2nd part of duodenum was normal.



Initially an endoscopic polypectomy was planned but in view of a wide stalk in a 5 month old baby a decision of laparoscopic polypectomy was taken. On laparoscopy a wide stalked antral polyp was found which was removed. Histopathology showed the features of hyperplastic polyp. The infant recovered very well post operatively and started feeding from breast from 2nd day and was discharged on 3rd day.

Discussion

Gastric polyp in infancy is an uncommon entity. The prevalence of gastric polyps in the pediatric population is low compared with that in adults (0.7% vs. 6.35%) [1,2].

Commonest pathological varieties are hyperplastic variety and are mostly asymptomatic when very small [3]. Present infant also had hyperplastic polyp in histopathology.

The pathogenesis of sporadic gastric polyps in adults and children still remains uncertain. In adults with sporadic fundic gland polyps (FGPs) mutations of the β -catenin gene affecting the APC/ β -catenin

pathway occurred and this may be involved in the pathogenesis of sporadic fundic gland polyps [4]. In pediatric population cases are limited but in future genetic sequencing of all such cases will be needed to delineate the genetic background (Figures 2 and 3).

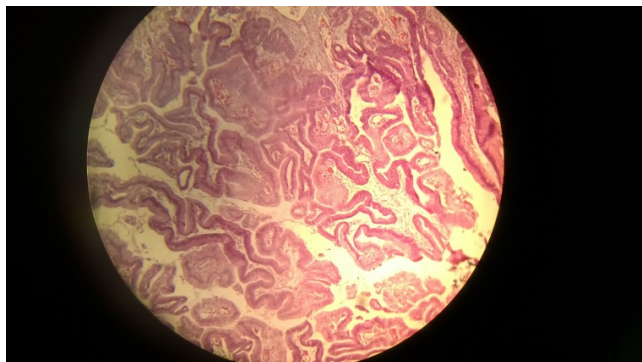


Figure 2: Histopathology of polyp showing hyperplastic variant.

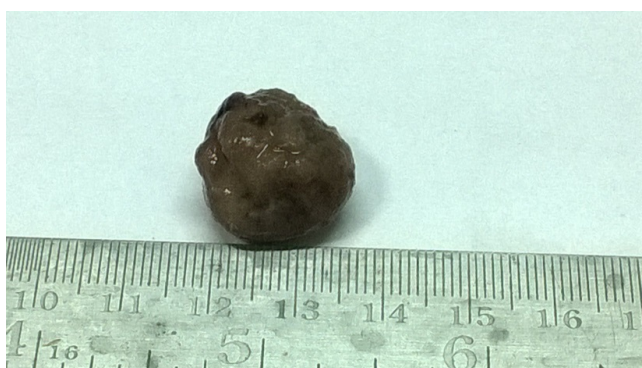

Figure 3: Macroscopic appearance of the polyp after resection.

Few cases of Gastric polyp mimicking hypertrophic pyloric stenosis in infancy have been reported in literature [5]. In infancy haematemesis as a presentation of polyp is rarer; so far only one case was reported whose sole presentation was haematemesis [6]. Present case has a significant haematemesis to drop her haemoglobin to 6.5 gm.

Earlier imaging with USG or contrast imaging used to be the mainstay in diagnosis. Ultrasonographic appearance of a hyperplastic gastric polyp has been described as an echogenic polypoid mass arising from distal antral mucosa [7]. Presently availability of paediatric endoscopy allows direct visualization of internal lesion. Though ultrasound

abdomen was done initially but endoscopy clinched the diagnosis in this baby.

Most of the cases of hyperplastic polyps reported in literature have been removed by surgical laparotomy. But endoscopic snare polypectomy or endoscopic mucosal resection is preferred option in present practice. However, at very early age, removing giant gastric polyps using endoscopy is challenging because bleeding from feeding vessel could induce unexpected hypovolemic shock [8]. Even in a 56 year old, severe bleeding from such polyp has been described where endoscopic measures failed to control bleeding and surgical wedge resection was needed [9]. Present case was also subjected to laparoscopic removal in view of large size and age of the infant.

Endoscopic submucosal dissection (ESD) can avoid the problems of endoscopic mucosal resection for better hemostasis under direct vision. Successful ESD has been reported in children even as young as 21 month old [7] but it needs immense expertise to perform in young infant like the present case.

In conclusion hyperplastic polyp is a very uncommon etiology of haematemesis in infants. Endoscopy gives a quick and definitive diagnosis and can guide for the proper management depending on availability of expert hands, clinical condition of the patient and the age of the child.

References

1. Attard TM, Yardley JH, Cuffari C (2002) Gastric polyps in pediatrics: an 18-year hospital-based analysis. *Am J Gastroenterol* 97: 298-301.
2. Carmack SW, Genta RM, Schuler CM, Saboorian MH (2009) The current spectrum of gastric polyps: a 1-year national study of over 120,000 patients. *Am J Gastroenterol* 104:1524-1532.
3. Jain R, Chetty R (2009) Gastric hyperplastic polyps: a review. *Dig Dis Sci* 54: 1839-1846.
4. Abraham SC, Nobukawa B, Giardiello FM, Hamilton SR, Wu TT (2001) Sporadic Fundic Gland Polyps. Common Gastric Polyps Arising through Activating Mutations in the β -Catenin Gene. *Am J Pathol* 158: 1005-1010.
5. Sarji S (2008) Infantile Hyperplastic Gastric Polyps: A Rare Entity. *The Internet Journal of Pediatrics and Neonatology* 11: 1.
6. Brooks GS, Frost ES, Wesselhoe C (1992) Prolapsed hyperplastic gastric polyp causing gastric outlet obstruction, hypergastrinemia, and haematemesis in an infant. *J Pediatr Surg* 27: 1537-1538.
7. Kim S, Chung CJ, Fordham LA, Specter BB (1997) Coexisting hyperplastic antral polyp and hypertrophic pyloric stenosis. *Pediatr Radiol* 27: 912-914.
8. Jung EY, Choi SO, Cho KB, Kim ES, Park KS, et al. (2014) Successful endoscopic submucosal dissection of a giant polyp in a 21-month-old female. *World J Gastroenterol* 20: 323-325.
9. Nayudu SK, Niazi M, Balar B, Kumbum K (2013) A Rare Complication of Hyperplastic Gastric Polyp. *Case Rep Gastrointest Med*.