

An Unusual Mass at the Colonic Splenic Flexure

Salih Samo* and Srinadh Komanduri

Northwestern University Feinberg School of Medicine, 333 East Ontario Street, Unit 4205, Chicago, IL 60611, USA

*Corresponding author: Salih Samo, MD, Northwestern University Feinberg School of Medicine, Address: 333 East Ontario Street, Unit 4205, Chicago, IL 60611, USA, E-mail id: salihsamo@hotmail.com

Rec date: Mar 16, 2016; Acc date: Mar 26, 2016; Pub date: Mar 31, 2016

Copyright: © 2016 Samo S, et al. This is an open-access article distributed under the terms of the Creative Commons Attribution License, which permits unrestricted use, distribution, and reproduction in any medium, provided the original author and source are credited.

Keywords: Splenic Flexure; Fecaloma; Constipation

Introduction

Large bowel obstruction is less common than small bowel obstruction and constitutes about 25% of intestinal obstruction [1]. Chronic functional bowel obstruction can lead to fecal impaction and subsequent fecaloma formation. We report a case of large bowel obstruction secondary to a large fecal mass at an unusual place at the colonic splenic flexure that was initially concerning for malignancy.

Case Information

A 56 year-old female with history of irritable bowel syndrome, polymyositis and chronic intestinal pseudo-obstruction (on chronic total parenteral nutrition) presented with 2-week duration of left lower quadrant abdominal pain, nausea, vomiting, and diarrhea (dark green stools).

She also reported a history of chronic constipation and narcotics use for her chronic hip pain. Abdominal examination was notable for left lower quadrant tenderness and a left upper quadrant palpable mass.

Abdominal X-ray showed, in addition to a few air filled dilated bowel loops consistent with partial bowel obstruction, a large mass in the left hemi-abdomen suspicious for malignancy (Figure 1a, blue arrow). A contrast-enhanced computed tomography (CT) scan of the abdomen showed diffuse dilatation of the proximal and mid small bowel with decompression of more distal loops; it also showed a large 14 cm mixed air and soft tissue density mass in the colonic splenic flexure (Figure 1b, green arrow). Flexible sigmoidoscopy revealed circumferentially obstructive solid fecal mass at the splenic flexure (Figure 2) with unsuccessful attempts to break it down with snare and forceps.

Patient received multiple laxative and stool softener regimens without improvement; repeat flexible sigmoidoscopy did not reveal any significant change in the size of the fecal mass. A repeat abdominal CT scan showed worsening of the colonic obstruction proximal to the fecal mass with a new transition point.

After failed medical and endoscopic management, she underwent surgical removal of the fecal mass, sigmoidectomy with diverting loop ileostomy. She was eventually discharged to a rehabilitation institution.

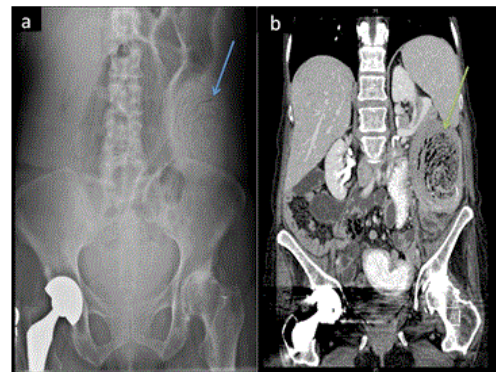


Figure 1: a) Abdominal X-ray: a large rounded area of mottled gas and soft tissue (blue arrow). b) Contrast-enhanced CT of the abdomen, coronal view: a large 14 cm mixed air and soft tissue density mass in the colon splenic flexure (green arrow).

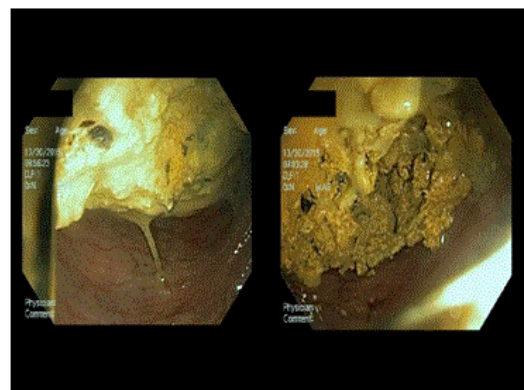


Figure 2: Flexible sigmoidoscopy shows a circumferentially obstructive solid fecal mass at the splenic flexure; unsuccessful attempts to break it down with snare and forceps.

Discussion

Fecaloma is an organized intraluminal fecal mass that is formed secondary to prolonged retention of fecal residue. Fecaloma is the most severe form of fecal impaction in predisposed individuals [2] and most commonly found in the recto-sigmoid area as stool becomes more consolidated due to decreased fluid content in the distal colon [3]. The

unusual site of the fecal mass at the colonic splenic flexure in this case was initially concerning for malignancy. Fecaloma may lead to specious diarrhea, bowel obstruction [4], stercoral colon ulceration and perforation [5], and urinary tract obstruction and hydronephrosis [6]. Surgical removal with limited or more extensive resection is required when conservative management fails to adequately remove fecalomas. The chronic pseudo-obstruction and low colonic transit in addition to chronic narcotic use in the patient in this case likely predisposed her to chronic fecal impaction and subsequently developing large fecaloma.

References

1. Markogiannakis H, Messaris E, Dardamanis D, Pararas N, Tzertzemelis D, et al. (2007) Acute mechanical bowel obstruction: clinical presentation, etiology, management and outcome. *World J Gastroenterol* 13: 432-437.
2. Aiyappan SK, Ranga U, Samraj A, Rajan SC, Veeraiyan S (2013) A case of fecaloma. *Indian J Surg* 75: 323-324.
3. Saksonov M, Bachar GN, Morgenstern S, Zeina AR, Vasserman M, et al. (2014) Stercoral colitis: a lethal disease-computed tomographic findings and clinical characteristic. *J Comput Assist Tomogr* 38: 721-726.
4. Yoo HY, Park HW, Chang SH, Bae SH (2015) Ileal Fecaloma Presenting with Small Bowel Obstruction. *Pediatric gastroenterology, hepatology & nutrition* 18: 193-196.
5. Kwag SJ, Choi SK, Park JH, Jung EJ, Jung CY, et al. (2013) A stercoral perforation of the rectum. *Annals of coloproctology* 29: 77-79.
6. Park JS, Park TJ, Hwa JS, Seo JH, Park CH, et al. (2013) Acute Urinary Retention in a 47-month-old Girl Caused by the Giant Fecaloma. *Pediatric gastroenterology, hepatology & nutrition* 16: 200-205.